

RECEIVED

Apr 25 2024

SC Court of Appeals

THE STATE OF SOUTH CAROLINA
In the Court of Appeals

APPEAL FROM NEWBERRY COUNTY
Court of Common Pleas

Charles M. Watson, Jr., Special Referee

Appellate Case No. 2023-000162

Related Appellate Case No. 2023-001143

Case No. 2022-CP-36-00326

Lena Sue Yarborough, Appellant,

v.

Joel F. Yarborough, III, Respondent.

MOTION FOR LEAVE TO FILE
RESPONDENT'S FINAL BRIEF OUT OF TIME

Pursuant to Rule 240 of the South Carolina Appellate Court Rules, the undersigned attorney for Respondent Joel F. Yarborough, III, respectfully requests leave to file Respondent's Final Brief out of the time allotted in Rule 211 of the South Carolina Appellate Court Rules.

Respondent's Initial Brief and Designation of Matter to be Included was due on April 19, 2024. For the majority of my life, I have been relatively healthy. However, in the past six months or longer, I have had repeated health issues that have significantly impacted my

activities and attention.

On December 2, 2023, I suffered a medical emergency caused by sudden blood clotting from my ankle to my hip in my left leg. After visiting urgent care on Monday morning and then an ultrasound procedure, I was hospitalized from December 4 through December 6, 2023, for emergency surgery to remove the blood clots in my left leg. The first surgery on December 5 was unsuccessful due to a collapsed vein in the leg and I was in severe pain, essentially bed-ridden for the better part of two months with limited mobility. After multiple surgical procedures at MUSC in Charleston and a nine hour procedure, the blood clotting was removed but the surgeons were unable to repair the collapsed iliac vein in my left leg. There is no circulation in the major iliac vein in my left leg to remove blood and the only way to keep the leg from heavy swelling is by elevation and drainage.

The symptoms are extreme swelling in the left leg, intense pain when walking and constant pain in the pelvic area (above the collapsed vein). I do note the massive swelling and intense pain are no longer as extreme. There is no procedure to fix the vein and I am on blood thinning medication.

In mid March, 2024, I had a procedure to remove four wisdom teeth/molars which required sedation. I was unable to take my blood thinning medicine for several days because of the risk of uncontrolled bleeding. Unfortunately, this seems to have triggered a re-occurrence of massive blood clotting in my left leg in early April of this year. I have attached a medical report. Because of the pain and lack of mobility, I was not able to file and serve Respondent's Initial Brief and Designation of Matters for the Record.

I am requesting leave to file and serve Respondent's Initial Brief and Designation out of time. I believe the brief is well founded and will assist the court in its review of this appeal and avoid an undue hardship on my client. The filing fee is being submitted to the Court of Appeals

tomorrow morning.

Respectfully submitted.

s/ Charles Verner
Charles Verner (SC Bar No. 10033)
lawyer@sc.rr.com
1303 Main Street, Suite 306
P. O. Box 484
Newberry, South Carolina 29108
(803) 915-9798 (Office)

Attorney for Respondent Joel F. Yarborough, III

Newberry, South Carolina
August 24, 2024

OTHER COUNSEL OF RECORD

Beth B. Richardson (SC Bar No. 69552)
brichardson@robinsongray.com
Sarah C. Frierson (SC Bar No. 104643)
sfrierson@robinsongray.com
ROBINSON GRAY STEPP & LAFFITTE, LLC
2151 Pickens Street, Suite 500 (29201)
Post Office Box 11449
Columbia, South Carolina 29211
(803) 929-1400 Telephone

Counsel for Appellant Lena Sue Yarborough

**Left Duplex
Venous Lower Extremity
Study Report**

CHARLES VERNER
April 01, 2024

MRN: [REDACTED]
DOB: [REDACTED] Age: 55
Gender: M
Height: 74 in Weight: 190 lbs
BSA: 2.12 m²
BMI: 24.39 kg/m²

Study Time: 01:52 PM
Reading Group: Daniel Bouknight, MD FACC
Referring Group: Midlands Orthopedics and Neurosurgery
Ordering Phys: Adam Griffith, MD
Sonographer: Shannon Watts, RVT, RDCS
Location: Advanced Diagnostics-Irmo
Equipment: Vivid S70

Study Quality: Good
Diagnosis Code: M79.89 Swelling
182.412 DVT Acute Femoral V. Left leg

Indications: Swelling. Extensive DVT previously
Risk Factors: May Thurner. Extensive DVT in December. Patient sent for thrombus removal with attempt to stent iliac vein. Patient was off Eliquis for a dental procedure but is back on it.
Procedure Code: 93971 Lower Extremity Venous Duplex (Unilateral)

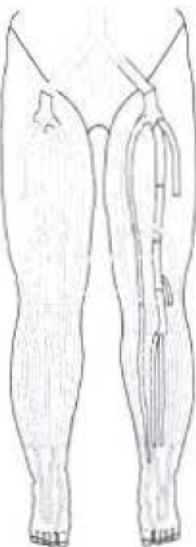
A Duplex Venous Lower Extremity ultrasound was performed.

RIGHT

	Compressibility	Thrombosis	Spontaneity	Phasicity	Augmentation
CFV	Normal	Normal	Normal	Normal	Normal

LEFT

	Compressibility	Thrombosis	Spontaneity	Phasicity	Augmentation
EIV	Absent	Acute	Absent	Absent	Inconclusive
CFV	Absent	Acute	Absent	Absent	Inconclusive
FV Prox	Absent	Acute			
FV Mid	Absent	Acute			
FV Dist	Absent	Acute			
PFV	Absent	Acute			
GSV AK	Normal	Normal			
GSV BK	Normal	Normal			
POP	Absent	Acute	Absent	Absent	Inconclusive
PTV	Absent	Acute			
PER	Absent	Acute			
GASTROC	Absent	Acute			



- Normal
- Mildly reduced
- Moderately reduced
- Severely reduced
- Absent
- Inconclusive

Right Findings:

There is no evidence of deep venous thrombosis of the (contralateral) common femoral vein.

Left Findings:

Noncompressible left lower extremity.
Acute deep vein thrombosis in the left lower extremity in the external iliac, common femoral, femoral, profunda, popliteal, peroneal, gastrocnemius, and proximal to mid posterior tibial veins.

Unable to visualize the left common iliac vein.

No spontaneous phasic flow in the left external iliac, common femoral and popliteal veins.

Conclusions:

There is no evidence of deep venous thrombosis of the (contralateral) common femoral vein.
Noncompressible left lower extremity.

Acute deep vein thrombosis in the left lower extremity in the external iliac, common femoral, femoral, profunda, popliteal, peroneal, gastrocnemius, and proximal to mid posterior tibial veins.

Unable to visualize the left common iliac vein.

No spontaneous phasic flow in the left external iliac, common femoral and popliteal veins.

April 02, 2024 06:54 AM EDT
Daniel P. Bouknight, MD FACC
Electronically Signed on Studycast

**Left Duplex
Venous Lower Extremity
Study Report**

CHARLES VERNER
April 01, 2024

Conclusions:

Call report to Monica at 2:22 PM on 4-1-24. Patient is taking his Eliquis and will follow up with the previous doctor that provided treatment for May Thurner.