

Rule 209

Designation of Matters to
be Included in the Record on
Appeal

RECEIVED

FEB 02 2018

SC Court of Appeals

Rule 209

~~Attest~~

1-

Designation of Matter to be included in the record appended
Starting with the STATEMENT
And Evidence of the Case.

On pag 2 about benefits been suspended
of Jun 29, 2015. Was wrong and miss diagnosis
by Doctor Van what was the plan by the
defence is to make it look as if it was
astrin and not what the M.R.I said it
was so; I wanted a second opinion
and thats when he used my work-
Comp Checks to stop it they even said
in e-mail that no one would see me not even
Doctor paylor but I ask My Surgeon Dr. Paylor
if that was true and he said no he would
love to treat me and do my surgery. So
there for he lied and my Lawyer saying
Dr paylor would not see me for my second
opinion. they stop my checks just to
force me to go back to Van. My
benefits should never had been stop. I
would like to have it back

2-

Also of page 2 I went to see Dr. Bommernanke at Urgent Doctor Care first he gave me pain meds and referred me to physical therapy and Belizing I was in to much pain he pulled me out and orderd me to have my first M.R.I done to my should we spok prefly about the sourness in my back and was hoping it was just from all that lifting we went on to Schueld my first M.R.I and we went over the M.R.I and in his notes he said I want you to go back to Doctor Paylor so this does not fall through the cracks. Doctor Van never orderd Me in M.R.I because I saw him for 5 min once and he order an X Ray I brout my M.R.I to him and he did not want to even look at it. So no he never orderd M.R.I

Dr. Van was appart of the throwing me under the bus with the Defence Doctor Plan and Doctor Paylor work at Leadmatt Orthoe to ~~get together~~ geather

On page three Lawyer John Holland and Usry was relect by Nathriel Alston for the basied of Doctor Keith was doing the same thing Doctor Van was trying to do Make it look like its not suggestall I was being Examine by Doctor Keith and I told him that my back is very painfull its been hinting for over three month he examine my shoulders my neck and back lower area lumbar but for some odd reason he wrote down my neck and I told him my neck is fine it my lower back he would not help me so I told him here is a list of my meds and the all need to be refilled he said he dosent do that so afte all of that I new he was not going to help me so I went bac to see him a few days later to have a talk with him he made it clear to him this is a sugical matter and could he do my sugary and I ask him why he did not want to fill my perscription well I recorded our last vist and would

4

I like to put my recording of our talk as evidence to prove how wrong he was to try and make me look like a junky for pills and said I was upset about that my recording says it all

Also I would like to have all M.R.I submitted in as evidence.

I also would like to be reimbursed for all my Medical and Medication

in to the Clame. Sorry about my hand writing it difficult to write perfect and also the miss spealed words. I have

had my Sugry to my left shoulder by Doctor Paylor in November and paid for it my self also would like to have it submitted in as evidence.

My wife as a witness. Yours Truly

All of my Medical Paper
Work

Nathaniel Alston



CVS Pharmacy

ALSTON, NATHANIEL
105 CAVALIER DR APT 11
GREENVILLE, SC, 29607

Private and Confidential
Intended for Addressee Only

01/30/18

Dear Patient:

Enclosed is your Patient Prescription record, as recently requested from CVS/Pharmacy.

If you have questions about this record, please go to www.CVS.com/privacy for further information or contact the Privacy Office at 1.800.287.2414.

PATIENT PRESCRIPTION RECORD

Date: 01/30/2018 Time: 1:21:20 PM

01/01/2017 THRU 01/30/2018

PHARMAC / NAME: 04172 # 04172
 ADDRESS: 315 W BUTLER ROAD
 CITY, ST, ZIP: MAULDIN, SC, 29662
 PATIENT KEY: 4993017899
 PATIENT NAME: ALSTON, NATHANIEL
 ADDRESS: 105 CAVALIER DR APT 11
 CITY, ST, ZIP: GREENVILLE, SC, 29607

TELEPHONE: (864) 593-3427
 BIRTHDATE: 11/24/1972
 GENDER: M
 RELATIONSHIP: Card Holder

STORE #	RX NUMBER	RFL	NDC NUMBER	DRUG DESCRIPTION	PRESCRIBER NAME	DATE FILLED	QUANT DISP	PATIENT PD AMT
4172	1488015	002	13668001005	CITALOPRAM HBR 20 MG TABLET	CRAWFORD, TRACY	02/23/2017	30.00	0.00
4172	1473476	005	00378075110	CYCLOBENZAPRINE 10 MG TABLET	LOUDERMILK, ERIC	01/14/2017	90.00	0.00
4172	1473476	006	00378075110	CYCLOBENZAPRINE 10 MG TABLET	LOUDERMILK, ERIC	02/14/2017	90.00	0.00
4172	1533414	000	00378075110	CYCLOBENZAPRINE 10 MG TABLET	SIMPSON, RACHEL	04/24/2017	90.00	0.00
4172	1533414	001	00378075110	CYCLOBENZAPRINE 10 MG TABLET	SIMPSON, RACHEL	05/29/2017	90.00	0.00
4172	1533414	002	00378075110	CYCLOBENZAPRINE 10 MG TABLET	SIMPSON, RACHEL	06/27/2017	90.00	0.00
4172	1533414	003	00378075110	CYCLOBENZAPRINE 10 MG TABLET	SIMPSON, RACHEL	07/26/2017	90.00	0.00
4172	1533414	004	00378075110	CYCLOBENZAPRINE 10 MG TABLET	SIMPSON, RACHEL	08/22/2017	90.00	0.00
4172	1533414	005	00378075110	CYCLOBENZAPRINE 10 MG TABLET	SIMPSON, RACHEL	09/18/2017	90.00	0.00
4172	1533414	006	00378075110	CYCLOBENZAPRINE 10 MG TABLET	SIMPSON, RACHEL	10/14/2017	90.00	0.00
4172	1562775	000	00378075110	CYCLOBENZAPRINE 10 MG TABLET	CRAWFORD, TRACY	11/09/2017	90.00	0.00
4172	1562775	001	00378075110	CYCLOBENZAPRINE 10 MG TABLET	CRAWFORD, TRACY	12/05/2017	90.00	0.00
4172	1562775	002	00378075110	CYCLOBENZAPRINE 10 MG TABLET	CRAWFORD, TRACY	01/04/2018	90.00	0.00
4172	1562775	003	00378075110	CYCLOBENZAPRINE 10 MG TABLET	CRAWFORD, TRACY	01/30/2018	90.00	2.98
4172	1480829	003	16571020106	DICLOFENAC SOD EC 75 MG TAB	LOUDERMILK, ERIC	01/27/2017	60.00	0.00
4172	1480829	004	16571020106	DICLOFENAC SOD EC 75 MG TAB	LOUDERMILK, ERIC	02/24/2017	60.00	0.00
4172	1480829	005	16571020106	DICLOFENAC SOD EC 75 MG TAB	LOUDERMILK, ERIC	03/25/2017	60.00	0.00
4172	1480829	006	16571020106	DICLOFENAC SOD EC 75 MG TAB	LOUDERMILK, ERIC	04/23/2017	60.00	0.00
4172	1533413	000	16571020106	DICLOFENAC SOD EC 75 MG TAB	SIMPSON, RACHEL	05/29/2017	60.00	0.00
4172	1533413	001	16571020106	DICLOFENAC SOD EC 75 MG TAB	SIMPSON, RACHEL	06/27/2017	60.00	0.00
4172	1533413	002	16571020106	DICLOFENAC SOD EC 75 MG TAB	SIMPSON, RACHEL	07/26/2017	60.00	0.00
4172	1533413	003	16571020106	DICLOFENAC SOD EC 75 MG TAB	SIMPSON, RACHEL	08/22/2017	60.00	0.00
4172	1533413	004	16571020106	DICLOFENAC SOD EC 75 MG TAB	SIMPSON, RACHEL	09/18/2017	60.00	0.00
4172	1533413	005	16571020106	DICLOFENAC SOD EC 75 MG TAB	SIMPSON, RACHEL	10/14/2017	60.00	0.00
4172	1533413	006	16571020106	DICLOFENAC SOD EC 75 MG TAB	SIMPSON, RACHEL	11/09/2017	60.00	0.00
4172	1562774	000	16571020106	DICLOFENAC SOD EC 75 MG TAB	LOUDERMILK, ERIC	12/05/2017	60.00	0.00
4172	1562774	001	16571020106	DICLOFENAC SOD EC 75 MG TAB	LOUDERMILK, ERIC	01/12/2018	60.00	5.00
4172	1562783	000	49884093547	DICLOFENAC SODIUM 1% GEL	CRAWFORD, TRACY	08/29/2017	200.00	0.00
4172	1562783	001	49884093547	DICLOFENAC SODIUM 1% GEL	CRAWFORD, TRACY	12/06/2017	200.00	0.00
4172	1548786	000	66993066330	DULOXETINE HCL DR 30 MG CAP	CRAWFORD, TRACY	06/30/2017	30.00	0.00
4172	1555048	000	66993066430	DULOXETINE HCL DR 60 MG CAP	CRAWFORD, TRACY	07/28/2017	30.00	0.00
4172	1555048	001	66993066430	DULOXETINE HCL DR 60 MG CAP	CRAWFORD, TRACY	08/23/2017	30.00	0.00
4172	1555048	002	66993066430	DULOXETINE HCL DR 60 MG CAP	CRAWFORD, TRACY	09/18/2017	30.00	0.00
4172	1555048	003	66993066430	DULOXETINE HCL DR 60 MG CAP	CRAWFORD, TRACY	10/14/2017	30.00	0.00
4172	1555048	004	66993066430	DULOXETINE HCL DR 60 MG CAP	CRAWFORD, TRACY	11/09/2017	30.00	0.00
4172	1555048	005	66993066430	DULOXETINE HCL DR 60 MG CAP	CRAWFORD, TRACY	12/05/2017	30.00	0.00
4172	1555048	006	66993066430	DULOXETINE HCL DR 60 MG CAP	CRAWFORD, TRACY	01/01/2018	30.00	5.00
4172	1562776	000	58160090752	FLUARIX QUAD 2017-2018 SYRINGE	BETEJEVA, MARIJA	08/29/2017	0.50	0.00
4172	1495582	000	69097081412	GABAPENTIN 300 MG CAPSULE	CRAWFORD, TRACY	01/02/2017	180.00	0.00
4172	1495582	001	69097081412	GABAPENTIN 300 MG CAPSULE	CRAWFORD, TRACY	01/29/2017	180.00	0.00
4172	1495582	002	69097081412	GABAPENTIN 300 MG CAPSULE	CRAWFORD, TRACY	02/25/2017	180.00	0.00
4172	1495582	003	69097081412	GABAPENTIN 300 MG CAPSULE	CRAWFORD, TRACY	03/25/2017	180.00	0.00
4172	1495582	004	69097081412	GABAPENTIN 300 MG CAPSULE	CRAWFORD, TRACY	04/22/2017	180.00	0.00
4172	1495582	005	69097081412	GABAPENTIN 300 MG CAPSULE	CRAWFORD, TRACY	05/20/2017	180.00	0.00
4172	1495582	006	69097081412	GABAPENTIN 300 MG CAPSULE	CRAWFORD, TRACY	06/16/2017	180.00	0.00
4172	1562780	000	65862052305	GABAPENTIN 600 MG TABLET	CRAWFORD, TRACY	08/29/2017	120.00	0.00
4172	1562780	001	65862052305	GABAPENTIN 600 MG TABLET	CRAWFORD, TRACY	09/24/2017	120.00	0.00
4172	1562780	002	65862052305	GABAPENTIN 600 MG TABLET	CRAWFORD, TRACY	10/24/2017	120.00	0.00
4172	1562780	003	65862052305	GABAPENTIN 600 MG TABLET	CRAWFORD, TRACY	11/29/2017	120.00	0.00
4172	1562780	004	65862052305	GABAPENTIN 600 MG TABLET	CRAWFORD, TRACY	12/28/2017	120.00	0.00
4172	1562780	005	65862052305	GABAPENTIN 600 MG TABLET	CRAWFORD, TRACY	01/23/2018	120.00	5.00
4172	1503276	000	00603388721	HYDROCODON-ACETAMINOPHN 10-325	LOUDERMILK, ERIC	01/02/2017	120.00	0.00
4172	1503304	000	00603388721	HYDROCODON-ACETAMINOPHN 10-325	LOUDERMILK, ERIC	02/01/2017	120.00	0.00
4172	1518458	000	00603388721	HYDROCODON-ACETAMINOPHN 10-325	LOUDERMILK, ERIC	03/02/2017	120.00	0.00
4172	1518458	000	00603388721	HYDROCODON-ACETAMINOPHN 10-325	LOUDERMILK, ERIC	04/01/2017	120.00	0.00
4172	1533423	000	00603388721	HYDROCODON-ACETAMINOPHN 10-325	LOUDERMILK, ERIC	04/30/2017	120.00	0.00
4172	1542512	000	00603388721	HYDROCODON-ACETAMINOPHN 10-325	LOUDERMILK, ERIC	06/02/2017	120.00	0.00
4172	1548789	000	00603388721	HYDROCODON-ACETAMINOPHN 10-325	LOUDERMILK, ERIC	07/01/2017	120.00	0.00
4172	1555245	000	00603388721	HYDROCODON-ACETAMINOPHN 10-325	LOUDERMILK, ERIC	07/30/2017	120.00	0.00
4172	1562769	000	00603388721	HYDROCODON-ACETAMINOPHN 10-325	LOUDERMILK, ERIC	08/29/2017	120.00	0.00
4172	1562818	000	00603388721	HYDROCODON-ACETAMINOPHN 10-325	LOUDERMILK, ERIC	09/28/2017	120.00	0.00
4172	1576868	000	00603388721	HYDROCODON-ACETAMINOPHN 10-325	LOUDERMILK, ERIC	10/27/2017	120.00	0.00
4172	1576995	000	00603388721	HYDROCODONE-ACETAMIN 10-325 MG	LOUDERMILK, ERIC	11/24/2017	120.00	0.00
4172	1582238	000	49483060350	IBUPROFEN 600 MG TABLET	PAYLOR, JOHN	11/10/2017	50.00	0.00

For customers who require additional information please contact the CVS privacy office at 800-287-2414.
 Private and Confidential Intended for Addressee only

PATIENT PRESCRIPTION RECORD

Date: 01/30/2018 Time: 1:21:20 PM

01/01/2017 THRU 01/30/2018

HARMACY NAME: 04172 # 04172
 ADDRESS: 315 W BUTLER ROAD
 CITY, ST, ZIP: MAULDIN, SC, 29662

PATIENT KEY: 4993017899
 PATIENT NAME: ALSTON, NATHANIEL
 ADDRESS: 105 CAVALIER DR APT 11
 CITY, ST, ZIP: GREENVILLE, SC, 29607

TELEPHONE: (864) 593-3427
 BIRTHDATE: 11/24/1972
 GENDER: M
 RELATIONSHIP: Card Holder

STORE #	RX NUMBER	RFL	NDC NUMBER	DRUG DESCRIPTION	PRESCRIBER NAME	DATE FILLED	QUANT DISP	PATIENT PD AMT
4172	1584070	000	49483060350	IBUPROFEN 600 MG TABLET	PAYLOR, JOHN	12/01/2017	90.00	0.00
4172	1562781	000	00603459315	METHYLPREDNISOLONE 4 MG DOSEPK	CRAWFORD, TRACY	08/29/2017	21.00	0.00
4172	1591885	000	00603499121	OXYCODONE HCL 15 MG TABLET	LOUDERMILK, ERIC	12/18/2017	120.00	0.00
4172	1598440	000	00603499121	OXYCODONE HCL 15 MG TABLET	LOUDERMILK, ERIC	01/16/2018	120.00	5.00
4172	1582237	000	42858010201	OXYCODONE-ACETAMINOPHEN 5-325	PAYLOR, JOHN	11/10/2017	25.00	0.00
4172	1542519	000	50111043401	TRAZODONE 100 MG TABLET	LOUDERMILK, ERIC	06/02/2017	30.00	0.00
4172	1542519	001	50111043401	TRAZODONE 100 MG TABLET	LOUDERMILK, ERIC	07/07/2017	30.00	0.00
4172	1542519	002	50111043401	TRAZODONE 100 MG TABLET	LOUDERMILK, ERIC	01/30/2018	30.00	3.05
4172	1533415	000	50111043301	TRAZODONE 50 MG TABLET	SIMPSON, RACHEL	04/24/2017	30.00	0.00
4172	1533415	001	50111043301	TRAZODONE 50 MG TABLET	SIMPSON, RACHEL	05/24/2017	30.00	0.00
4172	1555047	000	50111043301	TRAZODONE 50 MG TABLET	CRAWFORD, TRACY	07/28/2017	60.00	0.00
4172	1555047	001	50111043301	TRAZODONE 50 MG TABLET	CRAWFORD, TRACY	08/23/2017	60.00	0.00
4172	1555047	002	50111043301	TRAZODONE 50 MG TABLET	CRAWFORD, TRACY	09/18/2017	60.00	0.00
4172	1555047	003	50111043301	TRAZODONE 50 MG TABLET	CRAWFORD, TRACY	10/14/2017	60.00	0.00
4172	1555047	004	50111043301	TRAZODONE 50 MG TABLET	CRAWFORD, TRACY	11/09/2017	60.00	0.00
4172	1555047	005	50111043301	TRAZODONE 50 MG TABLET	CRAWFORD, TRACY	12/05/2017	60.00	0.00
4172	1555047	006	50111043301	TRAZODONE 50 MG TABLET	CRAWFORD, TRACY	01/01/2018	60.00	3.49

TOTAL # OF PRESCRIPTIONS: 81 TOTAL PATIENT PAID AMOUNT : 29.52

For customers who require additional information please contact the CVS privacy office at 800-287-2414.

Private and Confidential Intended for Addressee only



BON SECOURS HEALTH SYSTEM, INC.

MRI (BACK)

ST FRANCIS DOWNTOWN
ONE ST FRANCIS DRIVE
GREENVILLE SC 29601-3955

ALSTON, NATHANIEL
MRN: 781017975
DOB: 11/24/1972, Sex: M
Acct #: 30170100426
Arrived 1/17/2017, D/C:

Resulted: 01/18/17 0902, Result status: Final result

MRI LUMB SPINE WO CONT [356848614]

Resulted by: Krista D Timmerman, MD Performed: 01/17/17 1955 - 01/17/17 2036
Resulting lab: GRNVL SFD RADIANT
Narrative:
Examination: MRI lumbar spine without gadolinium

History: 44-year-old male with severe low back pain since 2014. Patient sustained a back injury while lifting in 2010. Also fell one week ago. No prior lumbar spine surgery.

Comparison: None.

Findings: Alignment is within normal limits. There is no vertebral body compression fracture. There is no marrow edema or focal osseous lesion. Intervertebral discs maintain normal signal intensity.

The conus terminates at T12-L1. The distal spinal cord and conus have normal signal intensity. Included retroperitoneal structures are unremarkable.

L1-L2: No central canal or foraminal stenosis.

L2-L3: No central canal or foraminal stenosis.

L3-L4: No central canal or foraminal stenosis.

L4-L5: Mild facet arthropathy with small facet joint effusions. No central canal or foraminal stenosis.

L5-S1: There is mild facet arthropathy. No central canal or foraminal stenosis.

Impression:

Impression: Mild facet arthropathy in the lower lumbar spine. No central canal or foraminal stenosis. No marrow signal abnormality.

Specimen Information

Type	Source	Collected On
		01/18/17 0851

Testing Performed By

Lab - Abbreviation	Name	Director	Address	Valid Date Range
10 - Unknown	GRNVL SFD RADIANT	SFD Lab Director	Unknown	01/15/13 1538 - Present



SOUTH CAROLINA DIAGNOSTIC IMAGING

Innervation Medical Imaging Eastside
One Marcus Drive Greenville, SC 29615
p: (864) 242-2020 F: (864) 240-5776

PATIENT: ALSTON, NATHANIEL
DOB: 11/24/1972
MRN: 691076
PHONE: 864-593-3427 (Mobile)
PHYSICIAN: JOHN PAYLOR, MD
EXAM DATE: 10/27/2017

EXAM: MR Left Shoulder Without Contrast

REASON FOR EXAM: Primary osteoarthritis, left shoulder, Impingement syndrome of left shoulder

ADDITIONAL HISTORY: Left shoulder pain. Injury lifting furniture.

TECHNIQUE: Multisequence, multiplanar imaging was obtained through the left shoulder unenhanced.

FINDINGS: Type II acromion configuration. Mild thickening and distention of the joint capsule. Small erosion or cyst of the articulating aspect of the clavicular head. Small inferior AC joint osteophytes. Small amount of AC joint fluid. Mild acute AC joint arthritis. Mild T2 hyperintensity within the subacromial-subdeltoid bursa. No full-thickness rotator cuff tear. Mild distal supraspinatus and infraspinatus tendinosis. Intact and normally located long head biceps tendon. No definite labral tear. Mild localized signal brightening within the interstitium footprint of the supraspinatus tendon may indicate a slightly more localized tendinopathy or perhaps a minor partial-thickness tear.

Tiny osteophyte of the inferior aspect of the humeral head. Normally-configured glenoid.

CONCLUSION: Acute-on-chronic AC joint arthritis. Mild supraspinatus and infraspinatus tendinopathy but without full-thickness rotator cuff tear. No long head biceps tendon avulsion. No identified labral tear.

Jeffrey K Shramek, MD

JS/llh

DD: 10/27/2017 01:50 P

DT: 10/27/2017 04:13 P

Accession#: 08-2712097 VS#: 121456208 CS#: 2483392

cc:

Electronically Signed and Reviewed by Jeffrey K Shramek, MD 10/29/2017 12:10 P

Alston, Nathaniel

MRN: 781017975
Description: 44 year old male

Op Notes Date of Service: 11/10/17 0942

John H Paylor III, MD
Orthopedic Surgery

PATIENT: Nathaniel Alston

DATE OF SURGERY: 11/10/2017

PREOPERATIVE DIAGNOSIS: Arthrosis of left acromioclavicular joint [M19.012]
Impingement syndrome of left shoulder [M75.42]

POSTOPERATIVE DIAGNOSIS: Left Shoulder Impingement/ AC Joint Arthritis

PROCEDURE: Procedure(s):
LEFT SHOULDER ARTHROSCOPY DISTAL CLAVICLE RESECTION SUBACROMIAL
DECOMPRESSION

PROCEDURE IN DETAIL: The patient's left shoulder was prepped and draped in a sterile fashion. The arthroscope was inserted through a posterior portal and the interior of the joint was examined. The labrum was intact. The biceps tendon was normal as well. The articular surfaces were normal. There was not a tear of the rotator cuff.

The scope was then removed from the shoulder joint and then placed into the subacromial space. The bursal tissue was removed and visualization was obtained. The anterior acromion was prominent. A subacromial decompression was performed through the posterior portal using a cutting block technique. This provided a good decompression of the subacromial space. The rotator cuff was examined and was normal.

The distal clavicle was very degenerative. A distal clavicle resection was done through the anterior portal. The arthroscopic burr was used to remove approximately 1 centimeter of the bone. The stab wounds were then closed with simple nylon sutures. A sterile dressing was applied. A sling was placed as well. The patient was then taken to the recovery room in satisfactory condition.

John H. Paylor III, M.D.
Electronically signed by John H Paylor III, MD at 11/10/17 0944

Admission (Current) on 11/10/2017
Note shared with patient

Note Details

Author	John H Paylor III, MD	File Time	11/10/17 0944
Author Type	Physician	Status	Signed

PIEDMONT ORTHOPAEDICS
COPY

7

Name: Alston, Nathaniel
DOB: 1972-11-24
Age: 44 years
Gender: Male
Chart#: 86152327



piedmont
orthopaedic
associates



BON SECOURS MEDICAL GROUP
Bon Secours St. Francis Health System

Muscular strength is normal in arms and shoulders bilaterally.

Medical Decision Making:

The MRI scan that he had on his left shoulder is over 2 years old. He has had treatment including therapy and injections in the past for his left shoulder. He did have successful surgery on his right shoulder in the past for a similar complaint. We could certainly do arthroscopic surgery on his left shoulder. He does need to have an updated MRI scan before scheduling him for surgery. The locking happened in the past several years since his last MRI scan. I would like to order an MRI scan before scheduling the surgery on his left shoulder. The surgery would most likely include a subacromial decompression and a distal clavicle resection. He would also need to have physical therapy following the surgery.


John H. Paylor

Electronically signed by John H Paylor MD

POA COPY
2011

6

Name: Alston, Nathaniel
DOB: 1972-11-24
Age: 44 years
Gender: Male
Chart#: 86152327



piedmont
orthopaedic
associates



BON SECOURS MEDICAL GROUP
Bon Secours St. Francis Health System

Insurance: BCBS of South Carolina;

Office Visit: 99203 New Level 3		Diagnosis: M19.012 Arthrosis of left acromioclavicular joint M75.42 Impingement syndrome of left shoulder			
Proc 1:		Laterality:		Med 1:	
Proc 2:		Laterality:		Med 2:	
FX 1:		Laterality:	FX2:		Laterality:
Casting:		Cast Supply:			
DME:		Laterality:	DME:		Laterality:
XRAY	RIGHT:	LEFT:		BILAT:	

Follow up: After MRI

BMI:

Date of Service: 2017-10-25

Work
Status:

Onset Date: 10/1/2015

Allergies:

Medications:

CC: Left shoulder pain.

HPI:

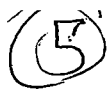The pain in the left shoulder has been present since the date of onset. There was an acute injury. It was hurt lifting over 3 years ago. The pain is located over the superior and lateral aspect of the left shoulder. It does hurt to raise the arm overhead. Night pain is present in the shoulder(s). Reaching behind is painful. The patient has tried anti-inflammatory medication. He is presently in pain management. He did have successful arthroscopic surgery of his right shoulder in the past. He did have an old MRI scan of his left shoulder which showed acromioclavicular arthrosis as well as findings of impingement. He is very interested in having arthroscopic surgery for his left shoulder.

POA stamp
NOV 2 2017

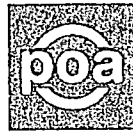
ROS AND PMFSH: This is located on the chart on the patient history form and has been signed and dated. Pertinent positives and negative are addressed with the patient. Non-orthopedic concerns are referred to the primary care provider.

Physical Examination:

General appearance of the patient is normal for age
Sensation in UEs is intact and denies numbness or tingling.
DTRs are normal and symmetrical.
Circulation is intact.
The skin is noted to be normal over bilateral upper extremities.
Gait is noted to be normal.
Palpation reveals tenderness over the **Error! Reference source not found.** aspect of the left shoulder
Range of motion shows pain with abduction to 90 degrees. Flexion with IR is painful. IR and ER produce pain in ABD..
Shoulder stability is normal bilaterally.



Name: Alston, Nathaniel
 DOB: 1972-11-24
 Age: 44 years
 Gender: Male
 Chart#: 86152327



piedmont
orthopaedic
associates



BON SECOURS MEDICAL GROUP
Bon Secours St. Francis Health System

Insurance: BCBS of South Carolina;

Office Visit: 99212 EST Level 2		Diagnosis: M19.012 Arthrosis of left acromioclavicular joint M75.42 Impingement syndrome of left shoulder	
Proc 1:		Laterality:	Med 1:
Proc 2:		Laterality:	Med 2:
FX 1:	Laterality:	FX2:	Laterality:
Casting:		Cast Supply:	
DME:		Laterality:	DME:
XRAY RIGHT:		LEFT:	BILAT:

Follow up: Surgery

BMI:43.7

Date of Service: 2017-11-06

Work
Status:

Allergies:

Medications: Cyclobenzaprine HCl (10 MG); Diclofenac Sodium (1 %); DULoxetine HCl (60 MG); Gabapentin (600 MG); Hydrocodone-Acetaminophen (10-325 MG); TraZODone HCl (50 MG)

CC: Left Shoulder

He did have the MRI scan of his left shoulder. There is not an interval change. He continues to have the acute on chronic acromioclavicular arthritis. He has have evidence of impingement as well. He would very much like to go ahead and have the surgery that had on his other shoulder. The surgery would be a subacromial decompression and a distal clavicle resection. The surgery is discussed. The risk of the procedure is discussed. The complications are discussed. The patient will be scheduled have this surgery. Hopefully he will do well and we will be able to help him with his pain. He does understand that it is not immediate and he will have Therapy. Takes a long time to have hopefully a good result.


John H. Paylor

Electronically Signed By John H Paylor MD

POA COPY
JUL 20 2017



Name: Alston, Nathaniel
 DOB: 1972-11-24
 Age: 44 years
 Gender: Male
 Chart#: 86152327



piedmont
orthopaedic
associates



BON SECOURS MEDICAL GROUP
Bon Secours St. Francis Health System

Insurance: BCBS of South Carolina;

Office Visit: 99024 Post-Op		Diagnosis: M19.012 Arthrosis of left acromioclavicular joint M75.42 Impingement syndrome of left shoulder	
Proc 1:		Laterality:	Med 1:
Proc 2:		Laterality:	Med 2:
Casting:		Cast Supply:	
DME:		Laterality:	DME: Laterality:
XRAY	RIGHT:	LEFT:	BILAT:

Follow up: 6 Weeks

BMI:43.7

Date of Service: 2017-11-15

Work
Status:

Allergies:

Medications: Cyclobenzaprine HCl (10 MG); Diclofenac Sodium (1 %); DULoxetine HCl (60 MG); Gabapentin (600 MG); Hydrocodone-Acetaminophen (10-325 MG); TraZODone HCl (50 MG)

The patient is status post their left shoulder surgery. He had a subacromial decompression and a distal clavicle resection.

The wounds are doing well with no sign of infection.

There is no abnormal swelling noted.

The patient will continue their medication as needed.

Exercises can begin. Physical therapy is ordered.

John H. Paylor

Electronically signed by John H Paylor MD

POA COPY
JUL 20 2011

3

Name: Alston, Nathaniel
DOB: 1972-11-24
Age: 45 years
Gender: Male
Chart#: 86152327



piedmont
orthopaedic
associates



BON SECOURS MEDICAL GROUP
Bon Secours St. Francis Health System

Insurance: BCBS of South Carolina;

Office Visit: 99024 Post-Op		Diagnosis: M19.012 Arthrosis of left acromioclavicular joint M75.42 Impingement syndrome of left shoulder			
Proc 1:		Laterality:		Med 1:	
Proc 2:		Laterality:		Med 2:	
FX 1:		Laterality:	FX2:		Laterality:
Casting:		Cast Supply:			
DME:		Laterality:		DME:	
DME:		Laterality:		DME:	
XRAY RIGHT:		LEFT:		BILAT:	

Follow up: 6 Weeks

BMI:43.7

Date of Service: 2017-12-27

Work
Status:

Allergies:

Medications: Cyclobenzaprine HCl (10 MG); Diclofenac Sodium (1 %); DULoxetine HCl (60 MG); Gabapentin (600 MG); Hydrocodone-Acetaminophen (10-325 MG); Ibuprofen (600 MG, Take 1 tablet(s) by mouth 3 times a day as needed [PRN]); TraZODone HCl (50 MG)

CC: Left Shoulder

He is having pain in the left shoulder. He also had a lot of postoperative pain in his right shoulder but finally did good with that. He needs to discontinue the sling which she is still in. He does need to get started on his therapy. There are no restrictions on his shoulder in physical therapy.

Copy to Dr. Loudermilk

POA COPY
DEC 27 2017

John H. Paylor

Electronically Signed By John H Paylor MD



2nd M.K.I

Innervision Medical Imaging Eastside
One Marcus Drive Greenville, SC 29615
p: (864) 242-2020 f: (864) 240-5776

SOUTH CAROLINA DIAGNOSTIC IMAGING

PATIENT: ALSTON, NATHANIEL
DOB: 11/24/1972
MRN: 691076
PHONE: 864-593-3427 (Mobile)
PHYSICIAN: JOHN PAYLOR, MD
EXAM DATE: 10/27/2017

EXAM: MR Left Shoulder Without Contrast

REASON FOR EXAM: Primary osteoarthritis, left shoulder, Impingement syndrome of left shoulder

ADDITIONAL HISTORY: Left shoulder pain. Injury lifting furniture.

TECHNIQUE: Multisequence, multiplanar imaging was obtained through the left shoulder unenhanced.

FINDINGS: Type II acromion configuration. Mild thickening and distention of the joint capsule. Small erosion or cyst of the articulating aspect of the clavicular head. Small inferior AC joint osteophytes. Small amount of AC joint fluid. Mild acute AC joint arthritis. Mild T2 hyperintensity within the subacromial-subdeltoid bursa. No full-thickness rotator cuff tear. Mild distal supraspinatus and infraspinatus tendinosis. Intact and normally located long head biceps tendon. No definite labral tear. Mild localized signal brightening within the interstitium footprint of the supraspinatus tendon may indicate a slightly more localized tendinopathy or perhaps a minor partial-thickness tear.

Tiny osteophyte of the inferior aspect of the humeral head. Normally-configured glenoid.

CONCLUSION: Acute-on-chronic AC joint arthritis. Mild supraspinatus and infraspinatus tendinopathy but without full-thickness rotator cuff tear. No long head biceps tendon avulsion. No identified labral tear.

Jeffrey K Shramek, MD

JS/llh

DD: 10/27/2017 01:50 P

DT: 10/27/2017 04:13 P

Accession#: 08-2712097 VS#: 121456208 CS#: 2483392

cc:

Electronically Signed and Reviewed by Jeffrey K Shramek, MD 10/29/2017 12:10 P

Alston, Nathaniel

MRN: 781017975
Description: 44 year old male

Op Notes Date of Service: 11/10/17 0942

John H Paylor III, MD
Orthopedic Surgery

PATIENT: Nathaniel Alston

DATE OF SURGERY: 11/10/2017

PREOPERATIVE DIAGNOSIS: Arthrosis of left acromioclavicular joint [M19.012]
Impingement syndrome of left shoulder [M75.42]

POSTOPERATIVE DIAGNOSIS: Left Shoulder Impingement/ AC Joint Arthritis

PROCEDURE: Procedure(s):
LEFT SHOULDER ARTHROSCOPY DISTAL CLAVICLE RESECTION SUBACROMIAL
DECOMPRESSION

PROCEDURE IN DETAIL: The patient's left shoulder was prepped and draped in a sterile fashion. The arthroscope was inserted through a posterior portal and the interior of the joint was examined. The labrum was intact. The biceps tendon was normal as well. The articular surfaces were normal. There was not a tear of the rotator cuff.

The scope was then removed from the shoulder joint and then placed into the subacromial space. The bursal tissue was removed and visualization was obtained. The anterior acromion was prominent. A subacromial decompression was performed through the posterior portal using a cutting block technique. This provided a good decompression of the subacromial space. The rotator cuff was examined and was normal.

The distal clavicle was very degenerative. A distal clavicle resection was done through the anterior portal. The arthroscopic burr was used to remove approximately 1 centimeter of the bone. The stab wounds were then closed with simple nylon sutures. A sterile dressing was applied. A sling was placed as well. The patient was then taken to the recovery room in satisfactory condition.

John H. Paylor III, M.D.
Electronically signed by John H Paylor III, MD at 11/10/17 0944

PO1 COPY
11/10/17

Admission (Current) on 11/10/2017
Note shared with patient

Note Details

Author	John H Paylor III, MD	File Time	11/10/17 0944
Author Type	Physician	Status	Signed



BON SECOURS HEALTH SYSTEM, INC.

**BON SECOURS HEALTH
SYSTEM**

**1 Saint Francis Dr
Greenville SC 29601
864-255-1248**

Patient: Nathaniel Alston
MRN: XXXXX7975
DOB: 11/24/1972

About your hospitalization

You were admitted on: November 10, 2017
You were discharged on: November 10, 2017

You last received care in the: SFD OP PACU

Why you were hospitalized

Your primary diagnosis was: Not on File

Things You Need To Do (next 8 weeks)

Follow up with None


Where: None (395) Patient stated that they have no PCP
Follow up with John H Paylor III, MD
Dr. Paylor's office will call you with follow-up date and time.

Phone: 864-234-7654

Where: 35 International Drive, Greenville SC 29615

Discharge Orders

None

A check mark  indicates which time of day the medication should be taken.

My Medications

STOP taking these medications

HYDROcodone-acetaminophen 10-325 mg tablet
Commonly known as: NORCO

TAKE these medications as instructed

My Medications (continued)

TAKE these medications as instructed (continued)

	Instructions	Each Dose to Equal	Morning	Noon	Evening	Bedtime
<p>amLODIPine 5 mg tablet Commonly known as: NORVASC</p> <p>Your last dose was:</p> <p>Your next dose is:</p>	<p>Take 5 mg by mouth nightly. Indications: hypertension</p>	5 mg				
<p>cyclobenzaprine 10 mg tablet Commonly known as: FLEXERIL</p> <p>Your last dose was:</p> <p>Your next dose is:</p>	<p>Take 10 mg by mouth three (3) times daily.</p>	10 mg				
<p>diclofenac 1 % Gel Commonly known as: VOLTAREN</p> <p>Your last dose was:</p> <p>Your next dose is:</p>	<p>Apply to affected area every six (6) hours.</p>					
<p>DULoxetine 60 mg capsule Commonly known as: CYMBALTA</p> <p>Your last dose was:</p> <p>Your next dose is:</p>	<p>Take 60 mg by mouth nightly.</p>	60 mg				
<p>gabapentin 600 mg tablet Commonly known as: NEURONTIN</p> <p>Your last dose was:</p> <p>Your next dose is:</p>	<p>Take 600 mg by mouth three (3) times daily.</p>	600 mg				
<p>ibuprofen 600 mg tablet Commonly known as: MOTRIN</p> <p>Your last dose was:</p> <p>Your next dose is:</p>	<p>Take 1 Tab by mouth every six (6) hours as needed for Pain. Indications: Pain</p>	600 mg				

My Medications (continued)

TAKE these medications as instructed (continued)

	Instructions	Each Dose to Equal	Morning	Noon	Evening	Bedtime
oxyCODONE-acetaminophen 5-325 mg per tablet Commonly known as: PERCOET	Take 1 Tab by mouth every four (4) hours as needed for Pain. Max Daily Amount: 6 Tabs.	1 Tab				
Your last dose was:						
Your next dose is:						

Where to Get Your Medications

Information on where to get these meds will be given to you by the nurse or doctor.

Ask your nurse or doctor about these medications:

- ibuprofen 600 mg tablet
- oxyCODONE-acetaminophen 5-325 mg per tablet

Discharge Instructions

**Post-Operative Instructions
For Nathaniel Alston
Shoulder Arthroscopy
Phone: (864) 234-7654**

1. Apply ice to the shoulder as needed.
2. Keep dressings in place for the first two days. After two days you may remove the dressings. Keep the stab wounds clean. The small stitches will be removed when you come to the office. You can cover them with small band aids.
3. You may discontinue use of your sling and begin active range of motion of the shoulder as tolerated by pain, unless you are instructed otherwise.
4. You may shower after the dressing comes off. Cover the small wounds with waterproof band aids.
5. Use pain medication as instructed on the bottle. If you have pain medication from another physician do not use it with this medication. Also take ibuprofen with the pain medication that you received today. This will help it work much better.
6. You may have some side effects from your pain medication. If you have nausea, try taking your medication with food. For itching, you may take over the counter Benadryl.

7. If you have a problem, please call Piedmont Orthopaedics at (864) 234-7654

John H. Paylor M.D.

Piedmont Orthopaedic Associates, P.A.

ACTIVITY

- As tolerated and as directed by your doctor.
- Bathe or shower as directed by your doctor.

DIET

- Clear liquids until no nausea or vomiting; then light diet for the first day.
- Advance to regular diet on second day, unless your doctor orders otherwise.
- If nausea and vomiting continues, call your doctor.

PAIN

- Take pain medication as directed by your doctor.
- Call your doctor if pain is **NOT** relieved by medication.
- **DO NOT** take aspirin or blood thinners unless directed by your doctor.

CALL YOUR DOCTOR IF

- Excessive bleeding that does not stop after holding pressure over the area
- Temperature of 101 degrees F or above
- Excessive redness, swelling or bruising, and/ or green or yellow, smelly discharge from incision

AFTER ANESTHESIA

- For the first 24 hours: **DO NOT** Drive, Drink alcoholic beverages, or Make **important** decisions.
- Be aware of dizziness following anesthesia and while taking pain medication.

DISCHARGE SUMMARY from Nurse

PATIENT INSTRUCTIONS:

After general anesthesia or intravenous sedation, for 24 hours or while taking prescription Narcotics:

- Limit your activities
- Do not drive and operate hazardous machinery
- Do not make important personal or business decisions
- Do not drink alcoholic beverages
- If you have not urinated within 8 hours after discharge, please contact your surgeon on call.

- * Please give a list of your current medications to your Primary Care Provider.
- * Please update this list whenever your medications are discontinued, doses are changed, or new medications (including over-the-counter products) are added.
- * Please carry medication information at all times in case of emergency situations.

These are general instructions for a healthy lifestyle:

No smoking/ No tobacco products/ Avoid exposure to second hand smoke

Surgeon General's Warning: Quitting smoking now greatly reduces serious risk to your health.

Obesity, smoking, and sedentary lifestyle greatly increases your risk for illness

A healthy diet, regular physical exercise & weight monitoring are important for maintaining a healthy lifestyle

You may be retaining fluid if you have a history of heart failure or if you experience any of the following

Alston, Nathaniel

symptoms: Weight gain of 3 pounds or more **overnight** or 5 pounds in a week, increased swelling in our hands or feet or shortness of breath while lying flat in bed. Please call your doctor as soon as you notice any of these symptoms; do not wait until your next office visit.

Recognize signs and symptoms of **STROKE**:

F-face looks uneven

A-arms unable to move or move unevenly

S-speech slurred or non-existent

T-time-call 911 as soon as signs and symptoms begin-DO NOT go
Back to bed or wait to see if you get better-**TIME IS BRAIN.**



Providers Seen During Your Hospitalization

Provider	Specialty	Primary office phone
John H Paylor III, MD	Orthopedic Surgery	864-234-7654

Your Primary Care Physician (PCP)

Primary Care Physician	Office Phone	Office Fax
NONE	** None **	** None **

You are allergic to the following

Allergen	Reactions
Tramadol	Nausea and Vomiting

Recent Documentation

Weight	BMI	Smoking Status
147.1 kg	43.97 kg/m2	Current Every Day Smoker

Emergency Contacts

Name	Discharge Info	Relation	Home	Work	Mobile
Alston, Andrea		Spouse [3]	864-593-7137		864-593-7137

Patient Belongings

The following personal items are in your possession at time of discharge:
Visual Aid: None Jewelry: None Clothing: Undergarments, Footwear, Shirt, Pants

Please provide this summary of care documentation to your next provider.

Signatures-by signing, you are acknowledging that this After Visit Summary has been reviewed with you and you have received a copy.

Alston, Nathaniel

Patient Signature: _____

Date: _____

Provider Signature: _____

Date: _____



BON SECOURS HEALTH SYSTEM, INC.

BON SECOURS HEALTH SYSTEM

**1 Saint Francis Dr
Greenville SC 29601
864-255-1248**

Patient: Nathaniel Alston
MRN: XXXXX7975
DOB: 11/24/1972

My Medications

STOP taking these medications

HYDROcodone-acetaminophen 10-325 mg tablet
Commonly known as: NORCO

TAKE these medications as instructed

		Each Dose to:	Morning	Noon	Evening	Bedtime
		Equal				
<p>amLODIPine 5 mg tablet Commonly known as: NORVASC</p> <p>Your last dose was:</p> <p>Your next dose is:</p>	<p>Instructions: Take 5 mg by mouth nightly. Indications: hypertension</p>	5 mg				
<p>cyclobenzaprine 10 mg tablet Commonly known as: FLEXERIL</p> <p>Your last dose was:</p> <p>Your next dose is:</p>	<p>Take 10 mg by mouth three (3) times daily.</p>	10 mg				
<p>diclofenac 1 % Gel Commonly known as: VOLTAREN</p> <p>Your last dose was:</p> <p>Your next dose is:</p>	<p>Apply to affected area every six (6) hours.</p>					
<p>DULoxetine 60 mg capsule Commonly known as: CYMBALTA</p> <p>Your last dose was:</p> <p>Your next dose is:</p>	<p>Take 60 mg by mouth nightly.</p>	60 mg				

My Medications (continued)

TAKE these medications as instructed (continued)

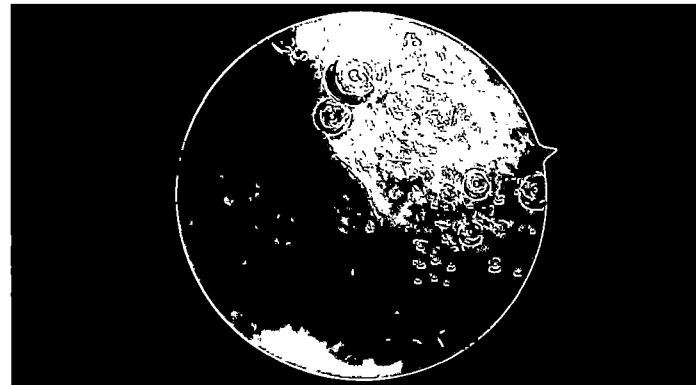
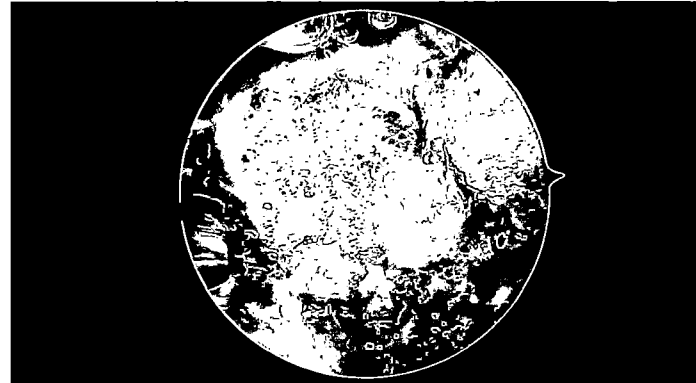

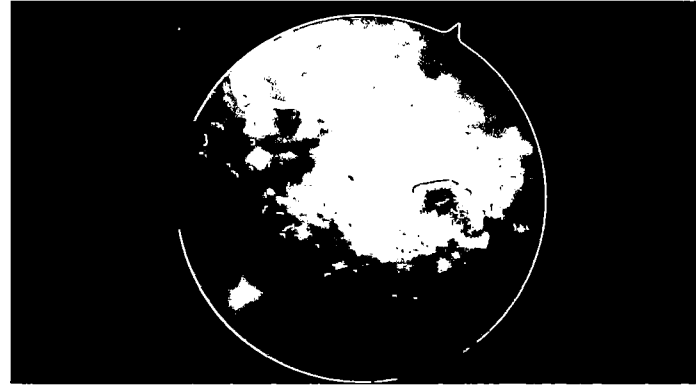
	Instructions:	Each Dose to Equal	Morning	Noon	Evening	Bedtime
<p>gabapentin 600 mg tablet Commonly known as: NEURONTIN</p> <p>Your last dose was:</p> <p>Your next dose is:</p>	<p>Take 600 mg by mouth three (3) times daily.</p>	600 mg				
<p>ibuprofen 600 mg tablet Commonly known as: MOTRIN</p> <p>Your last dose was:</p> <p>Your next dose is:</p>	<p>Take 1 Tab by mouth every six (6) hours as needed for Pain. Indications: Pain</p>	600 mg				
<p>oxyCODONE-acetaminophen 5-325 mg per tablet Commonly known as: PERCOET</p> <p>Your last dose was:</p> <p>Your next dose is:</p>	<p>Take 1 Tab by mouth every four (4) hours as needed for Pain. Max Daily Amount: 6 Tabs.</p>	1 Tab				

Where to Get Your Medications

Information on where to get these meds will be given to you by the nurse or doctor.

Ask your nurse or doctor about these medications:

- ibuprofen 600 mg tablet
- oxyCODONE-acetaminophen 5-325 mg per tablet



RULE 208 & 209

PROOF OF SERVICE OF A NOTICE OF APPEAL

THE STATE OF SOUTH CAROLINA

In The Court of Appeals

APPEAL FROM THE WORKERS' COMPENSATION COMMISSION

Appellate Case No. 2017-002126

Nathaniel Alston

Appellant,

v.

All My Sons Moving and Storage Employer

And Vanliner Insurance Carrier

Respondent.

PROOF OF SERVICE

I certify that I served the Rule 208 brief & 209 Designation of Matter to be included in the Record of Appeal to George Gallagher at Speed, Seta, Martin, Trivett & Stubley, LLC, PO Box 11669, Columbia, South Carolina 29211 and South Carolina Courts of Appeals, Jenny Abbott Kitchings, Clerk, PO Box 11629, Columbia, SC 29211 by depositing a copy of it in the United States Mail, postage prepaid, on January 31, 2018, addressed to attorney George Gallagher at Speed, Seta, Martin, Trivett & Stubley, LLC, PO Box 11669, Columbia, South Carolina 29211 and South Carolina Courts of Appeal, Jenny Abbott Kitchings, Clerk, PO Box 11629, Columbia, SC 29211, on January 31, 2018.

January 31, 2018

s/ Nathaniel Alston

Nathaniel Alston

RECEIVED
FEB 02 2018
SC Court of Appeals


150 Howell Cir Apt 253

Greenville, South Carolina 29615


(864) 593-3427

Representative of Self- Appellant

From: Nathaniel Alston
105 Howell Circle Apt 253
Greenville, S.C. 29615



U.S. POSTAGE
PAID
GREENVILLE, SC
PERMIT
NO. 100
JAN 1991
AMOUNT
\$5.50
R2304M13123-14



RECEIVED

FEB 02 2018
SC Court of Appeals

South Carolina Courts of Appeals
TO: Jenny Abbott Kitching (Clerk)
P.O. Box 11629
Columbia, S.C. 29211

v
v
v
v
v