THE STATE OF SOUTH CAROLINA
In The Court of Appeals

---

APPEAL FROM SOUTH CAROLINA
Workers' Compensation Commission

RECEIVED
SEP 09 2019
SC Court of Appeals

---

Appellate Case No.: 2018-000965

---

Victor G. Benjamin, Employee,.....Appellant,

v.

Rexam Beverage Can Company d/b/a Rexam Beverages, Employer, and
Hartford Insurance Company of the Midwest c/o Sedgwick CMS, Carrier,..... Respondents.

---

**RECORD ON APPEAL**

---

Stephen B. Samuels
SAMUELS LAW FIRM, LLC
1320 Richland Street
Columbia, SC 29201
(803) 779-4000

Jeff C. Chandler
CHANDLER LAW FIRM
2501 North Oak Street
Myrtle Beach, SC 29577
(843) 448-4357

**ATTORNEYS FOR APPELLANT**

Jason W. Lockhart, Esquire
MCANGUS GOUDELOCK & COURIE, LLC
Post Office Box 12519
Columbia, SC 29211
(803) 779-2300

Helen F. Hiser, Esquire
MCANGUS GOUDELOCK & COURIE, LLC
Post Office Box 650007
Mt. Pleasant, SC 29465
(843) 576-2900

**ATTORNEYS FOR RESPONDENTS**

Volume II

# INDEX


I. **ORDERS** ..... **1**

Decision and Order filed September 17, 2014 ..... 1

Appellate Panel Decision and Order filed April 23, 2015 ..... 20

Decision and Order filed July 21, 2017 ..... 48

Appellant Panel Decision and Order filed April 24, 2018 ..... 74

II. **PLEADINGS** ..... **105**

Form 50 of June 20, 2011 ..... 105

Form 50 of May 3, 2016 ..... 106

Form 51 of June 2, 2016 ..... 107

Claimant's Form 58 of August 2, 2016 ..... 109

Claimant's APA Submissions ..... 111

McLeod Regional Medical Center ..... 111

Florence Neurosurgery & Spine ..... 123

Pee Dee Orthopaedic Associates ..... 128

Grand Strand Specialty Associates ..... 129

Grand Strand Psychological Services ..... 228

Post Trauma Resources ..... 406

Dynamic Physical Therapy ..... 497

Southeastern Spine Institute ..... 572

Columbia Neurosurgical Associates ..... 620

Conway Hospital Community Services ..... 652

Florence Neurosurgery & Spine ..... 668

Coastal Orthopedic Associates ..... 675

Vocational Assessment by Dr. Robert Brabham ..... 678

Defendants' APA Submissions ..... 693
McLeod Regional Medical Center ..... 693
Pee Dee Orthopaedic Associates, PA ..... 697
Columbia Neurosurgical at Midlands Ortho ..... 705
Florence Neurosurgery & Spine, PC ..... 713
Florence MRI and Imaging ..... 717
ImageCare, LLC ..... 721
Florence MRI and Imaging ..... 722
Post Trauma Resources ..... 724
Southeastern Spine Institute ..... 745
Conway Physicians Group ..... 765
Sedgwick Surveillance Reports ..... 822

Form 30 of August 3, 2017 ..... 830

Claimant/Appellants' Brief to Full Commission ..... 833

**III. TRANSCRIPTS ..... 849**

Deposition of Victor G. Benjamin of March 2, 2012 ..... 849
Caption ..... 850
Examination by Ms. Hyatt ..... 851
Pgs. 15 – 19 ..... 851
Pgs. 21 – 22 ..... 853
Pgs. 29 – 32 ..... 854
Pgs. 45 – 48 ..... 855
Pg. 51 ..... 856

Deposition of Victor G. Benjamin of March 31, 2014 ..... 857
Caption ..... 857
Examination by Mr. Lockhart ..... 858
Pg. 24 ..... 858
Pgs. 27 – 29 ..... 859
Pgs. 52 – 54 ..... 861

Deposition of Karl Lozanne, M.D. of May 21, 2014 ..... 863
Caption ..... 863
Examination by Mr. Lockhart ..... 865
Pg. 4 ..... 865
Pgs. 13 – 21 ..... 866
Re-examination by Mr. Lockhart ..... 875
Pgs. 49 – 50 ..... 875

Transcript of Proceedings before Commissioner Susan Barden of June 23, 2014 ..... 877
Victor G. Benjamin ..... 880
Direct Examination by Mr. Chandler ..... 880
Pgs. 21 – 27 ..... 880
Pg. 30 ..... 887
Pg. 34 ..... 888
Cross Examination by Mr. Lockhart ..... 889
Pgs. 43 – 46 ..... 889

Deposition of Karl Lozanne, M.D. of July 7, 2016 ..... 893
Caption ..... 893
Examination by Mr. Lockhart ..... 895
Cross-examination by Mr. Chandler ..... 910
Defendant's Exhibit No. 1 ..... 921

Transcript of Proceedings before Commissioner Aisha Taylor of August 18, 2016 ..... 947
Victor G. Benjamin ..... 958
Direct Examination by Mr. Chandler ..... 958
Cross Examination by Mr. Lockhart ..... 997
Letia Anderson Benjamin ..... 1032
Direct Examination by Mr. Chandler ..... 1032
Cross Examination by Mr. Lockhart ..... 1057

**IV. CERTIFICATE OF COUNSEL ..... 1078**

DYNAMIC PHYSICAL THERA. .
OF FLORENCE

2724 W. Palmetto Street, Suite 2
Florence, SC USA 29526
Phone: (843) 292-1900 Fax: (843) 292-1902

Patient: Victor Benjamin
Acct #: [redacted]
DOB: [redacted]
Physician: George Sandoz
Phys Fax: (843) 692-2145
Physician: Not Specified
Clinician: Leah Hamoy
FSC: Workers Compensation
Case Mgr:
Payor:
Pol/Claim#:

Visit Date: Sep 18, 2012
Phys Phone: (843) 234-1710
SSN: [redacted]
Inj. Date:
Surg. Date:
Visits: 1
Cxl/Ns: 0
Employer:
Insured:

# Initial Evaluation

## Diagnoses

Spine

| | |
|---|---|
| 72291 | DISC DIS NEC/NOS-CERV |
| 7231 | CERVICALGIA |
| 7234 | BRACHIAL NEURITIS NOS |
| 72887 | MUSCLE WEAKNESS-GENERAL |

## General Information

**History of Injury:**

- Pt states that a piece of guard rail from 25 ft high feel on his head and R forearm causing tendons to be torn. Pt underwent surgery but never regained full function back. Pt states he can't make a fist yet but was released from therapy for the R hand. Pt is unable to perform any of the chores that he used to do before and hasn't tried to since the heat bothers him. He has pinched nerves in the neck causing numbness and tingling down RUE. Pt states he is able to perform BADLS by himself, but did need help from his wife until September last year. Pt had severe pain in lateral side of LLE which the doctor told him was coming from the neck and also informed him that he would be in pain the rest of his life. Neck hurts on the R side but more comfortable turning the head to R, hurts more to the L. Pt is taking seizure medication which has diminished his seizures. Pt also has balance problems which has caused falls in the past.

**Occupation:**

- Employer: Rexam Job Title: forklift operator, required to do heavy lifting

**tient / Concerns / Goals:**

- get better, feel less pain

**Summary List: Current Medication: Prescription:**

- Medication 1: valium Medication 2: xanax

## Subjective Examination

**The patient's medical history has been verbally reviewed with the patient by the evaluating therapist. The medical history questionnaire has been completed and signed by the patient, reviewed by the evaluating therapist, and is on file. The patient has read and signed the Patient Rights and Consent for Treatment forms, they have been reviewed by the evaluating therapist, and are on file.**

**ADL / Functional Status:**

- ADL's: awaken frequently at noc even medications, 2-3 hrs at the most, gets nightmares, sit 2 hrs at the most, stand w/ good tolerance Premorbid status: Work status: Unable to work secondary to dysfunction. Current status: Work status: Unable to work secondary to dysfunction.
- Premorbid status: Basic care:
  - Independent With Increased Time. Independent With Difficulty.

**Chief Complaint: Pain:**

- Current Severity: 5/10. Severity at Best: 3/10. Severity at Worst: 8/10.

**Daily Comments:**

- Pt reports current pain level of 5-6/10. Overall Condition is: A little better.

**Functional Capability:**

- Working Status: Unable to Work Due to Injury. Premorbid ADL Capacity: Unrestricted/Fully Able.

**Questionnaires:**

- NDI 62%

**Rehabilitation Expectations/Goals:**

- Return to Work Activities: Restricted/Minimal Symptoms.

## ...jective Examination

[redacted]

| Muscle Testing: Cervical Planes: | Left | Right |
|---|---|---|
| • Extension | 4/5 | |
| • Flexion | 3/5 | |
| • Rotation | 4/5 | 4/5 |
| • Side Bending | +4/5 | +4/5 |
| **Muscle Testing: Upper Extremity MMT:** | **Left** | **Right** |
| • Shoulder Abduction | | +3/5 |
| • Shoulder Flexion | 4/5 | +3/5 |
| • Shoulder External Rotation | +4/5 | +4/5 |
| • Shoulder Internal Rotation | +4/5 | +4/5 |
| **Muscle Testing: Grip/Pinch: Five Position Grip Test: Grip Dynamometer III:** | **Left** | **Right** |
| • Gross Assessment | 95 | 30 |

**Palpation:**
- Cervical Region: HYPMOBILITY IN OA JOINT, WNL AA JT,TENDERNESS IN R FACETS THAN L, TENDERNESS IN CERVICOTHORACIC MUSCLES

**Range of Motion: Spine: Cervical Degrees:**

| | |
|---|---|
| • Active Extension. | 60 Degrees |
| • Active Flexion | 30 Degrees |
| • Active Rotation Left | 60 Degrees |
| • Active Rotation Right | 60 Degrees |
| • Active Side Bend Left | 30 Degrees |
| • Active Side Bend Right | 25 Degrees |

# Treatments

| | |
|---|---|
| **Exercise Activities: Aerobic Conditioning:** Airgometer (Airdyne) | Time Elapsed: 10 Minutes, Additional Detail: UE, Charge As: Therapeutic Exercise, Billing Code: 97110. |
| **Exercise Activities: Isometrics:** • Isometric Activity 1 | Time Elapsed: 8 Minutes, Repetitions: 10, Side: Bilateral, Description: cervical each way, Charge As: Therapeutic Exercise, Billing Code: 97110. |
| **Exercise Activities: Flexibility(U. Quarter):** • Cervicothoracic Musculature | Time Elapsed: 4 Minutes, Repetitions: 3 each ways, Body Position: Seated, Hold.: 15 Seconds, Additional Detail: UTM,lev scap,bicep/pec,upper thoracic, Charge As: Therapeutic Exercise, Billing Code: 97110. |
| **Exercise Activities: Isotonics(U. Quarter):** | |
| • Prone Horizontal Abduction/ER | Time Elapsed: 2 Minutes, Repetitions: 10, Sets: 1, Charge As: Therapeutic Exercise, Billing Code: 97110. |
| • Shoulder Shrugs | Time Elapsed: 2 Minutes, Weight - Pounds: 2 Pounds, Repetitions: 10, Sets: 2, Charge As: Therapeutic Exercise, Billing Code: 97110. |
| • Isotonic Activity 1 | Time Elapsed: 4 Minutes, Repetitions: 10, Sets: 1, Side: Bilateral, Description: AROM each way, Charge As: Therapeutic Exercise, Billing Code: 97110. |
| **Manual Interventions: Upper Quarter Soft Tissue:** • Cervicothoracic PVM | Time Elapsed: 13 Minutes, Tx Depth: Moderate, Side: Bilateral, Technique: Strumming, Direction: Multidirectional, Assisting Technique: Tissue Elongation, Additional Detail: soft tissue mob, Charge As: Manual Therapy Techniques, Billing Code: 97140. |
| **Modalities:** | |

- Electric Stim, Unattended

Time Elapsed: 15 Minutes, Location: Posterior, Performed With: Moist Heat, Mode: Continuous, Type: Interferential, Additional Detail: CT spine, Clinical Use: Post Activity, Charge As: E-Stim, Unattended, Billing Code: 97014.

**Therapy Session Time**
- Total Therapy Session Time 60 Minutes

**Documented Procedural Code Summary:**

| Description | Code | Units | Minutes |
|---|---|---|---|
| • Electrical Stimulation (unattended) | 97014 | 1 | n/a |
| • Manual Therapy Techniques | 97140 | 1 | 13 |
| • Therapeutic Procedure | 97110 | 2 | 30 |

**Timed Code Total Time:**
- 43 Minutes

## Assessment

In my professional opinion, this client requires skilled rehabilitative therapy in conjunction with a home exercise program to address the problems and achieve the goals outlined below. Overall rehabilitation potential is good. The patient and/or family were educated regarding their diagnosis, prognosis and related pathology. The client exhibits good understanding and performance of the therapeutic activity and instructions outlined in this skilled rehabilitation session. The potential for continued improvement with skilled therapeutic intervention is good. The potential for continued progress toward the established rehabilitation goals is good.

**Impairments Identified:**
- Balance. ADL's. Functional Activities. Pain. Range of Motion. Recreational Activities. Strength. Weakness. Work Capacity.

**Presentation:**
- Severe Limitations In: ADL Function.
- Moderate Limitations In: Muscular Performance due to:
  - Weakness. Radiating Pain.

Displays signs and symptoms of: Cervical Spine:
- Neural compression: affecting right upper extremity. Mechanical derangement.

## Problems & Goals

*Problem #1* **Chief Complaint: Pain: Severity at Worst: 8/10.**
*STG Achieve by Oct 09, 2012.*
**Symptomatic Improvements:**
- Decreasing Pain: Decrease worst pain to 3/10 to sleep 4 hrs undisturbed

*Problem #2* **Questionnaires: NDI 62%**
*STG Achieve by Oct 02, 2012.*
**Functional Improvements In:**
- Functional Independence/Assessment Measure: Decrease NDI to 50% to show inc functional activity tolerance

*Problem #3* **Muscle Testing: Upper Extremity MMT.**
*STG Achieve by Oct 09, 2012.*

| Musculoskeletal Improvements In: Upper Extremity Strength to: | Right |
|---|---|
| • Gross Assessment | +4/5 |

## Plan

The goals and plan were discussed with the patient and/or family and they concur. The patient was instructed in the independent performance of a home exercise program that addresses the problems and achieving the goals outlined in the plan of care.

**Amount, Frequency and Duration:**
- Frequency and Duration: It is recommended that the client attend rehabilitative therapy for 2 visits a week with an expected duration of 3 weeks. Interventions during the course of treatment will be directed toward addressing the problems and achieving the goals previously outlined.

**apeutic Contents:**

- Active Range of Motion Activities. Client Education. Home Exercise Program. Joint Mobilization Techniques. Manual Therapy Techniques. Neural Mobilization Techniques. Postural Stabilization Training: Neutral Principle Training. Soft Tissue Mobilization Techniques. Self Care/Home Management. Stretching/Flexibility Activities. Therapeutic Activities. Therapeutic Exercise.
- Resistive Activities:
  - Isometric. Isotonic. Plyometric. Tubing/Bands. Machines/Free Weights.

Electronically authenticated.

Leah Hamoy, DPT(SC Lic: 2655)
Signed on Sep 18, 2012 15:03:23

DYNAMIC PHYSICAL THERA
OF FLORENCE

2724 W. Palmetto Street, Suite 2
Florence, SC USA 29526
Phone: (843) 292-1900 Fax: (843) 292-1902

Patient: Victor Benjamin
Physician: George Sandoz
Phy Phone: (843) 234-1710
Phy Fax: (843) 692-2145
Clinician: Leah Hamoy
Case Mgr:
Inj. Date:
Surg. Date:
Visits: 1
Cxl/Ns: 0

Acct: [redacted]
Visit Date: Sep 18, 2012
DOB:
SSN: [redacted]
FSC: Workers Compensation
Payor:
Pol/Claim#:
Name of Insured:
Employer:

# Plan of Care

## Diagnoses Spine

| | |
|---|---|
| 72291 | DISC DIS NEC/NOS-CERV |
| 7231 | CERVICALGIA |
| 7234 | BRACHIAL NEURITIS NOS |
| 72887 | MUSCLE WEAKNESS-GENERAL |

## Assessment

**In my professional opinion, this client requires skilled rehabilitative therapy in conjunction with a home exercise program to address the problems and achieve the goals outlined below. Overall rehabilitation potential is good. The patient and/or family were educated regarding their diagnosis, prognosis and related pathology. The client exhibits good understanding and performance of the therapeutic activity and instructions outlined in this skilled rehabilitation session. The potential for continued improvement with skilled therapeutic intervention is good. The potential for continued progress toward the established rehabilitation goals is good.**

**Impairments Identified:**

- Balance. ADL's. Functional Activities. Pain. Range of Motion. Recreational Activities. Strength. Weakness. Work Capacity.

**Presentation:**

- Severe Limitations In: ADL Function.
- Moderate Limitations In: Muscular Performance due to:
  - Weakness. Radiating Pain.
- Displays signs and symptoms of: Cervical Spine:
  - Neural compression: affecting right upper extremity. Mechanical derangement.

## Problems & Goals

*Problem #1* **Chief Complaint: Pain: Severity at Worst: 8/10.**

*STG Achieve by Oct 09, 2012.*

**Symptomatic Improvements:**

- Decreasing Pain: Decrease worst pain to 3/10 to sleep 4 hrs undisturbed

*Problem #2* **Questionnaires: NDI 62%**

*STG Achieve by Oct 02, 2012.*

**Functional Improvements In:**

- Functional Independence/Assessment Measure: Decrease NDI to 50% to show inc functional activity tolerance

*Problem #3* **Muscle Testing: Upper Extremity MMT.**

| | Left | Right |
|---|---|---|
| • Shoulder Abduction | | +3/5 |
| • Shoulder External Rotation | +4/5 | +4/5 |
| • Shoulder Flexion | 4/5 | +3/5 |
| • Shoulder Internal Rotation | +4/5 | +4/5 |

*STG Achieve by Oct 09, 2012.*

**Musculoskeletal Improvements In: Upper Extremity Strength to:**

| | Right |
|---|---|
| • Gross Assessment | +4/5 |

## Plan

**The goals and plan were discussed with the patient and/or family and they concur. The patient was instructed in the independent performance of a home exercise program that addresses the problems and achieving the goals outlined in the plan of care.**

Document ID: 00200D32.002
Leah Hamoy,DPT(SC Lic: 2655)

Status: Signed off (secure electronic signature)

**Amount, Frequency and Duration:**

- Fre[redacted]ration: It is recommended that the client attend rehabilitative therapy for 2 visits a week with an expected duration of 3 [redacted] weeks. Interventions during the course of treatment will be directed toward addressing the problems and achieving the goals previously outlined.

**Therapeutic Contents:**

- Active Range of Motion Activities. Client Education. Home Exercise Program. Joint Mobilization Techniques. Manual Therapy Techniques. Neural Mobilization Techniques. Postural Stabilization Training: Neutral Principle Training. Soft Tissue Mobilization Techniques. Self Care/Home Management. Stretching/Flexibility Activities. Therapeutic Activities. Therapeutic Exercise.
- Resistive Activities:
  - Isometric. Isotonic. Plyometric. Tubing/Bands. Machines/Free Weights.

Electronically authenticated on 9/18/2012 15:03:23

Leah Hamoy, DPT(SC Lic: 2655)

## Please sign and return

I have reviewed this Plan of Care and certify that the skilled therapy services identified are required to meet the patient's need. Comments and/or revisions to this Plan of Care are noted below.

**Comments/Revisions**

**Physician Signature** **Date**

DYNAMIC PHYSICAL THERAP
OF FLORENCE

2724 W. Palmetto Street, Suite 2
Florence, SC USA 29526
Phone: (843) 292-1900 Fax: (843) 292-1902

| | | | |
|---|---|---|---|
| Patient: | Victor Benjamin | Visit Date: | Sep 19, 2012 |
| Physician: | George Sandoz | DOB: | |
| Phy Phone: | (843) 234-1710 | SSN: | |
| Phy Fax: | (843) 692-2145 | FSC: | Workers Compensation |
| Clinician: | Leah Hamoy | Payor: | |
| Case Mgr: | | Pol/Claim#: | |
| Inj. Date: | | Name of Insured: | |
| Surg. Date: | | Employer: | |
| Visits: | 2 | | |
| Cxl/Ns: | 0 | | |

# Daily Note

## Diagnoses Spine

| | |
|---|---|
| 72291 | DISC DIS NEC/NOS-CERV |
| 7231 | CERVICALGIA |
| 7234 | BRACHIAL NEURITIS NOS |
| 72887 | MUSCLE WEAKNESS-GENERAL |

## General Information

**History of Injury:**

- Pt states that a piece of guard rail from 25 ft high feel on his head and R forearm causing tendons to be torn. Pt underwent surgery but never regained full function back. Pt states he can't make a fist yet but was released from therapy for the R hand. Pt is unable to perform any of the chores that he used to do before and hasn't tried to since the heat bothers him. He has pinched nerves in the neck causing numbness and tingling down RUE. Pt states he is able to perform BADLS by himself, but did need help from his wife until September last year. Pt had severe pain in lateral side of LLE which the doctor told him was coming from the neck and also informed him that he would be in pain the rest of his life. Neck hurts on the R side but more comfortable turning the head to R, hurts more to the L. Pt is taking seizure medication which has diminished his seizures. Pt also has balance problems which has caused falls in the past.

**Occupation:**

- Employer: Rexam Job Title: forklift operator, required to do heavy lifting

**Patient / Concerns / Goals:**

- get better, feel less pain

**Summary List: Current Medication: Prescription:**

- Medication 1: valium Medication 2: xanax

## Subjective Examination

**ADL / Functional Status:**

- ADL's: awaken frequently at noc even medications, 2-3 hrs at the most, gets nightmares, sit 2 hrs at the most, stand w/ good tolerance

**Chief Complaint:**

- Pain: Severity at Worst: 8/10.

**Daily Comments:**

- Pt reports tingling and numbness in his right and pain in his neck, somewhat decrease just a little today. Has an MD appt next Wed.

**Questionnaires:**

- NDI 62%

## Objective Examination

| Muscle Testing: Cervical Planes: | Left | Right |
|---|---|---|
| • Extension | 4/5 | |
| • Flexion | 3/5 | |
| • Rotation | 4/5 | 4/5 |
| • Side Bending | +4/5 | +4/5 |

| Muscle Testing: Upper Extremity MMT: | Left | Right |
|---|---|---|
| • Shoulder Abduction | | +3/5 |
| • Shoulder Flexion | 4/5 | +3/5 |
| • Shoulder External Rotation | +4/5 | +4/5 |
| • Shoulder Internal Rotation | +4/5 | +4/5 |

| Muscle Testing: Grip/Pinch: Five Position Grip Test: Grip Dynamometer III: | Left | Right |
|---|---|---|
| • Gross Assessment | 95 | 30 |

**Range of Motion: Spine: Cervical Degrees:**

| | |
|---|---|
| • Active Extension. | 60 Degrees |
| • Active Flexion | 30 Degrees |
| • Active Rotation Left | 60 Degrees |
| • Active Rotation Right | 60 Degrees |
| • Active Side Bend Left | 30 Degrees |
| • Active Side Bend Right | 25 Degrees |

# Treatments

**Exercise Activities: Aerobic Conditioning:**
- Airgometer (Airdyne)

Time Elapsed: 10 Minutes, Additional Detail: UE, Charge As: Therapeutic Exercise, Billing Code: 97110.

**Exercise Activities: Isometrics:**
- Isometric Activity 1

Time Elapsed: 8 Minutes, Repetitions: 10, Side: Bilateral, Description: cervical each way, Charge As: Therapeutic Exercise, Billing Code: 97110.

**Exercise Activities: Flexibility(U. Quarter):**
- Cervicothoracic Musculature

Time Elapsed: 4 Minutes, Repetitions: 3 each ways, Body Position: Seated, Hold.: 15 Seconds, Additional Detail: UTM,lev scap,bicep/pec,upper thoracic, Charge As: Therapeutic Exercise, Billing Code: 97110.

**Exercise Activities: Isotonics(U. Quarter):**
- Prone Horizontal Abduction/ER.

Time Elapsed: 2 Minutes, Repetitions: 10, Sets: 1, Charge As: Therapeutic Exercise, Billing Code: 97110.

Shoulder Shrugs

Time Elapsed: 2 Minutes, Weight - Pounds: 2 Pounds, Repetitions: 10, Sets: 2, Charge As: Therapeutic Exercise, Billing Code: 97110.

- Isotonic Activity 1

Time Elapsed: 4 Minutes, Repetitions: 10, Sets: 1, Side: Bilateral, Description: AROM each way, Charge As: Therapeutic Exercise, Billing Code: 97110.

**Exercise Activities: Tubing/Bands(U. Quarter):**
- Rows

Time Elapsed: 3 Minutes, Repetitions: 10, Sets: 3, Tubing/Band Color: Yellow, Resistance: Concentric/Eccentric, Additional Detail: standing, Charge As: Therapeutic Exercise, Billing Code: 97110.

- Tubing/Bands 1

Time Elapsed: 6 Minutes, Repetitions: 10, Sets: 3, Tubing/Band Color: Yellow, Resistance: Concentric/Eccentric, Additional Detail: standing bilateral hor abd and ER, Description: stabilization, Charge As: Therapeutic Exercise, Billing Code: 97110.

**Manual Interventions: Upper Quarter Soft Tissue:**
- Cervicothoracic PVM

Time Elapsed: 13 Minutes, Tx Depth: Moderate, Side: Bilateral, Technique: Strumming, Direction: Multidirectional, Assisting Technique: Tissue Elongation, Additional Detail: soft tissue mob, Charge As: Manual Therapy Techniques, Billing Code: 97140.

**Modalities:**
- Electric Stim, Unattended

Time Elapsed: 10 Minutes, Location: cervical, Performed With: Moist Heat, Mode: Continuous, Type: Interferential, Clinical Use: Post Activity, Charge As: E-Stim, Unattended, Billing Code: 97014.

**Documented Procedural Code Summary:**

| Description | Code | Units | Minutes |
|---|---|---|---|
| • Electrical Stimulation (unattended) | 97014 | 1 | n/a |
| Manual Therapy Techniques | 97140 | 1 | 13 |
| Therapeutic Procedure | 97110 | 3 | 39 |

**Timed Code Total Time:**
- 52 Minutes

## Assessment

**Signs/Symptoms:**
- Tingling: Unchanged with: exercise activity, but has slight relief following STM and modalities.

## Plan

**Daily Plan:**
- Continue w/ Current Rehabilitation Program.

Electronically authenticated on 9/19/2012 19:36:10
Cyreano Hamoy, PTA(SC Lic: 2464)
Under the direct supervision of the primary therapist.

Electronically authenticated on 9/21/2012 09:05:21
Leah Hamoy, DPT(SC Lic: 2655)

DYNAMIC PHYSICAL THERAP
OF FLORENCE

2724 W. Palmetto Street, Suite 2
Florence, SC USA 29526
Phone: (843) 292-1900 Fax: (843) 292-1902

'atient: Victor Benjamin
Acct #:
DOB:
Physician: George Sandoz
Phys Fax: (843) 692-2145
Physician: Not Specified
Clinician: Leah Hamoy
FSC: Workers Compensation
Case Mgr:
Payor:
Pol/Claim#:

Note Date: Sep 24, 2012
Phys Phone: (843) 234-1710
SSN:
Inj. Date: Jun 15, 2011
Surg. Date:
Visits: 3
Cxl/Ns: 0
Employer:
Insured:

# Progress Note

## Diagnoses Spine

| | |
|---|---|
| 72291 | DISC DIS NEC/NOS-CERV |
| 7231 | CERVICALGIA |
| 7234 | BRACHIAL NEURITIS NOS |
| 72887 | MUSCLE WEAKNESS-GENERAL |

## General Information

**History of Injury:**

- Pt states that a piece of guard rail from 25 ft high feel on his head and R forearm causing tendons to be torn. Pt underwent surgery but never regained full function back. Pt states he can't make a fist yet but was released from therapy for the R hand. Pt is unable to perform any of the chores that he used to do before and hasn't tried to since the heat bothers him. He has pinched nerves in the neck causing numbness and tingling down RUE. Pt states he is able to perform BADLS by himself, but did need help from his wife until September last year. Pt had severe pain in lateral side of LLE which the doctor told him was coming from the neck and also informed him that he would be in pain the rest of his life. Neck hurts on the R side but more comfortable turning the head to R, hurts more to the L. Pt is taking seizure medication which has diminished his seizures. Pt also has balance problems which has caused falls in the past.

**Occupation:**

- Employer: Rexam Job Title: forklift operator, required to do heavy lifting

**tient / Concerns / Goals:**

- get better, feel less pain

**Summary List: Current Medication: Prescription:**

- Medication 1: valium Medication 2: xanax

## Subjective Examination

**ADL / Functional Status:**

- ADL's: awaken frequently at noc even medications, 2-3 hrs at the most, gets nightmares, sit 2 hrs at the most, stand w/ good tolerance

**Chief Complaint: Pain:**

- Severity at Worst: 7/10. Severity at Best: 4/10.

**Questionnaires:**

- NDI 62%

## Objective Examination

| Muscle Testing: Cervical Planes: | Sep 18, 2012 Left | Sep 18, 2012 Right | Sep 24, 2012 Left | Sep 24, 2012 Right |
|---|---|---|---|---|
| • Extension | 4/5 | | -5/5 | |
| • Flexion | 3/5 | | -5/5 | |
| • Rotation | 4/5 | 4/5 | -5/5 | -5/5 |
| • Side Bending | +4/5 | +4/5 | -5/5 | -5/5 |

| Muscle Testing: Upper Extremity MMT: | Sep 18, 2012 Left | Sep 18, 2012 Right | Sep 24, 2012 Left | Sep 24, 2012 Right |
|---|---|---|---|---|
| • Shoulder Abduction | | +3/5 | -5/5 | 4/5 |
| • Shoulder Flexion | 4/5 | +3/5 | +4/5 | 4/5 |
| • Shoulder External Rotation | +4/5 | +4/5 | +4/5 | 4/5 |
| • Shoulder Internal Rotation | +4/5 | +4/5 | -5/5 | +4/5 |

| Muscle Testing: Grip/Pinch: Five Position Grip Test: Grip Dynamometer III: | Left | Right |
|---|---|---|
| • Gross Assessment | 95 | 30 |
| **Range of Motion: Spine: Cervical Degrees:** | Sep 18, 2012 | Sep 24, 2012 |
| • Active Extension. | 60 Degrees | 40 Degrees |
| • Active Flexion | 30 Degrees | 40 Degrees |
| • Active Rotation Left | 60 Degrees | 65 Degrees |
| • Active Rotation Right | 60 Degrees | 65 Degrees |
| • Active Side Bend Left | 30 Degrees | 35 Degrees |
| • Active Side Bend Right | 25 Degrees | 30 Degrees |

## Assessment

**Recommendations:**

• Re-Check with Physician. Pt may also benefit from further invasive medical intervention

**Signs/Symptoms:**

• Pt is making progress with cervical strength and stability. But worst pain levels continue to be severe. Pt also reports radiculopathy in BUE and sometimes BLE which cause loss of balance

## Plan

**Daily Plan:**

• Will follow up after pt's MD visit on Wed 9/26/12.

**Refer Client to:**

• Physician for Re-Check.

**Therapy Referral**

I have read the above report and request that my patient:

☐ Continue with treatment program as indicated above.
☐ Continue treatment program for ___ days/week for ___ weeks.
☐ Revise treatment program as indicated: _____
☐ Progress to a home exercise program.
☐ Be discharged.
☐ Other: _____

**Please sign and return**

_____ _____
**Physician/NPP Signature** **Date**

_____
**Print Name and Credentials**

Electronically authenticated.

_____
Leah Hamoy, DPT(SC Lic: 2655)
Signed on Sep 24, 2012 18:18:19

DYNAMIC PHYSICAL THERAP.
OF FLORENCE

2724 W. Palmetto Street, Suite 2
Florence, SC USA 29526
Phone: (843) 292-1900 Fax: (843) 292-1902

| | | | |
|---|---|---|---|
| Patient: | Victor Benjamin | Acct #: | |
| Physician: | George Sandoz | Visit Date: | Sep 25, 2012 |
| Phy Phone: | (843) 234-1710 | DOB: | |
| Phy Fax: | (843) 692-2145 | SSN: | |
| Clinician: | Leah Hamoy | FSC: | Workers Compensation |
| Case Mgr: | | Payor: | |
| Inj. Date: | Jun 15, 2011 | Pol/Claim#: | |
| Surg. Date: | | Name of Insured: | |
| Visits: | 4 | Employer: | |
| Cxl/Ns: | 0 | | |

# Daily Note

## Diagnoses Spine

| | |
|---|---|
| 72291 | DISC DIS NEC/NOS-CERV |
| 7231 | CERVICALGIA |
| 7234 | BRACHIAL NEURITIS NOS |
| 72887 | MUSCLE WEAKNESS-GENERAL |

## General Information

**History of Injury:**

- Pt states that a piece of guard rail from 25 ft high feel on his head and R forearm causing tendons to be torn. Pt underwent surgery but never regained full function back. Pt states he can't make a fist yet but was released from therapy for the R hand. Pt is unable to perform any of the chores that he used to do before and hasn't tried to since the heat bothers him. He has pinched nerves in the neck causing numbness and tingling down RUE. Pt states he is able to perform BADLS by himself, but did need help from his wife until September last year. Pt had severe pain in lateral side of LLE which the doctor told him was coming from the neck and also informed him that he would be in pain the rest of his life. Neck hurts on the R side but more comfortable turning the head to R, hurts more to the L. Pt is taking seizure medication which has diminished his seizures. Pt also has balance problems which has caused falls in the past.

**Occupation:**

Employer: Rexam Job Title: forklift operator, required to do heavy lifting

**Patient / Concerns / Goals:**

- get better, feel less pain

**Summary List: Current Medication: Prescription:**

- Medication 1: valium Medication 2: xanax

## Subjective Examination

**ADL / Functional Status:**

- ADL's: awaken frequently at noc even medications, 2-3 hrs at the most, gets nightmares, sit 2 hrs at the most, stand w/ good tolerance

**Chief Complaint:**

- Pain: Severity at Worst: 8/10.

**Daily Comments:**

- Pt stated his neck give him a "fit" after PT while he was waiting for his wife in the tire place but he does not feel it during exercises.

**Questionnaires:**

- NDI 62%

## Objective Examination

**Muscle Testing: Cervical Planes:**

| | Left | Right |
|---|---|---|
| • Extension | -5/5 | |
| • Flexion | -5/5 | |
| • Rotation | -5/5 | -5/5 |
| • Side Bending | -5/5 | -5/5 |

**Muscle Testing: Upper Extremity MMT:**

| | Left | Right |
|---|---|---|
| • Shoulder Abduction | -5/5 | 4/5 |
| • Shoulder Flexion | +4/5 | 4/5 |
| • Shoulder External Rotation | +4/5 | 4/5 |
| • Shoulder Internal Rotation | -5/5 | +4/5 |

| Muscle Testing: Grip/Pinch: Five Position Grip Test: Grip Dynamometer III: | Left | Right |
|---|---|---|
| • Gross Assessment | 95 | 30 |
| **Range of Motion: Spine: Cervical Degrees:** | | |
| • Active Extension. | 40 Degrees | |
| • Active Flexion | 40 Degrees | |
| • Active Rotation Left | 65 Degrees | |
| • Active Rotation Right | 65 Degrees | |
| • Active Side Bend Left | 35 Degrees | |
| • Active Side Bend Right | 30 Degrees | |

# Treatments

| | |
|---|---|
| **Exercise Activities: Aerobic Conditioning:** | |
| • Airgometer (Airdyne) | Time Elapsed: 10 Minutes, Additional Detail: UE, Charge As: Therapeutic Exercise, Billing Code: 97110. |
| **Exercise Activities: Isometrics:** | |
| • Isometric Activity 1 | Time Elapsed: 8 Minutes, Repetitions: 10, Side: Bilateral, Description: cervical each way, Charge As: Therapeutic Exercise, Billing Code: 97110. |
| **Exercise Activities: Flexibility(U. Quarter):** | |
| • Cervicothoracic Musculature | Time Elapsed: 4 Minutes, Repetitions: 3 each ways, Body Position: Seated, Hold.: 15 Seconds, Additional Detail: UTM,lev scap,bicep/pec,upper thoracic, Charge As: Therapeutic Exercise, Billing Code: 97110. |
| **Exercise Activities: Isotonics(U. Quarter):** | |
| • Prone Horizontal Abduction/ER. | Time Elapsed: 2 Minutes, Repetitions: 10, Sets: 1, Charge As: Therapeutic Exercise, Billing Code: 97110. |
| Shoulder Shrugs | Time Elapsed: 2 Minutes, Weight - Pounds: 2 Pounds, Repetitions: 10, Sets: 2, Charge As: Therapeutic Exercise, Billing Code: 97110. |
| • Isotonic Activity 1 | Time Elapsed: 3 Minutes, Repetitions: 10, Sets: 1, Side: Bilateral, Description: AROM each way, Charge As: Therapeutic Exercise, Billing Code: 97110. |
| **Exercise Activities: Tubing/Bands(U. Quarter):** | |
| • Rows | Time Elapsed: 3 Minutes, Repetitions: 10, Sets: 3, Tubing/Band Color: Yellow, Resistance: Concentric/Eccentric, Additional Detail: standing, Charge As: Therapeutic Exercise, Billing Code: 97110. |
| • Tubing/Bands 1 | Time Elapsed: 6 Minutes, Repetitions: 10, Sets: 3, Tubing/Band Color: Yellow, Resistance: Concentric/Eccentric, Additional Detail: standing bilateral hor abd and ER, Description: stabilization, Charge As: Therapeutic Exercise, Billing Code: 97110. |
| **Exercise Activities: Dynamic Training: C-K-C Activity ( U. Quarter):** | |
| • Push-Ups | Time Elapsed: 2 Minutes, Repetitions: 5, Sets: 3, Position: Into Wall, Charge As: Therapeutic Exercise, Billing Code: 97110. |
| **Manual Interventions: Upper Quarter Soft Tissue:** | |
| • Cervicothoracic PVM | Time Elapsed: 12 Minutes, Tx Depth: Moderate, Side: Bilateral, Technique: Strumming, Direction: Multidirectional, Assisting Technique: Tissue Elongation, Additional Detail: soft tissue mob, Charge As: Manual Therapy Techniques, Billing Code: 97140. |
| **Modalities:** | |
| • Electric Stim, Unattended | Time Elapsed: 10 Minutes, Location: cervical, Performed With: Moist Heat, Mode: Continuous, Type: Interferential, Clinical Use: Post Activity, Charge As: E-Stim, Unattended, Billing Code: 97014. |
| • Ultrasound | Time Elapsed: 10 Minutes, Location: Superior, Watts/cm2: 1.50, Charge As: Ultrasound, Billing Code: 97035. |

**Therapy Session Time**

- Total Therapy Session Time 75 Minutes

**Documented Procedural Code Summary:**

| Description | Code | Units | Minutes |
|---|---|---|---|
| • Electrical Stimulation (unattended) | 97014 | 1 | n/a |
| • Manual Therapy Techniques | 97140 | 1 | 12 |
| • Therapeutic Procedure | 97110 | 3 | 40 |
| • Ultrasound | 97035 | 1 | 10 |

**Timed Code Total Time:**

- 62 Minutes

## Assessment

**Signs/Symptoms:**

- Pt stated his neck feel better compared to last night but I still continue to feel tingling and numbness in my arm. MD visit for follow up tomorrow.

## Plan

**Daily Plan:**

- Will follow up after MD visit 9/26/12.

Electronically authenticated on 9/25/2012 15:50:24

Cyreano Hamoy, PTA(SC Lic: 2464)

Under the direct supervision of the primary therapist.

Electronically authenticated on 9/25/2012 17:09:56

Leah Hamoy, DPT(SC Lic: 2655)

DYNAMIC PHYSICAL THERAPY OF FLORENCE

2724 W. Palmetto Street, Suite 2
Florence, SC USA 29526
Phone: (843) 292-1900 Fax: (843) 292-1902

Patient: Victor Benjamin
Acct #:
DOB:
Physician: George Sandoz
Phys Fax: (843) 692-2145
Physician: Not Specified
Clinician: Leah Hamoy
FSC: Workers Compensation
Case Mgr:
Payor:
Pol/Claim#:

Visit Date: Oct 02, 2012
Phys Phone: [illegible]
SSN:
Inj. Date: Jun 15, 2011
Surg. Date:
Visits: 5
Cxl/Ns: 0
Employer:
Insured:

# Daily Note

## Diagnoses Spine

| | |
|---|---|
| 72291 | DISC DIS NEC/NOS-CERV |
| 7231 | CERVICALGIA |
| 7234 | BRACHIAL NEURITIS NOS |
| 72887 | MUSCLE WEAKNESS-GENERAL |

## General Information

**History of Injury:**

- Pt states that a piece of guard rail from 25 ft high feel on his head and R forearm causing tendons to be torn. Pt underwent surgery but never regained full function back. Pt states he can't make a fist yet but was released from therapy for the R hand. Pt is unable to perform any of the chores that he used to do before and hasn't tried to since the heat bothers him. He has pinched nerves in the neck causing numbness and tingling down RUE. Pt states he is able to perform BADLS by himself, but did need help from his wife until September last year. Pt had severe pain in lateral side of LLE which the doctor told him was coming from the neck and also informed him that he would be in pain the rest of his life. Neck hurts on the R side but more comfortable turning the head to R, hurts more to the L. Pt is taking seizure medication which has diminished his seizures. Pt also has balance problems which has caused falls in the past.

**Occupation:**

- Employer: Rexam Job Title: forklift operator, required to do heavy lifting

**Patient / Concerns / Goals:**

- get better, feel less pain

**Summary List: Current Medication: Prescription:**

- Medication 1: valium Medication 2: xanax

## Subjective Examination

**ADL / Functional Status:**

- ADL's: awaken frequently at noc even medications, 2-3 hrs at the most, gets nightmares, sit 2 hrs at the most, stand w/ good tolerance

**Chief Complaint:**

- Pain: Severity at Worst: 8/10.

**Daily Comments:**

- Pt reports continue PT per MD. Pt noticing neck muscle felt relax after PT. Physician Communication: Physician Comments/Outcome: Continue as Prescribed.

**Questionnaires:**

- NDI 62%

## Objective Examination

| Muscle Testing: Cervical Planes: | Left | Right |
|---|---|---|
| • Extension | -5/5 | |
| • Flexion | -5/5 | |
| • Rotation | -5/5 | -5/5 |
| • Side Bending | -5/5 | -5/5 |

| Muscle Testing: Upper Extremity MMT: | Left | Right |
|---|---|---|
| • Shoulder Abduction | -5/5 | 4/5 |
| • Shoulder Flexion | +4/5 | 4/5 |
| • Shoulder External Rotation | +4/5 | 4/5 |
| • Shoulder Internal Rotation | -5/5 | +4/5 |

| Muscle Testing: Grip/Pinch: Five Position Grip Test: Grip Dynamometer III: | Left | Right |
|---|---|---|
| • Gross Assessment | 95 | 30 |
| **Range of Motion: Spine: Cervical Degrees:** | | |
| • Active Extension. | 40 Degrees | |
| • Active Flexion | 40 Degrees | |
| • Active Rotation Left | 65 Degrees | |
| • Active Rotation Right | 65 Degrees | |
| • Active Side Bend Left | 35 Degrees | |
| • Active Side Bend Right | 30 Degrees | |

# Treatments

**Exercise Activities: Aerobic Conditioning:**
- Airgometer (Airdyne)

Time Elapsed: 10 Minutes, Additional Detail: UE, Charge As: Therapeutic Activities, Billing Code: 97530.

**Exercise Activities: Isometrics:**
- Isometric Activity 1

Time Elapsed: 8 Minutes, Repetitions: 10, Side: Bilateral, Description: cervical each way, Charge As: Therapeutic Exercise, Billing Code: 97110.

**Exercise Activities: Flexibility(U. Quarter):**
- Cervicothoracic Musculature

Time Elapsed: 4 Minutes, Repetitions: 3 each ways, Body Position: Seated, Hold.: 15 Seconds, Additional Detail: UTM,lev scap,bicep/pec,upper thoracic, Charge As: Therapeutic Exercise, Billing Code: 97110.

**Exercise Activities: Isotonics(U. Quarter):**
- Prone Horizontal Abduction/ER.

Time Elapsed: 2 Minutes, Repetitions: 10, Sets: 1, Charge As: Therapeutic Exercise, Billing Code: 97110.

- Shoulder Shrugs

Time Elapsed: 2 Minutes, Weight - Pounds: 2 Pounds, Repetitions: 10, Sets: 2, Charge As: Therapeutic Exercise, Billing Code: 97110.

- Isotonic Activity 1

Time Elapsed: 3 Minutes, Repetitions: 10, Sets: 1, Side: Bilateral, Description: AROM each way, Charge As: Therapeutic Exercise, Billing Code: 97110.

**Exercise Activities: Tubing/Bands(U. Quarter):**
- Rows

Time Elapsed: 3 Minutes, Repetitions: 10, Sets: 3, Tubing/Band Color: Yellow, Resistance: Concentric/Eccentric, Additional Detail: standing, Charge As: Therapeutic Exercise, Billing Code: 97110.

- Tubing/Bands 1

Time Elapsed: 6 Minutes, Repetitions: 10, Sets: 3, Tubing/Band Color: Yellow, Resistance: Concentric/Eccentric, Additional Detail: standing-bilateral hor abd and ER, Description: stabilization, Charge As: Therapeutic Exercise, Billing Code: 97110.

**Exercise Activities: Dynamic Training: C-K-C Activity ( U. Quarter):**
- Push-Ups

Time Elapsed: 3 Minutes, Repetitions: 10, Sets: 2, Position: Into Wall, Charge As: Therapeutic Exercise, Billing Code: 97110.

**Manual Interventions: Upper Quarter Soft Tissue:**
- Cervicothoracic PVM

Time Elapsed: 12 Minutes, Tx Depth: Moderate, Side: Bilateral, Technique: Strumming, Direction: Multidirectional, Assisting Technique: Tissue Elongation, Additional Detail: soft tissue mob, Charge As: Manual Therapy Techniques, Billing Code: 97140.

**Modalities:**
- Electric Stim, Unattended

Time Elapsed: 15 Minutes, Location: cervical, Performed With: Moist Heat, Mode: Continuous, Type: Interferential, Clinical Use: Post Activity, Charge As: E-Stim, Unattended, Billing Code: 97014.

- Ultrasound(This visit)

Did Not Perform: This visit

**Documented Procedural Code Summary:**

| Description | Code | Units | Minutes |
|---|---|---|---|

| | | | |
|---|---|---|---|
| • Electrical Stimulation (unattended) | 97014 | 1 | n/a |
| • Manual Therapy Techniques | 97140 | 1 | 12 |
| • Therapeutic Activities | 97530 | 1 | 10 |
| • Therapeutic Procedure | 97110 | 3 | 31 |

**Timed Code Total Time:**
- 53 Minutes

# Assessment

**Signs/Symptoms:**
- Pt continue working on flexibility, strengthening and stability. No significant changes on the tingling and numbness in his right arm.

# Plan

**Daily Plan:**
- Progress as Tolerated w/ the Addition of: Stretching/Flexibility Activities.

Electronically authenticated.

Cyreano Hamoy, PTA(SC Lic: 2464)
Signed on Oct 02, 2012 12:04:05
Under the direct supervision of the primary therapist.

Electronically authenticated.

Leah Hamoy, DPT(SC Lic: 2655)
Signed on Oct 02, 2012 17:56:12

DYNAMIC PHYSICAL THERAP.
OF FLORENCE

2724 W. Palmetto Street, Suite 2
Florence, SC USA 29526
Phone: (843) 292-1900 Fax: (843) 292-1902

Patient: Victor Benjamin
Acct #:
DOB:
Physician: George Sandoz
Phys Fax: (843) 692-2145
Physician: Not Specified
Clinician: Leah Hamoy
FSC: Workers Compensation
Case Mgr:
Payor:
Pol/Claim#:

Visit Date: Oct 03, 2012
Phys Phone: (843) 234-1710
SSN:
Inj. Date: Jun 15, 2011
Surg. Date:
Visits: 6
Cxl/Ns: 0
Employer:
Insured:

# Daily Note

## Diagnoses

Spine

| | |
|---|---|
| 72291 | DISC DIS NEC/NOS-CERV |
| 7231 | CERVICALGIA |
| 7234 | BRACHIAL NEURITIS NOS |
| 72887 | MUSCLE WEAKNESS-GENERAL |

## General Information

**History of Injury:**

- Pt states that a piece of guard rail from 25 ft high feel on his head and R forearm causing tendons to be torn. Pt underwent surgery but never regained full function back. Pt states he can't make a fist yet but was released from therapy for the R hand. Pt is unable to perform any of the chores that he used to do before and hasn't tried to since the heat bothers him. He has pinched nerves in the neck causing numbness and tingling down RUE. Pt states he is able to perform BADLS by himself, but did need help from his wife until September last year. Pt had severe pain in lateral side of LLE which the doctor told him was coming from the neck and also informed him that he would be in pain the rest of his life. Neck hurts on the R side but more comfortable turning the head to R, hurts more to the L. Pt is taking seizure medication which has diminished his seizures. Pt also has balance problems which has caused falls in the past.

**Occupation:**

- Employer: Rexam Job Title: forklift operator, required to do heavy lifting

**Patient / Concerns / Goals:**

- get better, feel less pain

**Summary List: Current Medication: Prescription:**

- Medication 1: valium Medication 2: xanax

## Subjective Examination

**ADL / Functional Status:**

- ADL's: awaken frequently at noc even medications, 2-3 hrs at the most, gets nightmares, sit 2 hrs at the most, stand w/ good tolerance

**Chief Complaint:**

- Pain: Severity at Worst: 8/10.

**Daily Comments:**

- Pt reports something he feels something on his hand and he thinks it's a bug but there's nothing there. Reports the pain in R shoulder blade has hurt since DOI.

**Questionnaires:**

- NDI 62%

## Objective Examination

**Muscle Testing: Cervical Planes:**

| | Left | Right |
|---|---|---|
| • Extension | -5/5 | |
| • Flexion | -5/5 | |
| • Rotation | -5/5 | -5/5 |
| • Side Bending | -5/5 | -5/5 |

**Muscle Testing: Upper Extremity MMT:**

| | Left | Right |
|---|---|---|
| • Shoulder Abduction | -5/5 | 4/5 |
| • Shoulder Flexion | +4/5 | 4/5 |
| • Shoulder External Rotation | +4/5 | 4/5 |
| • Shoulder Internal Rotation | -5/5 | +4/5 |

| Muscle Testing: Grip/Pinch: Five Position Grip Test: Grip Dynamometer III: | Left | Right |
|---|---|---|
| • Gross Assessment | 95 | 30 |
| **Range of Motion: Spine: Cervical Degrees:** | | |
| • Active Extension. | 40 Degrees | |
| • Active Flexion | 40 Degrees | |
| • Active Rotation Left | 65 Degrees | |
| • Active Rotation Right | 65 Degrees | |
| • Active Side Bend Left | 35 Degrees | |
| • Active Side Bend Right | 30 Degrees | |

# Treatments

| | |
|---|---|
| **Exercise Activities: Aerobic Conditioning:** | |
| • Airgometer (Airdyne) | Time Elapsed: 10 Minutes, Additional Detail: UB, Charge As: Therapeutic Activities, Billing Code: 97530. |
| **Exercise Activities: Isometrics:** | |
| • Isometric Activity 1 | Time Elapsed: 8 Minutes, Repetitions: 10, Side: Bilateral, Description: cervical each way, Charge As: Therapeutic Exercise, Billing Code: 97110. |
| **Exercise Activities: Flexibility(U. Quarter):** | |
| • Cervicothoracic Musculature | Time Elapsed: 4 Minutes, Repetitions: 3 each ways, Body Position: Seated, Hold.: 15 Seconds, Additional Detail: UTM,lev scap,bicep/pec,upper thoracic, Charge As: Therapeutic Exercise, Billing Code: 97110. |
| **Exercise Activities: Isotonics(U. Quarter):** | |
| • Prone Horizontal Abduction/ER. | Time Elapsed: 2 Minutes, Repetitions: 10, Sets: 1, Charge As: Therapeutic Exercise, Billing Code: 97110. |
| Shoulder Shrugs | Time Elapsed: 2 Minutes, Weight - Pounds: 2 Pounds, Repetitions: 10, Sets: 2, Charge As: Therapeutic Exercise, Billing Code: 97110. |
| • Isotonic Activity 1 | Time Elapsed: 3 Minutes, Repetitions: 10, Sets: 1, Side: Bilateral, Description: AROM each way, Charge As: Therapeutic Exercise, Billing Code: 97110. |
| **Exercise Activities: Tubing/Bands(U. Quarter):** | |
| • Rows | Time Elapsed: 3 Minutes, Repetitions: 10, Sets: 3, Tubing/Band Color: Yellow, Resistance: Concentric/Eccentric, Additional Detail: standing, Charge As: Therapeutic Exercise, Billing Code: 97110. |
| • Tubing/Bands 1 | Time Elapsed: 6 Minutes, Repetitions: 10, Sets: 3, Tubing/Band Color: Yellow, Resistance: Concentric/Eccentric, Additional Detail: standing bilateral hor abd and ER, Description: stabilization, Charge As: Therapeutic Exercise, Billing Code: 97110. |
| **Exercise Activities: Dynamic Training: C-K-C Activity ( U. Quarter):** | |
| • Push-Ups | Time Elapsed: 3 Minutes, Repetitions: 10, Sets: 2, Position: Into Wall, Charge As: Therapeutic Exercise, Billing Code: 97110. |
| **Exercise Activities: Stabilization Training: Supine Position:** | |
| • Isometric Cervical Retraction | Time Elapsed: 2 Minutes, Repetitions: 10, Hold.: 10 sec Seconds, Additional Detail: supine nod, Charge As: Therapeutic Exercise, Billing Code: 97110. |
| **Manual Interventions: Upper Quarter Soft Tissue:** | |
| • Cervicothoracic PVM | Time Elapsed: 12 Minutes, Tx Depth: Moderate, Side: Bilateral, Technique: Strumming, Direction: Multidirectional, Assisting Technique: Tissue Elongation, Additional Detail: soft tissue mob, Charge As: Manual Therapy Techniques, Billing Code: 97140. |
| **Modalities:** | |

- Electric Stim, Unattended

Time Elapsed: 15 Minutes, Location: cervical, Performed With: Moist Heat, Mode: Continuous, Type: Interferential, Clinical Use: Post Activity, Charge As: E-Stim, Unattended, Billing Code: 97014.

- Ultrasound

Time Elapsed: 10 Minutes, Location: Superior, Watts/cm2: 1.50, Charge As: Ultrasound, Billing Code: 97035.

**Documented Procedural Code Summary:**

| Description | Code | Units | Minutes |
|---|---|---|---|
| • Electrical Stimulation (unattended) | 97014 | 1 | n/a |
| • Manual Therapy Techniques | 97140 | 1 | 12 |
| • Therapeutic Activities | 97530 | 1 | 10 |
| • Therapeutic Procedure | 97110 | 3 | 33 |
| • Ultrasound | 97035 | 1 | 10 |

**Timed Code Total Time:**

- 65 Minutes

## Assessment

**Pt noted w/ tenderness in medial border of R scapula. Improved pain symptoms at end of session slightly.**

## Plan

**Recommendations:**

- Discharge next session as per MD orders

Electronically authenticated.

Leah Hamoy, DPT(SC Lic: 2655)
Signed on Oct 03, 2012 15:16:44

DYNAMIC PHYSICAL THERAP.
OF FLORENCE

2724 W. Palmetto Street, Suite 2
Florence, SC USA 29526
Phone: (843) 292-1900 Fax: (843) 292-1902

| | | | |
|---|---|---|---|
| Patient: | Victor Benjamin | Visit Date: | Oct 09, 2012 |
| Acct #: | | Phys Phone: | (843) 234-1710 |
| DOB: | | SSN: | |
| Physician: | George Sandoz | Inj. Date: | Jun 15, 2011 |
| Phys Fax: | (843) 692-2145 | Surg. Date: | |
| Physician: | Not Specified | Visits: | 7 |
| Clinician: | Leah Hamoy | Cxl/Ns: | 0 |
| FSC: | Workers Compensation | Employer: | |
| Case Mgr: | | Insured: | |
| Payor: | | | |
| Pol/Claim#: | | | |

# Daily Note

## Diagnoses Spine

| | |
|---|---|
| 72291 | DISC DIS NEC/NOS-CERV |
| 7231 | CERVICALGIA |
| 7234 | BRACHIAL NEURITIS NOS |
| 72887 | MUSCLE WEAKNESS-GENERAL |

## General Information

**History of Injury:**

- Pt states that a piece of guard rail from 25 ft high feel on his head and R forearm causing tendons to be torn. Pt underwent surgery but never regained full function back. Pt states he can't make a fist yet but was released from therapy for the R hand. Pt is unable to perform any of the chores that he used to do before and hasn't tried to since the heat bothers him. He has pinched nerves in the neck causing numbness and tingling down RUE. Pt states he is able to perform BADLS by himself, but did need help from his wife until September last year. Pt had severe pain in lateral side of LLE which the doctor told him was coming from the neck and also informed him that he would be in pain the rest of his life. Neck hurts on the R side but more comfortable turning the head to R, hurts more to the L. Pt is taking seizure medication which has diminished his seizures. Pt also has balance problems which has caused falls in the past.

**Occupation:**

- Employer: Rexam Job Title: forklift operator, required to do heavy lifting

**Patient / Concerns / Goals:**

- get better, feel less pain

**Summary List: Current Medication: Prescription:**

- Medication 1: valium Medication 2: xanax

## Subjective Examination

**ADL / Functional Status:**

- ADL's: awaken frequently at noc even medications, 2-3 hrs at the most, gets nightmares, sit 2 hrs at the most, stand w/ good tolerance

**Chief Complaint:**

- Pain: Severity at Worst: 8/10.

**Daily Comments:**

- Current pain 6/10, worst pain within the past week 8-9/10 in the neck, but also c/o LBP for no apparent reason.

**Questionnaires:**

- NDI 68%

## Objective Examination

| Muscle Testing: Cervical Planes: | Left | Right |
|---|---|---|
| • Extension | 5/5 | |
| • Flexion | 5/5 | |
| • Rotation | 5/5 | 5/5 |
| • Side Bending | 5/5 | 5/5 |

| Muscle Testing: Upper Extremity MMT: | Left | Right |
|---|---|---|
| • Shoulder Abduction | -5/5 | +4/5 |
| • Shoulder Flexion | -5/5 | +4/5 |
| • Shoulder External Rotation | +4/5 | +4/5 |
| • Shoulder Internal Rotation | -5/5 | +4/5 |

| Muscle Testing: Grip/Pinch: Five Position Grip Test: Grip Dynamometer III: | Left | Right |
|---|---|---|
| • Gross Assessment | 45 | 35 |
| **Range of Motion: Spine: Cervical Degrees:** | | |
| • Active Extension. | 45 Degrees | |
| • Active Flexion | 30 Degrees | |
| • Active Rotation Left | 55 Degrees | |
| • Active Rotation Right | 50 Degrees | |
| • Active Side Bend Left | 25 Degrees | |
| • Active Side Bend Right | 25 Degrees | |

# Treatments

**Exercise Activities: Aerobic Conditioning:**
• Airgometer (Airdyne)

Time Elapsed: 10 Minutes, Additional Detail: UE, Charge As: Therapeutic Activities, Billing Code: 97530.

**Exercise Activities: Isometrics:**
• Isometric Activity 1

Time Elapsed: 8 Minutes, Repetitions: 10, Side: Bilateral, Description: cervical each way, Charge As: Therapeutic Exercise, Billing Code: 97110.

**Exercise Activities: Flexibility(U. Quarter):**
• Cervicothoracic Musculature

Time Elapsed: 4 Minutes, Repetitions: 3 each ways, Body Position: Seated, Hold.: 15 Seconds, Additional Detail: UTM,lev scap,bicep/pec,upper thoracic, Charge As: Therapeutic Exercise, Billing Code: 97110.

**Exercise Activities: Isotonics(U. Quarter):**
• Prone Horizontal Abduction/ER.

Time Elapsed: 2 Minutes, Repetitions: 10, Sets: 1, Charge As: Therapeutic Exercise, Billing Code: 97110.

• Shoulder Shrugs

Time Elapsed: 2 Minutes, Weight - Pounds: 2 Pounds, Repetitions: 10, Sets: 2, Charge As: Therapeutic Exercise, Billing Code: 97110.

• Isotonic Activity 1

Time Elapsed: 3 Minutes, Repetitions: 10, Sets: 1, Side: Bilateral, Description: AROM each way, Charge As: Therapeutic Exercise, Billing Code: 97110.

**Exercise Activities: Tubing/Bands(U. Quarter):**
• Rows

Time Elapsed: 3 Minutes, Repetitions: 10, Sets: 3, Tubing/Band Color: Yellow, Resistance: Concentric/Eccentric, Additional Detail: standing, Charge As: Therapeutic Exercise, Billing Code: 97110.

• Tubing/Bands 1

Time Elapsed: 6 Minutes, Repetitions: 10, Sets: 3, Tubing/Band Color: Yellow, Resistance: Concentric/Eccentric, Additional Detail: standing bilateral hor abd and ER, Description: stabilization, Charge As: Therapeutic Exercise, Billing Code: 97110.

**Exercise Activities: Dynamic Training: C-K-C Activity ( U. Quarter):**
• Push-Ups

Time Elapsed: 3 Minutes, Repetitions: 10, Sets: 2, Position: Into Wall, Charge As: Therapeutic Exercise, Billing Code: 97110.

**Exercise Activities: Stabilization Training: Supine Position:**
• Isometric Cervical Retraction

Time Elapsed: 2 Minutes, Repetitions: 10, Hold.: 10 sec Seconds, Additional Detail: supine nod, Charge As: Therapeutic Exercise, Billing Code: 97110.

**Manual Interventions: Upper Quarter Soft Tissue:**
• Cervicothoracic PVM

Time Elapsed: 12 Minutes, Tx Depth: Moderate, Side: Bilateral, Technique: Strumming, Direction: Multidirectional, Assisting Technique: Tissue Elongation, Additional Detail: soft tissue mob, Charge As: Manual Therapy Techniques, Billing Code: 97140.

**Modalities:**

- Electric Stim, Unattended

Time Elapsed: 15 Minutes, Location: cervical, Performed With: Moist Heat, Mode: Continuous, Type: Interferential, Clinical Use: Post Activity, Charge As: E-Stim, Unattended, Billing Code: 97014.

- Ultrasound

Time Elapsed: 10 Minutes, Location: Superior, Watts/cm2: 1.50, Charge As: Ultrasound, Billing Code: 97035.

**Documented Procedural Code Summary:**

| Description | Code | Units | Minutes |
|---|---|---|---|
| • Electrical Stimulation (unattended) | 97014 | 1 | n/a |
| • Manual Therapy Techniques | 97140 | 1 | 12 |
| • Therapeutic Activities | 97530 | 1 | 10 |
| • Therapeutic Procedure | 97110 | 3 | 33 |
| • Ultrasound | 97035 | 1 | 10 |

**Timed Code Total Time:**
- 65 Minutes

## Assessment

**Presentation:**
- Pt has not made progress w/ pain symptoms which continues to fluctuate but still at severe levels at its worst. Pt has made some progress UE and cervical strength, but cervical ROM today decreased from last assessment.

## Plan

**Recommendations:**
- Discharge to Home Exercise Program.

**Refer Client to:**
- Physician for Re-Check. Physician for Evaluation.

electronically authenticated.

Leah Hamoy, DPT(SC Lic: 2655)
Signed on Oct 09, 2012 13:33:27

DYNAMIC PHYSICAL THERAP.
OF FLORENCE

2724 W. Palmetto Street, Suite 2
Florence, SC USA 29526
Phone: (843) 292-1900 Fax: (843) 292-1902

| | | | |
|---|---|---|---|
| Patient: | Victor Benjamin | Acct: | 1024 |
| Physician: | George Sandoz | Note Date: | Oct 09. 2012 |
| Phy Phone: | (843) 234-1710 | DOB: | |
| Phy Fax: | (843) 692-2145 | SSN: | |
| Clinician: | Leah Hamoy | FSC: | Workers Compensation |
| Case Mgr: | | Payor: | |
| Inj. Date: | Jun 15, 2011 | Pol/Claim#: | |
| Surg. Date: | | Name of Insured: | |
| Visits: | 7 | Employer: | |
| Cxl/Ns: | 0 | | |

# Discharge Summary

## Diagnoses

Spine

| | |
|---|---|
| 72291 | DISC DIS NEC/NOS-CERV |
| 7231 | CERVICALGIA |
| 7234 | BRACHIAL NEURITIS NOS |
| 72887 | MUSCLE WEAKNESS-GENERAL |

## General Information

**History of Injury:**

- Pt states that a piece of guard rail from 25 ft high feel on his head and R forearm causing tendons to be torn. Pt underwent surgery but never regained full function back. Pt states he can't make a fist yet but was released from therapy for the R hand. Pt is unable to perform any of the chores that he used to do before and hasn't tried to since the heat bothers him. He has pinched nerves in the neck causing numbness and tingling down RUE. Pt states he is able to perform BADLS by himself, but did need help from his wife until September last year. Pt had severe pain in lateral side of LLE which the doctor told him was coming from the neck and also informed him that he would be in pain the rest of his life. Neck hurts on the R side but more comfortable turning the head to R, hurts more to the L. Pt is taking seizure medication which has diminished his seizures. Pt also has balance problems which has caused falls in the past.

**Occupation:**

Employer: Rexam Job Title: forklift operator, required to do heavy lifting

**tient / Concerns / Goals:**

- get better, feel less pain

**Summary List: Current Medication: Prescription:**

- Medication 1: valium Medication 2: xanax

## Subjective Examination

**ADL / Functional Status:**

- ADL's: awaken frequently at noc even medications, 2-3 hrs at the most, gets nightmares, sit 2 hrs at the most, stand w/ good tolerance Current status: Work status: Unable to work secondary to dysfunction.

**Chief Complaint:**

- Pain: Severity at Worst: 8/10.

**Questionnaires:**

- NDI 68%

## Objective Examination

| Muscle Testing: Cervical Planes: | Sep 18, 2012 Left | Sep 18, 2012 Right | Oct 09, 2012 Left | Oct 09, 2012 Right |
|---|---|---|---|---|
| • Extension | 4/5 | | 5/5 | |
| • Flexion | 3/5 | | 5/5 | |
| • Rotation | 4/5 | 4/5 | 5/5 | 5/5 |
| • Side Bending | +4/5 | +4/5 | 5/5 | 5/5 |

| Muscle Testing: Upper Extremity MMT: | Sep 18, 2012 Left | Sep 18, 2012 Right | Oct 09, 2012 Left | Oct 09, 2012 Right |
|---|---|---|---|---|
| • Shoulder Abduction | | +3/5 | -5/5 | +4/5 |
| • Shoulder Flexion | 4/5 | +3/5 | -5/5 | +4/5 |
| Shoulder External Rotation | +4/5 | +4/5 | +4/5 | +4/5 |
| houlder Internal Rotation | +4/5 | +4/5 | -5/5 | +4/5 |

| Muscle Testing: Grip/Pinch: Five Position Grip Test: Grip Dynamometer III: | Left | Right |
|---|---|---|
| • Gross Assessment | 45 | 35 |
| **Range of Motion: Spine: Cervical Degrees:** | Sep 18, 2012 | Oct 09, 2012 |
| • Active Extension. | 60 Degrees | 45 Degrees |
| • Active Flexion | 30 Degrees | 30 Degrees |
| • Active Rotation Left | 60 Degrees | 55 Degrees |
| • Active Rotation Right | 60 Degrees | 50 Degrees |
| • Active Side Bend Left | 30 Degrees | 25 Degrees |
| • Active Side Bend Right | 25 Degrees | 25 Degrees |

## Assessment

**In my professional opinion, this client exhibits a good prognosis at time of discharge from skilled rehabilitative therapy in conjunction with a home exercise program. The client was educated regarding the discharge prognosis and related pathology. The client exhibits good understanding and is independent in their home exercise program and instructions outlined in this skilled rehabilitation program.**

**Presentation:**

- Pt has not made progress w/ pain symptoms which continues to fluctuate but still at severe levels at its worst. Pt has made some progress UE and cervical strength, but cervical ROM today decreased from last assessment.

## Problems & Goals

*Problem #1* **Chief Complaint: Pain: Severity at Worst: 8/10.**

*Goal Abandoned Oct 09, 2012. as per script*

**Symptomatic Improvements:**

- Decreasing Pain: Decrease worst pain to 3/10 to sleep 4 hrs undisturbed

*Problem #2* **Questionnaires: NDI 68%**

*Goal Abandoned Oct 09, 2012. as per script*

**Functional Improvements In:**

- Functional Independence/Assessment Measure: Decrease NDI to 50% to show inc functional activity tolerance

*Problem #3* **Muscle Testing: Upper Extremity MMT.**

*Goal Achieved Oct 09, 2012.*

| Musculoskeletal Improvements In: Upper Extremity Strength to: | Right |
|---|---|
| • Gross Assessment | +4/5 |

## Plan

**Recommendations:**

- Discharge to Home Exercise Program.

**Refer Client to:**

- Physician for Re-Check. Physician for Evaluation.

Electronically authenticated on 10/9/2012 13:36:08

Leah Hamoy, DPT(SC Lic: 2655)

DYNAMIC PHYSICAL THERAP
OF FLORENCE

2724 W. Palmetto Street, Suite 2
Florence, SC USA 29526
Phone: (843) 292-1900 Fax: (843) 292-1902

Patient: Victor Benjamin
Acct #:
DOB:
Physician: Karl Lozanne
Phys Fax: (803) 794-0322
Physician: Not Specified
Clinician: Leah Hamoy
FSC: Workers Compensation
Case Mgr:
Payor:
Pol/Claim#:

Visit Date: Mar 25, 2013
Phys Phone: (803) 794-3700
SSN:
Inj. Date:
Surg. Date:
Visits: 1
Cxl/Ns: 0
Employer:
Insured:

# Initial Evaluation

## Diagnoses Spine

| | |
|---|---|
| 7231 | CERVICALGIA |
| 7197 | DIFFICULTY IN WALKING |
| 7234 | BRACHIAL NEURITIS NOS |
| 71959 | JT STIFFNESS NEC-MULT JT |

## General Information

**Surgery:**
- Pt underwent cervical fusion on 2-18-13 at C4-/5, 5/6, 6/7.

## Subjective Examination

**The patient's medical history has been verbally reviewed with the patient by the evaluating therapist. The medical history questionnaire has been completed and signed by the patient, reviewed by the evaluating therapist, and is on file. The patient has read and signed the Patient Rights and Consent for Treatment forms, they have been reviewed by the evaluating therapist, and are on file.**

**ADL / Functional Status: Current Status: Basic care:**
uses shower chair Independent With Difficulty. Independent With Increased Time.

**ADL / Functional Status: ADL's: Activities:**

| | |
|---|---|
| • Driving/Traveling | 1 hr, slow |
| • Heavy Housework | Unable to perform |
| • Light Housework | Unable to perform |
| • Meal Preparation | heat up food in microwave |
| • Sitting: | To 51-60 minutes |
| • Sleeping. | 3-5 hrs |
| • Standing. | To 5-10 minutes |
| • Walking. | < 5 min |

**ADL / Functional Status:**
- Premorbid Status:
  - Basic care: Independent With Increased Time. Work status: Unable to work secondary to dysfunction.
- Current Status: Work status: Unable to work secondary to dysfunction.

**Chief Complaint: Pain:**
- Current Severity: 7/10. Severity at Best: 6/10. Severity at Worst: 10/10. Aggravating Factors: could be anything, sometimes swallowing

**Daily Comments:**
- Pt states that both his hands are cold, and having balance problems and has to use cane.

**Extremity Dominance:**
- Left.

**Mechanism of Injury:**
- surgery

**Questionnaires: Disability Index:**

| | |
|---|---|
| • Test Name | Oswestry Disability Index |
| • Percentage | 88.00% |

**Rehabilitation Expectations/Goals: Minimize:**
Pain. Numbness/Tingling.

# Objective Examination

**Functional Tests: Balance:**

| | |
|---|---|
| • Left Leg, Eyes Open, Firm | 5 seconds |
| • Right Leg, Eyes Open, Firm | 4 seconds |

**Muscle Testing: Grip/Pinch: Five Position Grip Test: Grip Dynamometer III:**

| | Left | Right |
|---|---|---|
| • Gross Assessment | 40 lbs | 20 |

**Muscle Testing: Upper Extremity MMT:**

| | Left | Right |
|---|---|---|
| • Gross Assessment | +4/5 | +3/5 |

**Muscle Testing: Lower Extremity MMT:**

| | Left | Right |
|---|---|---|
| • Gross Assessment | +3/5 | +3/5 |
| • Ankle Dorsiflexion | +4/5 | +4/5 |

**Observations:**

- External Devices: cervical collar
- Gross Movements:
  - Active Movements: Stiff. Protective Posturing: Guarding: Severe.

**Palpation: Cervical Region: Musculature, Posterior: Decreased**

**Mobility:**

| | Left | Right |
|---|---|---|
| • General Muscle Mass | Moderate | Moderate |

**Posture:**

- Laterally: Cervical Lordosis: Decreased.

**Range of Motion: Spine: Cervical Degrees:**

| | |
|---|---|
| • Active Extension. | 40 Degrees |
| • Active Flexion | 5 Degrees |
| • Active Rotation Left | 10 Degrees |
| • Active Rotation Right | 25 Degrees |
| • Active Side Bend Left | 10 Degrees |
| • Active Side Bend Right | 10 Degrees |

# Treatments

**Documented Procedural Code Summary:**

| Description | Code | Units | Minutes |
|---|---|---|---|
| • Electrical Stimulation (unattended) | 97014 | 1 | n/a |
| • Physical Therapy Evaluation | 97001 | 1 | n/a |
| • Ultrasound | 97035 | 1 | 8 |

**Modalities:**

- Electric Stim, Unattended — Time Elapsed: 15 Minutes, Location: cervical, Performed With: Moist Heat, Mode: Continuous, Type: Interferential, Clinical Use: Post Activity, Charge As: E-Stim, Unattended, Billing Code: 97014.
- Ultrasound — Time Elapsed: 8 Minutes, Location: cervical, Watts/cm2: 1.50, Method: Direct application, Waves: Continuous, Charge As: Ultrasound, Billing Code: 97035.

**Timed Code Total Time:**

- 8 Minutes

# Assessment

**In my professional opinion, this client requires skilled physical therapy in conjunction with a home exercise program to address the problems and achieve the goals outlined below. Overall rehabilitation potential is good. The patient and/or family were educated regarding their diagnosis, prognosis and related pathology. The client exhibits good understanding and performance of the therapeutic activity and instructions outlined in this skilled rehabilitation session.**

**Impairments Identified:**

Balance. Endurance. Flexibility. Joint Integrity/Mobility. Pain. Posture. Functional Activities. Range of Motion. Soft Tissue Mobility. Weakness. Work Capacity.

# Problems & Goals

*Problem #1* **Chief Complaint: Pain: Severity at Worst: 10/10.**

*STG Achieve by Apr 08, 2013.*

**Symptomatic Improvements:**

- Decreasing Pain: to 7/10.

*LTG Achieve by Apr 22, 2013.*

**Symptomatic Improvements:**

- Decreasing Pain: Decrease worst pain to 5/10 for ease w/ self care and chores

*Problem #2* **ADL / Functional Status: ADL's: Activities.**

*STG Achieve by Apr 08, 2013.*

**ADL Improvements In: Activities:**

- Light Housework To 5-10 minutes

*LTG Achieve by Apr 22, 2013.*

**ADL Improvements In: Activities:**

- Light Housework To 11-20 minutes

*Problem #3* **Range of Motion: Spine: Cervical Degrees.**

*STG Achieve by Apr 08, 2013.*

**Range of Motion Improvements to: Cervical:**

- Active Flexion — 10 Degrees
- Active Rotation Left — 15 Degrees

*LTG Achieve by Apr 22, 2013.*

**Range of Motion Improvements to: Cervical:**

- Active Flexion — 15 Degrees
- Active Rotation Left — 20 Degrees

*Problem #4* **Muscle Testing: Upper Extremity MMT.**

*STG Achieve by Apr 08, 2013.*

**Musculoskeletal Improvements In: Upper Extremity Strength to:** — Right

- Gross Assessment — 4/5

*LTG Achieve by Apr 22, 2013.*

**Musculoskeletal Improvements In: Upper Extremity Strength to:** — Right

- Gross Assessment — +4/5

*Problem #5* **Questionnaires: Disability Index.**

*LTG Achieve by Apr 22, 2013.*

**Questionnaire Improvements: Disability Index:**

- Test Name — Oswestry Disability Index
- Percentage — 78.00%

*Problem #6* **Palpation: Cervical Region: Musculature, Posterior: Decreased Mobility.**

*STG Achieve by Apr 08, 2013.*

**Palpable Improvements:**

- Soft Tissue Mobility/Pliability Improving to: Mild Restrictions.

*LTG Achieve by Apr 22, 2013.*

**Palpable Improvements:**

- Soft Tissue Mobility/Pliability Improving to: Slight Restrictions.

# Plan

**Amount, Frequency and Duration:**

- Frequency and Duration: It is recommended that the client attend rehabilitative therapy for 2 visits a week with an expected duration of 6 weeks. Interventions during the course of treatment will be directed toward addressing the problems and achieving the goals previously

outlined.

**Therapeutic Contents:**

- Client Education. Home Exercise Program. Manual Therapy Techniques. Soft Tissue Mobilization Techniques. Therapeutic Activities. Therapeutic Exercise. Stretching/Flexibility Activities.
- Modalities:
  - Cryotherapy. Ice Massage. Interferential Stimulation. Iontophoresis. Mechanical Traction. Moist Hot Pack. Ultrasound.

**Therapeutic Contents: Modalities: Iontophoresis: Medication:**

- Medication

Name: Dexamethazone, Dosage: 1.2-2.0cc@40-80mA/mi

Electronically authenticated.

Leah Hamoy, DPT(SC Lic: 2655)
Signed on Mar 26, 2013 14:06:16

DYNAMIC PHYSICAL THERAP.
OF FLORENCE

2724 W. Palmetto Street, Suite 2
Florence, SC USA 29526
Phone: (843) 292-1900 Fax: (843) 292-1902

Patient: Victor Benjamin
Acct #:
DOB:
Physician: Karl Lozanne
Phys Fax: (803) 794-0322
Physician: Not Specified
Clinician: Leah Hamoy
FSC: Workers Compensation
Case Mgr:
Payor:
Pol/Claim#:

Visit Date: Mar 25, 2013
Phys Phone: (803) 794-3700
SSN:
Inj. Date:
Surg. Date:
Visits: 1
Cxl/Ns: 0
Employer:
Insured:

# Plan of Care

## Diagnoses

Spine

| | |
|---|---|
| 7231 | CERVICALGIA |
| 7197 | DIFFICULTY IN WALKING |
| 7234 | BRACHIAL NEURITIS NOS |
| 71959 | JT STIFFNESS NEC-MULT JT |

## Assessment

**In my professional opinion, this client requires skilled physical therapy in conjunction with a home exercise program to address the problems and achieve the goals outlined below. Overall rehabilitation potential is good. The patient and/or family were educated regarding their diagnosis, prognosis and related pathology. The client exhibits good understanding and performance of the therapeutic activity and instructions outlined in this skilled rehabilitation session.**

**Impairments Identified:**

- Balance. Endurance. Flexibility. Joint Integrity/Mobility. Pain. Posture. Functional Activities. Range of Motion. Soft Tissue Mobility. Weakness. Work Capacity.

## Problems & Goals

*Problem #1* **Chief Complaint: Pain: Severity at Worst: 10/10.**

*STG Achieve by Apr 08, 2013.*

**Symptomatic Improvements:**

- Decreasing Pain: to 7/10.

*LTG Achieve by Apr 22, 2013.*

**Symptomatic Improvements:**

- Decreasing Pain: Decrease worst pain to 5/10 for ease w/ self care and chores

*Problem #2* **ADL / Functional Status: ADL's: Activities.**

| | |
|---|---|
| • Driving/Traveling | 1 hr, slow |
| • Heavy Housework | Unable to perform |
| • Light Housework | Unable to perform |
| • Meal Preparation | heat up food in microwave |
| • Sitting: | To 51-60 minutes |
| • Sleeping. | 3-5 hrs |
| • Standing. | To 5-10 minutes |
| • Walking. | < 5 min |

*STG Achieve by Apr 08, 2013.*

**ADL Improvements In: Activities:**

- Light Housework To 5-10 minutes

*LTG Achieve by Apr 22, 2013.*

**ADL Improvements In: Activities:**

- Light Housework To 11-20 minutes

*Problem #3* **Range of Motion: Spine: Cervical Degrees.**

| | |
|---|---|
| • Active Extension. | 40 Degrees |
| • Active Flexion | 5 Degrees |
| • Active Rotation Left | 10 Degrees |
| • Active Rotation Right | 25 Degrees |

- Active Side Bend Left — 10 Degrees
- Active Side Bend Right — 10 Degrees

*STG Achieve by Apr 08, 2013.*

**Range of Motion Improvements to: Cervical:**
- Active Flexion — 10 Degrees
- Active Rotation Left — 15 Degrees

*LTG Achieve by Apr 22, 2013.*

**Range of Motion Improvements to: Cervical:**
- Active Flexion — 15 Degrees
- Active Rotation Left — 20 Degrees

*Problem #4* **Muscle Testing: Upper Extremity MMT.**

| | Left | Right |
|---|---|---|
| • Gross Assessment | +4/5 | +3/5 |

*STG Achieve by Apr 08, 2013.*

**Musculoskeletal Improvements In: Upper Extremity Strength to:**

| | Right |
|---|---|
| • Gross Assessment | 4/5 |

*LTG Achieve by Apr 22, 2013.*

**Musculoskeletal Improvements In: Upper Extremity Strength to:**

| | Right |
|---|---|
| • Gross Assessment | +4/5 |

*Problem #5* **Questionnaires: Disability Index.**
- Percentage — 88.00%
- Test Name — Oswestry Disability Index

*LTG Achieve by Apr 22, 2013.*

**Questionnaire Improvements: Disability Index:**
- Test Name — Oswestry Disability Index
- Percentage — 78.00%

*Problem #6* **Palpation: Cervical Region: Musculature, Posterior: Decreased Mobility.**

| | Left | Right |
|---|---|---|
| • General Muscle Mass | Moderate | Moderate |

*STG Achieve by Apr 08, 2013.*

**Palpable Improvements:**
- Soft Tissue Mobility/Pliability Improving to: Mild Restrictions.

*LTG Achieve by Apr 22, 2013.*

**Palpable Improvements:**
- Soft Tissue Mobility/Pliability Improving to: Slight Restrictions.

## Plan

**Amount, Frequency and Duration:**
- Frequency and Duration: It is recommended that the client attend rehabilitative therapy for 2 visits a week with an expected duration of 6 weeks. Interventions during the course of treatment will be directed toward addressing the problems and achieving the goals previously outlined.

**Therapeutic Contents:**
- Client Education. Home Exercise Program. Manual Therapy Techniques. Soft Tissue Mobilization Techniques. Therapeutic Activities. Therapeutic Exercise. Stretching/Flexibility Activities.
- Modalities:
  - Cryotherapy. Ice Massage. Interferential Stimulation. Iontophoresis. Mechanical Traction. Moist Hot Pack. Ultrasound.

**Therapeutic Contents: Modalities: Iontophoresis: Medication:**
- Medication — Name: Dexamethazone, Dosage: 1.2-2.0cc@40-80mA/mi

Electronically authenticated.

Leah Hamoy, DPT(SC Lic: 2655)
Signed on Mar 26, 2013 14:06:16

## Please sign and return

I have reviewed this Plan of Care and certify that the skilled therapy services identified are required to meet the patient's need. Comments and/or revisions to this Plan of Care are noted below.

**Comments/Revisions**

| Physician/NPP Signature | Date | Print Name and Credentials |
|---|---|---|

DYNAMIC PHYSICAL THERAP
OF FLORENCE

2724 W. Palmetto Street, Suite 2
Florence, SC USA 29526
Phone: (843) 292-1900 Fax: (843) 292-1902

Patient: Victor Benjamin
Acct #:
DOB:
Physician: Karl Lozanne
Phys Fax: (803) 794-0322
Physician: Not Specified
Clinician: Leah Hamoy
FSC: Workers Compensation
Case Mgr:
Payor:
Pol/Claim#:

Visit Date: Mar 27, 2013
Phys Phone: (803) 794-3700
SSN:
Inj. Date:
Surg. Date:
Visits: 2
Cxl/Ns: 0
Employer:
Insured:

# Daily Note

## Diagnoses

Spine

| | |
|---|---|
| 7231 | CERVICALGIA |
| 7197 | DIFFICULTY IN WALKING |
| 7234 | BRACHIAL NEURITIS NOS |
| 71959 | JT STIFFNESS NEC-MULT JT |

## General Information

**Surgery:**

- Pt underwent cervical fusion on 2-18-13 at C4-/5, 5/6, 6/7.

## Subjective Examination

**ADL / Functional Status: ADL's: Activities:**

| | |
|---|---|
| • Driving/Traveling | 1 hr, slow |
| • Heavy Housework | Unable to perform |
| • Light Housework | Unable to perform |
| • Meal Preparation | heat up food in microwave |
| • Sitting: | To 51-60 minutes |
| Sleeping. | 3-5 hrs |
| • Standing. | To 5-10 minutes |
| • Walking. | < 5 min |

**ADL / Functional Status:**

- Current Status: Work status: Unable to work secondary to dysfunction.

**Chief Complaint:**

- Pain: Severity at Worst: 10/10.

**Daily Comments:**

- Pt reports 7/10 pain at start of treatment this morning. Pt reports that electrical stimulation made him feel kinda good. Pt reports 5/10 pain at end of treatment.

**Questionnaires: Disability Index:**

| | |
|---|---|
| • Test Name | Oswestry Disability Index |
| • Percentage | 88.00% |

## Objective Examination

**Functional Tests: Balance:**

| | |
|---|---|
| • Left Leg, Eyes Open, Firm | 5 seconds |
| • Right Leg, Eyes Open, Firm | 4 seconds |

**Muscle Testing: Grip/Pinch: Five Position Grip Test: Grip Dynamometer III:**

| | Left | Right |
|---|---|---|
| • Gross Assessment | 40 lbs | 20 |

**Muscle Testing: Upper Extremity MMT:**

| | Left | Right |
|---|---|---|
| • Gross Assessment | +4/5 | +3/5 |

**Muscle Testing: Lower Extremity MMT:**

| | Left | Right |
|---|---|---|
| • Gross Assessment | +3/5 | +3/5 |
| • Ankle Dorsiflexion | +4/5 | +4/5 |

**Observations:**

• Gross Movements: Protective Posturing: Guarding: Severe.
Palpation: Cervical Region: Musculature, Posterior: Decreased

| | Left | Right |
|---|---|---|
| **Mobility:** | | |
| • General Muscle Mass | Moderate | Moderate |
| **Posture:** | | |
| • Laterally: Cervical Lordosis: Decreased. | | |
| **Range of Motion: Spine: Cervical Degrees:** | | |
| • Active Extension. | 40 Degrees | |
| • Active Flexion | 5 Degrees | |
| • Active Rotation Left | 10 Degrees | |
| • Active Rotation Right | 25 Degrees | |
| • Active Side Bend Left | 10 Degrees | |
| • Active Side Bend Right | 10 Degrees | |

# Treatments

**Documented Procedural Code Summary:**

| Description | Code | Units | Minutes |
|---|---|---|---|
| • Electrical Stimulation (unattended) | 97014 | 1 | n/a |
| • Manual Therapy Techniques | 97140 | 1 | 12 |
| • Therapeutic Procedure | 97110 | 3 | 33 |

**Exercise Activities: Range of Motion:**

• ROM Activity 1

Time Elapsed: 4 Minutes, Repetitions: 10, Sets: 1, Technique: Active, Body Position: seated shoulders relaxed, Hold.: 5 Seconds, Description: Cervical all planes, Charge As: Therapeutic Exercise, Billing Code: 97110.

• ROM Activity 2

Time Elapsed: 4 Minutes, Repetitions: 5, Sets: 1, Side: Bilateral, Technique: Active, Body Position: standing back doral palm against wall, Hold.: 1 Seconds, Description: wall angels for scapular mozilization/stabilization, Charge As: Therapeutic Exercise, Billing Code: 97110.

**Exercise Activities: Isometrics:**

• Isometric Activity 1

Time Elapsed: 4 Minutes, Repetitions: 10, Sets: 1, Hold.: 2 Seconds, Additional Detail: supine with auto manual pain free resistance, Description: cervical, Charge As: Therapeutic Exercise, Billing Code: 97110.

**Exercise Activities: Aerobic Conditioning:**

• Airgometer (Airdyne)

Time Elapsed: 8 Minutes, Additional Detail: for aerobic conditioning., Charge As: Therapeutic Exercise, Billing Code: 97110.

**Exercise Activities: Tubing/Bands(U. Quarter):**

• Rows

Time Elapsed: 3 Minutes, Repetitions: 10, Sets: 1, Tubing/Band Color: Yellow, Hold.: 5 Seconds, Resistance: Concentric/Eccentric, Additional Detail: standing, Charge As: Therapeutic Exercise, Billing Code: 97110.

**Manual Interventions: Massage:**

• Massage 1

Time Elapsed: 12 Minutes, Tx Depth: Moderate, Location: cervical/thoracic, Direction: cervical/thoracic along superficial muscle fibers, Additional Detail: prone with ankle pillow/cervical pillows, Technique 1: Combination Approach, Charge As: Manual Therapy Techniques, Billing Code: 97140.

**Modalities:**

- Electric Stim, Unattended

Time Elapsed: 15 Minutes, Location: cervical, Performed With: Moist Heat, Mode: Continuous, Type: Interferential, Additional Detail: 24mA, Clinical Use: Post Activity, Charge As: E-Stim, Unattended, Billing Code: 97014.

**Pt./Family Education:**
- Functional Strategies

Time Elapsed: 8 Minutes, Activity 1: cervical roll for sleeping, Activity 2: diaphragmatic breathing for relaxation and deep breathing strategies, Charge As: Therapeutic Exercise, Billing Code: 97110.

- Written Home Exercise Program

Time Elapsed: 2 Minutes, Activity: Provided & Reviewed, Description: Diagnosis Specific, Charge As: Therapeutic Exercise, Billing Code: 97110.

**Timed Code Total Time:**
- 45 Minutes

## Assessment

**The client tolerated today's treatment/therapeutic activity with minimal complaints of pain and difficulty. Given patient's response after completing program activity, they exhibit good perception of appropriate self-exertion levels.**
**Pt with subjective complaint during wall angels in Left side of neck but progressed through there ex. Pt with noted trigger point near inferior Right scapula angle and Right middle scapula. At end of therapy session pt complained of beginning pain level of 7/10 in Left levator area, therapist instructed pt to avoid ROM to the right until next session or until pain subsides.**

**Client Behavior/Traits:**
- Self-exertion level: Pt paces well, listens and attempts there ex with one demonstration.

**Signs/Symptoms:**
- Stiffness: Unchanged.

## Plan

**Daily Plan:**
- Continue w/ Current Rehabilitation Program. check for HEP compliance with parallel there ex session.

Electronically authenticated.

patrick boltin, PTA(SC Lic: 2874)
Signed on Mar 27, 2013 12:23:13
Under the direct supervision of the primary therapist.

Electronically authenticated.

Leah Hamoy, DPT(SC Lic: 2655)
Signed on Mar 27, 2013 21:55:47

DYNAMIC PHYSICAL THERAP,
OF FLORENCE

2724 W. Palmetto Street, Suite 2
Florence, SC USA 29526
Phone: (843) 292-1900 Fax: (843) 292-1902

Patient: Victor Benjamin
Acct #:
DOB:
Physician: Karl Lozanne
Phys Fax: (803) 794-0322
Physician: Not Specified
Clinician: Leah Hamoy
FSC: Workers Compensation
Case Mgr:
Payor:
Pol/Claim#:

Visit Date: Apr 01, 2013
Phys Phone: (803) 794-3700
SSN:
Inj. Date:
Surg. Date:
Visits: 3
Cxl/Ns: 0
Employer:
Insured:

# Daily Note

## Diagnoses

Spine

| | |
|---|---|
| 7231 | CERVICALGIA |
| 7197 | DIFFICULTY IN WALKING |
| 7234 | BRACHIAL NEURITIS NOS |
| 71959 | JT STIFFNESS NEC-MULT JT |

## General Information

**Surgery:**

- Pt underwent cervical fusion on 2-18-13 at C4-/5, 5/6, 6/7.

## Subjective Examination

**ADL / Functional Status: ADL's: Activities:**

| | |
|---|---|
| • Driving/Traveling | 1 hr, slow |
| • Heavy Housework | Unable to perform |
| • Light Housework | Unable to perform |
| • Meal Preparation | heat up food in microwave |
| Sitting: | To 51-60 minutes |
| Sleeping. | 3-5 hrs |
| • Standing. | To 5-10 minutes |
| • Walking. | < 5 min |

**ADL / Functional Status:**

- Current Status: Work status: Unable to work secondary to dysfunction.

**Chief Complaint:**

- Pain: Severity at Worst: 10/10.

**Daily Comments:**

- Pt reports having a headache today. Pt reports 8/10 pain at start of treatment. Pt reports 7-8/10 pain in neck and still reports a headache with same pain level at end of treatment.

**Questionnaires: Disability Index:**

| | |
|---|---|
| • Test Name | Oswestry Disability Index |
| • Percentage | 88.00% |

## Objective Examination

**Functional Tests: Balance:**

| | |
|---|---|
| • Left Leg, Eyes Open, Firm | 5 seconds |
| • Right Leg, Eyes Open, Firm | 4 seconds |

**Muscle Testing: Grip/Pinch: Five Position Grip Test: Grip Dynamometer III:**

| | Left | Right |
|---|---|---|
| • Gross Assessment | 40 lbs | 20 |

**Muscle Testing: Upper Extremity MMT:**

| | Left | Right |
|---|---|---|
| • Gross Assessment | +4/5 | +3/5 |

**Muscle Testing: Lower Extremity MMT:**

| | Left | Right |
|---|---|---|
| • Gross Assessment | +3/5 | +3/5 |
| Ankle Dorsiflexion | +4/5 | +4/5 |

**Observations:**

• Gross Movements: Protective Posturing: Guarding: Severe.

| Palpation: Cervical Region: Musculature, Posterior: Decreased | Left | Right |
|---|---|---|
| **Mobility:** | | |
| • General Muscle Mass | Moderate | Moderate |
| **Posture:** | | |
| • Laterally: Cervical Lordosis: Decreased. | | |
| **Range of Motion: Spine: Cervical Degrees:** | | |
| • Active Extension. | 40 Degrees | |
| • Active Flexion | 5 Degrees | |
| • Active Rotation Left | 10 Degrees | |
| • Active Rotation Right | 25 Degrees | |
| • Active Side Bend Left | 10 Degrees | |
| • Active Side Bend Right | 10 Degrees | |

# Treatments

**Documented Procedural Code Summary:**

| Description | Code | Units | Minutes |
|---|---|---|---|
| • Electrical Stimulation (unattended) | 97014 | 1 | n/a |
| • Manual Therapy Techniques | 97140 | 1 | 10 |
| • Therapeutic Procedure | 97110 | 2 | 28 |

**Exercise Activities: Range of Motion:**

• ROM Activity 1

Time Elapsed: 4 Minutes, Repetitions: 10, Sets: 1, Technique: Active, Body Position: seated shoulders relaxed, Hold.: 5 Seconds, Description: Cervical all planes, Charge As: Therapeutic Exercise, Billing Code: 97110.

ROM Activity 2

Time Elapsed: 4 Minutes, Repetitions: 10, Sets: 1, Side: Bilateral, Technique: Active, Body Position: standing back doral palm against wall, Hold.: 1 Seconds, Description: wall angels for scapular mozilization/stabilization, Charge As: Therapeutic Exercise, Billing Code: 97110.

**Exercise Activities: Isometrics:**

• Isometric Activity 1

Time Elapsed: 4 Minutes, Repetitions: 10, Sets: 1, Hold.: 5 Seconds, Additional Detail: supine with auto manual pain free resistance, Description: cervical, Charge As: Therapeutic Exercise, Billing Code: 97110.

**Exercise Activities: Aerobic Conditioning:**

• Airgometer (Airdyne)

Time Elapsed: 8 Minutes, Additional Detail: for aerobic conditioning., Charge As: Therapeutic Exercise, Billing Code: 97110.

**Exercise Activities: Tubing/Bands(U. Quarter):**

• Rows

Time Elapsed: 3 Minutes, Repetitions: 10, Sets: 1, Tubing/Band Color: Yellow, Hold.: 5 Seconds, Resistance: Concentric/Eccentric, Additional Detail: standing, Charge As: Therapeutic Exercise, Billing Code: 97110.

**Manual Interventions: Massage:**

• Massage 1

Time Elapsed: 10 Minutes, Tx Depth: Moderate, Location: cervical/thoracic, Direction: cervical/thoracic along superficial muscle fibers, Additional Detail: prone with ankle pillow/cervical pillows, Technique 1: Combination Approach, Charge As: Manual Therapy Techniques, Billing Code: 97140.

**Modalities:**

- Electric Stim, Unattended

Time Elapsed: 15 Minutes, Location: cervical, Performed With: Cryotherapy, Mode: Continuous, Type: Interferential, Additional Detail: 28 mA, Clinical Use: Post Activity, Charge As: E-Stim, Unattended, Billing Code: 97014.
Did Not Perform: This visit

- Ultrasound(This visit)

**Pt./Family Education:**

- Patient Education 1

Time Elapsed: 5 Minutes, Additional Detail: went of strategies at home for pain free range of wall angles, verb cue on body positiong for HEP, Description: pt received YTB to begin rows with HEP and demonstration with home using door, Charge As: Therapeutic Exercise, Billing Code: 97110.

**Timed Code Total Time:**

- 38 Minutes

## Assessment

**The client tolerated today's treatment/therapeutic activity with minimal complaints of pain and difficulty. Given patient's response after completing program activity, they exhibit good perception of appropriate self-exertion levels.**

**Client Behavior/Traits:**

- Self-exertion level: Pt just needing verbal cue for hold on cervical Isometrics, and tactile cue for position of theraband for rows.

**Signs/Symptoms:**

- Spasm: tightness along left middle trapezius/rhomboid area and right upper trapezius area that both decreased after STM. Pt with trigger point along left middle trapezius area with STM.

**Tolerance: With Mild:**

- Pain. Pt still having pain with wall angles on right side, pt went to pain free range to avoid pain. Pt tolerated increase reps with wall angles, and rows today without being intolerable.

## Plan

**Recommendations:**

- Continue with current program. increase reps as tolerated.

Electronically authenticated.

patrick boltin, PTA(SC Lic: 2874)
Signed on Apr 01, 2013 12:24:11
Under the direct supervision of the primary therapist.

Electronically authenticated.

Leah Hamoy, DPT(SC Lic: 2655)
Signed on Apr 01, 2013 21:42:03

DYNAMIC PHYSICAL THERAP
OF FLORENCE

2724 W. Palmetto Street, Suite 2
Florence, SC USA 29526
Phone: (843) 292-1900 Fax: (843) 292-1902

Patient: Victor Benjamin
Acct #:
DOB:
Physician: Karl Lozanne
Phys Fax: (803) 794-0322
Physician: Not Specified
Clinician: Leah Hamoy
FSC: Workers Compensation
Case Mgr:
Payor:
Pol/Claim#:

Visit Date: Apr 03, 2013
Phys Phone: (803) 794-3700
SSN:
Inj. Date:
Surg. Date:
Visits: 4
Cxl/Ns: 0
Employer:
Insured:

# Daily Note

## Diagnoses Spine

| | |
|---|---|
| 7231 | CERVICALGIA |
| 7197 | DIFFICULTY IN WALKING |
| 7234 | BRACHIAL NEURITIS NOS |
| 71959 | JT STIFFNESS NEC-MULT JT |

## General Information

**Surgery:**
- Pt underwent cervical fusion on 2-18-13 at C4-/5, 5/6, 6/7.

## Subjective Examination

**ADL / Functional Status: ADL's: Activities:**

| | |
|---|---|
| • Driving/Traveling | 1 hr, slow |
| • Heavy Housework | Unable to perform |
| • Light Housework | Unable to perform |
| • Meal Preparation | heat up food in microwave |
| • Sitting: | To 51-60 minutes |
| Sleeping. | 3-5 hrs |
| • Standing. | To 5-10 minutes |
| • Walking. | < 5 min |

**ADL / Functional Status:**
- Current Status: Work status: Unable to work secondary to dysfunction.

**Chief Complaint:**
- Pain: Severity at Worst: 10/10.

**Daily Comments:**
- Pt reports 6/10 pain in neck today and reports most right side of neck. Pt reports that massage seems to relax him, but doesn't know if it's helping or not. Pt reports 5/10 at end of treatment.

**Questionnaires: Disability Index:**

| | |
|---|---|
| • Test Name | Oswestry Disability Index |
| • Percentage | 88.00% |

## Objective Examination

**Functional Tests: Balance:**

| | |
|---|---|
| • Left Leg, Eyes Open, Firm | 5 seconds |
| • Right Leg, Eyes Open, Firm | 4 seconds |

**Muscle Testing: Grip/Pinch: Five Position Grip Test: Grip Dynamometer III:**

| | Left | Right |
|---|---|---|
| • Gross Assessment | 40 lbs | 20 |

**Muscle Testing: Upper Extremity MMT:**

| | Left | Right |
|---|---|---|
| • Gross Assessment | +4/5 | +3/5 |

**Muscle Testing: Lower Extremity MMT:**

| | Left | Right |
|---|---|---|
| • Gross Assessment | +3/5 | +3/5 |
| • Ankle Dorsiflexion | +4/5 | +4/5 |

**Observations:**

- Gross Movements: Protective Posturing: Guarding: Severe.

**Palpation: Cervical Region: Musculature, Posterior: Decreased**

| | Left | Right |
|---|---|---|
| **Mobility:** | | |
| • General Muscle Mass | Moderate | Moderate |
| **Posture:** | | |
| • Laterally: Cervical Lordosis: Decreased. | | |
| **Range of Motion: Spine: Cervical Degrees:** | | |
| • Active Extension. | 40 Degrees | |
| • Active Flexion | 5 Degrees | |
| • Active Rotation Left | 10 Degrees | |
| • Active Rotation Right | 25 Degrees | |
| • Active Side Bend Left | 10 Degrees | |
| • Active Side Bend Right | 10 Degrees | |

# Treatments

**Documented Procedural Code Summary:**

| Description | Code | Units | Minutes |
|---|---|---|---|
| • Iontophoresis | 97033 | 1 | 15 |
| • Manual Therapy Techniques | 97140 | 1 | 10 |
| • Therapeutic Procedure | 97110 | 2 | 24 |
| • Ultrasound | 97035 | 1 | 8 |

**Exercise Activities: Range of Motion:**

• ROM Activity 1

Time Elapsed: 4 Minutes, Repetitions: 10, Sets: 1, Technique: Active, Body Position: seated shoulders relaxed, Hold.: 5 Seconds, Description: Cervical all planes, Charge As: Therapeutic Exercise, Billing Code: 97110.

ROM Activity 2

Time Elapsed: 4 Minutes, Repetitions: 10, Sets: 1, Side: Bilateral, Technique: Active, Body Position: standing back doral palm against wall, Hold.: 1 Seconds, Description: wall angels for scapular mozilization/stabilization, Charge As: Therapeutic Exercise, Billing Code: 97110.

**Exercise Activities: Isometrics:**

• Isometric Activity 1

Time Elapsed: 4 Minutes, Repetitions: 10, Sets: 1, Hold.: 5 Seconds, Additional Detail: supine with auto manual pain free resistance, Description: cervical, Charge As: Therapeutic Exercise, Billing Code: 97110.

**Exercise Activities: Aerobic Conditioning:**

• Airgometer (Airdyne)

Time Elapsed: 5 Minutes, Additional Detail: for aerobic conditioning., Charge As: Therapeutic Exercise, Billing Code: 97110.

**Exercise Activities: Tubing/Bands(U. Quarter):**

• Rows

Time Elapsed: 3 Minutes, Repetitions: 10, Sets: 1, Tubing/Band Color: Yellow, Hold.: 5 Seconds, Resistance: Concentric/Eccentric, Additional Detail: standing, Charge As: Therapeutic Exercise, Billing Code: 97110.

**Exercise Activities: Isotonics(U. Quarter):**

• Shoulder Shrugs

Time Elapsed: 4 Minutes, Weight - Pounds: 0 Pounds, Repetitions: 15, Sets: 1, Hold.: 5 sec Seconds, Additional Detail: seated, Charge As: Therapeutic Exercise, Billing Code: 97110.

**Exercise Activities: Flexibility(U. Quarter):**

**Manual Interventions: Massage:**

Massage 1

Time Elapsed: 10 Minutes, Tx Depth: Moderate, Location: cervical/thoracic, Direction: cervical/thoracic along superficial muscle fibers, Additional Detail: prone with ankle pillow/cervical pillows, Technique 1: Combination Approach, Charge As: Manual Therapy Techniques, Billing Code: 97140.

**Modalities:**

- Electric Stim, Unattended(This visit)
- Iontophoresis

Did Not Perform: This visit

Time Elapsed: 15 Minutes, Location: Right middle trapezius, Medication: Dexamethasone, Polarity: -, Pad Size: Medium, MA/Min: 40, Clinical Use: with detailed instructions and use, Charge As: Iontophoresis, Billing Code: 97033.

- Ultrasound

Time Elapsed: 8 Minutes, Location: cervical, Watts/cm2: 1.50, Method: Direct application, Waves: Continuous, MHz: 1, Additional Detail: right rhomboid and right levator, Pulse %: 100, Charge As: Ultrasound, Billing Code: 97035.

**Pt./Family Education:**

- Patient Education 1(This visit)

Did Not Perform: This visit

**Timed Code Total Time:**

- 57 Minutes

## Assessment

**The client tolerated today's treatment/therapeutic activity with minimal complaints of pain and difficulty.**

**Client Behavior/Traits:**

- Attendance: Pt arrived 20 minutes early. Pt demonstrates good pacing and positioning with therex and needs to cues.

**Tolerance: With Mild:**

- Pain. Pt reports increase in pain with stretching cervical sidebending to from 6/10 to 8/10 while doing flexion exercise. Pt with no pain with new shrug therex. Trigger points with right rhomboid/levator and spasm that decreased with STM and US. Pt reports latent trigger point with right middle trapezius.

## Plan

**Daily Plan:**

- Continue w/ Current Rehabilitation Program. Advance as tolerated. Added shrugs this visit, increase reps as tolerated. Add flexibility cervical stretch with 15 sec hold if pt can tolerate AROM therex with little pain. Check on Ionophoresis pain relief.

Electronically authenticated.

patrick boltin, PTA(SC Lic: 2874)
Signed on Apr 03, 2013 12:06:09
Under the direct supervision of the primary therapist.

Electronically authenticated.

Leah Hamoy, DPT(SC Lic: 2655)
Signed on Apr 03, 2013 13:33:07

DYNAMIC PHYSICAL THERAP
OF FLORENCE

2724 W. Palmetto Street, Suite 2
Florence, SC USA 29526
Phone: (843) 292-1900 Fax: (843) 292-1902

Patient: Victor Benjamin
Acct #:
DOB:
Physician: Karl Lozanne
Phys Fax: (803) 794-0322
Physician: Not Specified
Clinician: Leah Hamoy
FSC: Workers Compensation
Case Mgr:
Payor:
Pol/Claim#:

Visit Date: Apr 08, 2013
Phys Phone: (803) 794-3700
SSN:
Inj. Date: Jun 15, 2011
Surg. Date:
Visits: 5
Cxl/Ns: 0
Employer:
Insured:

# Daily Note

## Diagnoses Spine

| | |
|---|---|
| 7231 | CERVICALGIA |
| 7197 | DIFFICULTY IN WALKING |
| 7234 | BRACHIAL NEURITIS NOS |
| 71959 | JT STIFFNESS NEC-MULT JT |

## General Information

**Surgery:**
- Pt underwent cervical fusion on 2-18-13 at C4-/5, 5/6, 6/7.

## Subjective Examination

**ADL / Functional Status: ADL's: Activities:**

| | |
|---|---|
| • Driving/Traveling | 1 hr, slow |
| • Heavy Housework | Unable to perform |
| • Light Housework | Unable to perform |
| • Meal Preparation | heat up food in microwave |
| • Sitting: | To 51-60 minutes |
| • Sleeping. | 3-5 hrs |
| • Standing. | To 5-10 minutes |
| • Walking. | < 5 min |

**ADL / Functional Status:**
- Current Status: Work status: Unable to work secondary to dysfunction.

**Chief Complaint:**
- Pain: Severity at Worst: 10/10.

**Daily Comments:**
- Pt states 7/10 pain today but no headache.

**Questionnaires: Disability Index:**

| | |
|---|---|
| • Test Name | Oswestry Disability Index |
| • Percentage | 88.00% |

## Objective Examination

**Functional Tests: Balance:**

| | |
|---|---|
| • Left Leg, Eyes Open, Firm | 5 seconds |
| • Right Leg, Eyes Open, Firm | 4 seconds |

**Muscle Testing: Grip/Pinch: Five Position Grip Test: Grip Dynamometer III:**

| | Left | Right |
|---|---|---|
| • Gross Assessment | 40 lbs | 20 |

**Muscle Testing: Upper Extremity MMT:**

| | Left | Right |
|---|---|---|
| • Gross Assessment | +4/5 | +3/5 |

**Muscle Testing: Lower Extremity MMT:**

| | Left | Right |
|---|---|---|
| • Gross Assessment | +3/5 | +3/5 |
| • Ankle Dorsiflexion | +4/5 | +4/5 |

**Observations:**
- Gross Movements: Protective Posturing: Guarding: Severe.

**Palpation: Cervical Region: Musculature, Posterior: Decreased**

| | Left | Right |
|---|---|---|
| **Mobility:** | | |
| • General Muscle Mass | Moderate | Moderate |
| **Posture:** | | |
| • Laterally: Cervical Lordosis: Decreased. | | |
| **Range of Motion: Spine: Cervical Degrees:** | | |
| • Active Extension. | 40 Degrees | |
| • Active Flexion | 5 Degrees | |
| • Active Rotation Left | 10 Degrees | |
| • Active Rotation Right | 25 Degrees | |
| • Active Side Bend Left | 10 Degrees | |
| • Active Side Bend Right | 10 Degrees | |

# Treatments

**Documented Procedural Code Summary:**

| Description | Code | Units | Minutes |
|---|---|---|---|
| • Electrical Stimulation (unattended) | 97014 | 1 | n/a |
| • Iontophoresis | 97033 | 1 | 15 |
| • Manual Therapy Techniques | 97140 | 1 | 14 |
| • Therapeutic Procedure | 97110 | 2 | 29 |
| • Ultrasound | 97035 | 1 | 8 |

**Exercise Activities: Range of Motion:**

• ROM Activity 1

Time Elapsed: 4 Minutes, Repetitions: 10, Sets: 1, Technique: Active, Body Position: seated shoulders relaxed, Hold.: 5 Seconds, Description: Cervical all planes, Charge As: Therapeutic Exercise, Billing Code: 97110.

ROM Activity 2

Time Elapsed: 4 Minutes, Repetitions: 10, Sets: 1, Side: Bilateral, Technique: Active, Body Position: standing back doral palm against wall, Hold.: 1 Seconds, Description: wall angels for scapular mozilization/stabilization, Charge As: Therapeutic Exercise, Billing Code: 97110.

**Exercise Activities: Isometrics:**

• Isometric Activity 1

Time Elapsed: 4 Minutes, Repetitions: 10, Sets: 1, Hold.: 5 Seconds, Additional Detail: supine with auto manual pain free resistance, Description: cervical, Charge As: Therapeutic Exercise, Billing Code: 97110.

**Exercise Activities: Aerobic Conditioning:**

• Airgometer (Airdyne)

Time Elapsed: 10 Minutes, Additional Detail: for aerobic conditioning., Charge As: Therapeutic Exercise, Billing Code: 97110.

**Exercise Activities: Tubing/Bands(U. Quarter):**

• Rows

Time Elapsed: 3 Minutes, Repetitions: 10, Sets: 1, Tubing/Band Color: Yellow, Hold.: 5 Seconds, Resistance: Concentric/Eccentric, Additional Detail: standing, Charge As: Therapeutic Exercise, Billing Code: 97110.

**Exercise Activities: Isotonics(U. Quarter):**

• Shoulder Shrugs

Time Elapsed: 4 Minutes, Weight - Pounds: 0 Pounds, Repetitions: 15, Sets: 1, Hold.: 5 sec Seconds, Additional Detail: seated, Charge As: Therapeutic Exercise, Billing Code: 97110.

**Exercise Activities: Flexibility(U. Quarter):**

**Manual Interventions: Massage:**

- Massage 1

Time Elapsed: 14 Minutes, Tx Depth: Moderate, Location: cervical/thoracic, Direction: cervical/thoracic along superficial muscle fibers, Additional Detail: prone with ankle pillow/cervical pillows, Technique 1: Combination Approach, Technique 2: STM to SCM, Charge As: Manual Therapy Techniques, Billing Code: 97140.

**Modalities:**

- Electric Stim, Unattended

Time Elapsed: 15 Minutes, Location: cervical, Performed With: Cryotherapy, Mode: Continuous, Type: Interferential, Additional Detail: 28 mA, Clinical Use: Post Activity, Charge As: E-Stim, Unattended, Billing Code: 97014.

- Iontophoresis

Time Elapsed: 15 Minutes, Location: Right middle trapezius, Medication: Dexamethasone, Polarity: -, Pad Size: Medium, MA/Min: 40, Clinical Use: with detailed instructions and use, Charge As: Iontophoresis, Billing Code: 97033.

- Ultrasound

Time Elapsed: 8 Minutes, Location: L SCM belly, Watts/cm2: 1.50, Method: Direct application, Waves: Continuous, MHz: 1, Additional Detail: right rhomboid and right levator, Pulse %: 100, Charge As: Ultrasound, Billing Code: 97035.

**Pt./Family Education:**

- Patient Education 1(This visit)

Did Not Perform: This visit

**Timed Code Total Time:**

- 66 Minutes

## Assessment

**r tolerance to exercises, reporting feeling of fatigue in B shoulder muscles. Noted w/ Tenderness and swelling in L SCM muscle d restrictions in thoracic erector spinae and medial scapula muscles. Pt reported improved pain symptoms significantly at the end of session.**

## Plan

**Daily Plan:**

- Continue w/ Current Rehabilitation Program. Progression Under Current Plan.

Electronically authenticated.

Leah Hamoy, DPT(SC Lic: 2655)
Signed on Apr 08, 2013 12:26:32

- Gross Movements: Protective Posturing: Guarding: Severe.

**Palpation: Cervical Region: Musculature, Posterior: Decreased**

**Mobility:**

| | Left | Right |
|---|---|---|
| • General Muscle Mass | Moderate | Moderate |

**Posture:**

- Laterally: Cervical Lordosis: Decreased.

**Range of Motion: Spine: Cervical Degrees:**

| | |
|---|---|
| • Active Extension. | 40 Degrees |
| • Active Flexion | 5 Degrees |
| • Active Rotation Left | 10 Degrees |
| • Active Rotation Right | 25 Degrees |
| • Active Side Bend Left | 10 Degrees |
| • Active Side Bend Right | 10 Degrees |

# Treatments

**Documented Procedural Code Summary:**

| Description | Code | Units | Minutes |
|---|---|---|---|
| • Electrical Stimulation (unattended) | 97014 | 1 | n/a |
| • Manual Therapy Techniques | 97140 | 1 | 12 |
| • Therapeutic Procedure | 97110 | 2 | 29 |

**Exercise Activities: Range of Motion:**

- ROM Activity 1

Time Elapsed: 4 Minutes, Repetitions: 10, Sets: 1, Technique: Active, Body Position: seated shoulders relaxed, Hold.: 5 Seconds, Description: Cervical all planes, Charge As: Therapeutic Exercise, Billing Code: 97110.

ROM Activity 2

Time Elapsed: 4 Minutes, Repetitions: 10, Sets: 1, Side: Bilateral, Technique: Active, Body Position: standing back doral palm against wall, Hold.: 1 Seconds, Description: wall angels for scapular mozilization/stabilization, Charge As: Therapeutic Exercise, Billing Code: 97110.

**Exercise Activities: Isometrics:**

- Isometric Activity 1

Time Elapsed: 4 Minutes, Repetitions: 10, Sets: 1, Hold.: 5 Seconds, Additional Detail: supine with auto manual pain free resistance, Description: cervical, Charge As: Therapeutic Exercise, Billing Code: 97110.

**Exercise Activities: Aerobic Conditioning:**

- Airgometer (Airdyne)

Time Elapsed: 10 Minutes, Additional Detail: for aerobic conditioning., Charge As: Therapeutic Exercise, Billing Code: 97110.

**Exercise Activities: Tubing/Bands(U. Quarter):**

- Rows

Time Elapsed: 3 Minutes, Repetitions: 10, Sets: 1, Tubing/Band Color: Yellow, Hold.: 5 Seconds, Resistance: Concentric/Eccentric, Additional Detail: standing, Charge As: Therapeutic Exercise, Billing Code: 97110.

**Exercise Activities: Isotonics(U. Quarter):**

- Shoulder Shrugs

Time Elapsed: 4 Minutes, Weight - Pounds: 0 Pounds, Repetitions: 15, Sets: 1, Hold.: 5 sec Seconds, Additional Detail: seated, Charge As: Therapeutic Exercise, Billing Code: 97110.

**Exercise Activities: Flexibility(U. Quarter):**

**Manual Interventions: Upper Quarter Soft Tissue:**

- Cervicothoracic PVM

Time Elapsed: 12 Minutes, Technique: Strumming, Additional Detail: focus on posterior, Charge As: Manual Therapy Techniques, Billing Code: 97140.

**Modalities:**

DYNAMIC PHYSICAL THERAPY
OF FLORENCE

2724 W. Palmetto Street, Suite 2
Florence, SC USA 29526
Phone: (843) 292-1900 Fax: (843) 292-1902

Patient: Victor Benjamin
Acct #:
DOB:
Physician: Karl Lozanne
Phys Fax: (803) 794-0322
Physician: Not Specified
Clinician: Leah Hamoy
FSC: Workers Compensation
Case Mgr:
Payor:
Pol/Claim#:

Visit Date: Apr 10, 2013
Phys Phone: (803) 794-3700
SSN:
Inj. Date: Jun 15, 2011
Surg. Date:
Visits: 6
Cxl/Ns: 0
Employer:
Insured:

# Daily Note

## Diagnoses

Spine

| | |
|---|---|
| 7231 | CERVICALGIA |
| 7197 | DIFFICULTY IN WALKING |
| 7234 | BRACHIAL NEURITIS NOS |
| 71959 | JT STIFFNESS NEC-MULT JT |

## General Information

**Surgery:**
- Pt underwent cervical fusion on 2-18-13 at C4-/5, 5/6, 6/7.

## Subjective Examination

**ADL / Functional Status: ADL's: Activities:**

| | |
|---|---|
| • Driving/Traveling | 1 hr, slow |
| • Heavy Housework | Unable to perform |
| • Light Housework | Unable to perform |
| • Meal Preparation | heat up food in microwave |
| • Sitting: | To 51-60 minutes |
| Sleeping. | 3-5 hrs |
| • Standing. | To 5-10 minutes |
| • Walking. | < 5 min |

**ADL / Functional Status:**
- Current Status: Work status: Unable to work secondary to dysfunction.

**Chief Complaint:**
- Pain: Severity at Worst: 10/10.

**Daily Comments:**
- Pt states he couldn't sleep due to L wrist and hand pain which was also a result of the work injury. Pt states he's wearing the brace but neither that or pain medication seem to help. Pt states 6/10 pain in the neck and R scapular region.

**Questionnaires: Disability Index:**

| | |
|---|---|
| • Test Name | Oswestry Disability Index |
| • Percentage | 88.00% |

## Objective Examination

**Functional Tests: Balance:**

| | |
|---|---|
| • Left Leg, Eyes Open, Firm | 5 seconds |
| • Right Leg, Eyes Open, Firm | 4 seconds |

**Muscle Testing: Grip/Pinch: Five Position Grip Test: Grip Dynamometer III:**

| | Left | Right |
|---|---|---|
| • Gross Assessment | 40 lbs | 20 |

**Muscle Testing: Upper Extremity MMT:**

| | Left | Right |
|---|---|---|
| • Gross Assessment | +4/5 | +3/5 |

**Muscle Testing: Lower Extremity MMT:**

| | Left | Right |
|---|---|---|
| • Gross Assessment | +3/5 | +3/5 |
| Ankle Dorsiflexion | +4/5 | +4/5 |

**Observations:**

- Electric Stim, Unattended

Time Elapsed: 15 Minutes, Location: cervical, Performed With: Cryotherapy, Mode: Continuous, Type: Interferential, Additional Detail: 28 mA, Clinical Use: Post Activity, Charge As: E-Stim, Unattended, Billing Code: 97014.

- Iontophoresis(This visit)
- Ultrasound(This visit)

Did Not Perform: This visit
Did Not Perform: This visit

**Pt./Family Education:**

- Patient Education 1(This visit)

Did Not Perform: This visit

**Timed Code Total Time:**

- 41 Minutes

## Assessment

**The client tolerated today's treatment/therapeutic activity with moderate complaints of pain and difficulty.**

**Tolerance:**

- Decreased Complaints: of pain at the end of session after modality and manual therapy

## Plan

**Daily Plan:**

- Continue w/ Current Rehabilitation Program. Progression Under Current Plan.

Electronically authenticated.

Leah Hamoy, DPT(SC Lic: 2655)
Signed on Apr 11, 2013 13:36:16

DYNAMIC PHYSICAL THERAPY
OF FLORENCE

2724 W. Palmetto Street, Suite 2
Florence, SC USA 29526
Phone: (843) 292-1900 Fax: (843) 292-1902

Patient: Victor Benjamin
Acct #:
DOB:
Physician: Karl Lozanne
Phys Fax: (803) 794-0322
Physician: Not Specified
Clinician: Leah Hamoy
FSC: Workers Compensation
Case Mgr:
Payor:
Pol/Claim#:

Visit Date: Apr 15, 2013
Phys Phone: (803) 794-3700
SSN:
Inj. Date: Jun 15, 2011
Surg. Date:
Visits: 7
Cxl/Ns: 0
Employer:
Insured:

# Daily Note

## Diagnoses

Spine

| | |
|---|---|
| 7231 | CERVICALGIA |
| 7197 | DIFFICULTY IN WALKING |
| 7234 | BRACHIAL NEURITIS NOS |
| 71959 | JT STIFFNESS NEC-MULT JT |

## General Information

**Surgery:**
- Pt underwent cervical fusion on 2-18-13 at C4-/5, 5/6, 6/7.

## Subjective Examination

**ADL / Functional Status: ADL's: Activities:**

| | |
|---|---|
| • Driving/Traveling | 1 hr, slow |
| • Heavy Housework | Unable to perform |
| • Light Housework | Unable to perform |
| • Meal Preparation | heat up food in microwave |
| Sitting: | To 51-60 minutes |
| Sleeping. | 3-5 hrs |
| • Standing. | To 5-10 minutes |
| • Walking. | < 5 min |

**ADL / Functional Status:**
- Current Status: Work status: Unable to work secondary to dysfunction.

**Chief Complaint:**
- Pain: Severity at Worst: 10/10.

**Daily Comments:**
- PT states current pain is 7/10. Pt also reports he doesn't do anything else around except watch TV and sit on the swing.

**Questionnaires: Disability Index:**

| | |
|---|---|
| • Test Name | Oswestry Disability Index |
| • Percentage | 88.00% |

## Objective Examination

**Functional Tests: Balance:**

| | |
|---|---|
| • Left Leg, Eyes Open, Firm | 5 seconds |
| • Right Leg, Eyes Open, Firm | 4 seconds |

**Muscle Testing: Grip/Pinch: Five Position Grip Test: Grip Dynamometer III:**

| | Left | Right |
|---|---|---|
| • Gross Assessment | 40 lbs | 20 |

**Muscle Testing: Upper Extremity MMT:**

| | Left | Right |
|---|---|---|
| • Gross Assessment | +4/5 | +3/5 |

**Muscle Testing: Lower Extremity MMT:**

| | Left | Right |
|---|---|---|
| • Gross Assessment | +3/5 | +3/5 |
| • Ankle Dorsiflexion | +4/5 | +4/5 |

**Observations:**
- Gross Movements: Protective Posturing: Guarding: Severe.

| Palpation: Cervical Region: Musculature, Posterior: Decreased | Left | Right |
|---|---|---|
| **Mobility:** | | |
| • General Muscle Mass | Moderate | Moderate |

**Posture:**
- Laterally: Cervical Lordosis: Decreased.

**Range of Motion: Spine: Cervical Degrees:**

| | |
|---|---|
| • Active Extension. | 25 Degrees |
| • Active Flexion | 25 Degrees |
| • Active Rotation Left | 40 Degrees |
| • Active Rotation Right | 40 Degrees |
| • Active Side Bend Left | 20 Degrees |
| • Active Side Bend Right | 20 Degrees |

# Treatments

**Documented Procedural Code Summary:**

| Description | Code | Units | Minutes |
|---|---|---|---|
| • Electrical Stimulation (unattended) | 97014 | 1 | n/a |
| • Manual Therapy Techniques | 97140 | 1 | 12 |
| • Therapeutic Procedure | 97110 | 3 | 32 |

**Exercise Activities: Range of Motion:**

• ROM Activity 1

Time Elapsed: 4 Minutes, Repetitions: 10, Sets: 1, Technique: Active, Body Position: seated shoulders relaxed, Hold.: 5 Seconds, Description: Cervical all planes, Charge As: Therapeutic Exercise, Billing Code: 97110.

• ROM Activity 2

Time Elapsed: 4 Minutes, Repetitions: 10, Sets: 1, Side: Bilateral, Technique: Active, Body Position: standing back doral palm against wall, Hold.: 1 Seconds, Description: wall angels for scapular mozilization/stabilization, Charge As: Therapeutic Exercise, Billing Code: 97110.

**Exercise Activities: Isometrics:**

• Isometric Activity 1

Time Elapsed: 4 Minutes, Repetitions: 10, Sets: 1, Hold.: 5 Seconds, Additional Detail: supine with auto manual pain free resistance, Description: cervical, Charge As: Therapeutic Exercise, Billing Code: 97110.

**Exercise Activities: Aerobic Conditioning:**

• Airgometer (Airdyne)

Time Elapsed: 10 Minutes, Additional Detail: for aerobic conditioning., Charge As: Therapeutic Exercise, Billing Code: 97110.

**Exercise Activities: Tubing/Bands(U. Quarter):**

• Rows

Time Elapsed: 3 Minutes, Repetitions: 10, Sets: 1, Tubing/Band Color: Yellow, Hold.: 5 Seconds, Resistance: Concentric/Eccentric, Additional Detail: standing, Charge As: Therapeutic Exercise, Billing Code: 97110.

**Exercise Activities: Isotonics(U. Quarter):**

• Shoulder Shrugs

Time Elapsed: 4 Minutes, Weight - Pounds: 1 Pounds, Repetitions: 15, Sets: 1, Hold.: 5 sec Seconds, Additional Detail: seated, Charge As: Therapeutic Exercise, Billing Code: 97110.

**Exercise Activities: Flexibility(U. Quarter):**

**Exercise Activities: Dynamic Training: C-K-C Activity ( U. Quarter):**

• Push-Ups

Time Elapsed: 3 Minutes, Repetitions: 5, Sets: 2, Position: Into Wall, Charge As: Therapeutic Exercise, Billing Code: 97110.

**Manual Interventions: Upper Quarter Soft Tissue:**

- Cervicothoracic PVM

Time Elapsed: 12 Minutes, Technique: Strumming, Additional Detail: focus on posterior, Charge As: Manual Therapy Techniques, Billing Code: 97140.

**Modalities:**
- Electric Stim, Unattended

Time Elapsed: 15 Minutes, Location: cervical, Performed With: Cryotherapy, Mode: Continuous, Type: Interferential, Additional Detail: 28 mA, Clinical Use: Post Activity, Charge As: E-Stim, Unattended, Billing Code: 97014.

- Iontophoresis(This visit)
  Did Not Perform: This visit
- Ultrasound(This visit)
  Did Not Perform: This visit

**Pt./Family Education:**
- Patient Education 1(This visit)
  Did Not Perform: This visit

**Timed Code Total Time:**
- 44 Minutes

## Assessment

**The client tolerated today's treatment/therapeutic activity with mild complaints of pain and difficulty.**

**Tolerance:**
- Decreased Complaints: pain to 4/10 after manual therapy and modalities

## Plan

**Daily Plan:**
- Continue w/ Current Rehabilitation Program. Advance as tolerated.

Electronically authenticated.

Leah Hamoy, DPT(SC Lic: 2655)
Signed on Apr 15, 2013 19:26:53

DYNAMIC PHYSICAL THERAPY
OF FLORENCE

2724 W. Palmetto Street, Suite 2
Florence, SC USA 29526
Phone: (843) 292-1900 Fax: (843) 292-1902

Patient: Victor Benjamin
Acct #:
DOB:
Physician: Karl Lozanne
Phys Fax: (803) 794-0322
Physician: Not Specified
Clinician: Leah Hamoy
FSC: Workers Compensation
Case Mgr:
Payor:
Pol/Claim#:

Visit Date: Apr 17, 2013
Phys Phone: (803) 794-3700
SSN:
Inj. Date: Jun 15, 2011
Surg. Date:
Visits: 8
Cxl/Ns: 0
Employer:
Insured:

# Daily Note

## Diagnoses

Spine

| | |
|---|---|
| 7231 | CERVICALGIA |
| 7197 | DIFFICULTY IN WALKING |
| 7234 | BRACHIAL NEURITIS NOS |
| 71959 | JT STIFFNESS NEC-MULT JT |

## General Information

**Surgery:**
- Pt underwent cervical fusion on 2-18-13 at C4-/5, 5/6, 6/7.

## Subjective Examination

**ADL / Functional Status: ADL's: Activities:**

| | |
|---|---|
| • Driving/Traveling | 1 hr, slow |
| • Heavy Housework | Unable to perform |
| • Light Housework | Unable to perform |
| • Meal Preparation | heat up food in microwave |
| • Sitting: | To 51-60 minutes |
| Sleeping. | 3-5 hrs |
| • Standing. | To 5-10 minutes |
| • Walking. | < 5 min |

**ADL / Functional Status:**
- Current Status: Work status: Unable to work secondary to dysfunction.

**Chief Complaint:**
- Pain: Severity at Worst: 10/10.

**Daily Comments:**
- Pt reports having a bad day yesterday, better today but having a headache and 7/10 pain.

**Questionnaires: Disability Index:**

| | |
|---|---|
| • Test Name | Oswestry Disability Index |
| • Percentage | 88.00% |

## Objective Examination

**Functional Tests: Balance:**

| | |
|---|---|
| • Left Leg, Eyes Open, Firm | 5 seconds |
| • Right Leg, Eyes Open, Firm | 4 seconds |

**Muscle Testing: Grip/Pinch: Five Position Grip Test: Grip Dynamometer III:**

| | Left | Right |
|---|---|---|
| • Gross Assessment | 40 lbs | 20 |

**Muscle Testing: Upper Extremity MMT:**

| | Left | Right |
|---|---|---|
| • Gross Assessment | +4/5 | +3/5 |

**Muscle Testing: Lower Extremity MMT:**

| | Left | Right |
|---|---|---|
| • Gross Assessment | +3/5 | +3/5 |
| • Ankle Dorsiflexion | +4/5 | +4/5 |

**Observations:**
Gross Movements: Protective Posturing: Guarding: Severe.

**Palpation: Cervical Region: Musculature, Posterior: Decreased**

| | Left | Right |
|---|---|---|
| **Mobility:** | | |
| • General Muscle Mass | Moderate | Moderate |
| **Posture:** | | |
| • Laterally: Cervical Lordosis: Decreased. | | |
| **Range of Motion: Spine: Cervical Degrees:** | | |
| • Active Extension. | 25 Degrees | |
| • Active Flexion | 25 Degrees | |
| • Active Rotation Left | 40 Degrees | |
| • Active Rotation Right | 40 Degrees | |
| • Active Side Bend Left | 20 Degrees | |
| • Active Side Bend Right | 20 Degrees | |

# Treatments

**Documented Procedural Code Summary:**

| Description | Code | Units | Minutes |
|---|---|---|---|
| • Electrical Stimulation (unattended) | 97014 | 1 | n/a |
| • Manual Therapy Techniques | 97140 | 1 | 12 |
| • Therapeutic Procedure | 97110 | 3 | 32 |
| • Ultrasound | 97035 | 1 | 8 |

**Exercise Activities: Range of Motion:**

• ROM Activity 1

Time Elapsed: 4 Minutes, Repetitions: 10, Sets: 1, Technique: Active, Body Position: seated shoulders relaxed, Hold.: 5 Seconds, Description: Cervical all planes, Charge As: Therapeutic Exercise, Billing Code: 97110.

• ROM Activity 2

Time Elapsed: 4 Minutes, Repetitions: 10, Sets: 1, Side: Bilateral, Technique: Active, Body Position: standing back doral palm against wall, Hold.: 1 Seconds, Description: wall angels for scapular mozilization/stabilization, Charge As: Therapeutic Exercise, Billing Code: 97110.

**Exercise Activities: Isometrics:**

• Isometric Activity 1

Time Elapsed: 4 Minutes, Repetitions: 10, Sets: 1, Hold.: 5 Seconds, Additional Detail: supine with auto manual pain free resistance, Description: cervical, Charge As: Therapeutic Exercise, Billing Code: 97110.

**Exercise Activities: Aerobic Conditioning:**

• Airgometer (Airdyne)

Time Elapsed: 10 Minutes, Additional Detail: for aerobic conditioning., Charge As: Therapeutic Exercise, Billing Code: 97110.

**Exercise Activities: Tubing/Bands(U. Quarter):**

• Rows

Time Elapsed: 3 Minutes, Repetitions: 10, Sets: 1, Tubing/Band Color: Yellow, Hold.: 5 Seconds, Resistance: Concentric/Eccentric, Additional Detail: standing, Charge As: Therapeutic Exercise, Billing Code: 97110.

**Exercise Activities: Isotonics(U. Quarter):**

• Shoulder Shrugs

Time Elapsed: 4 Minutes, Weight - Pounds: 1 Pounds, Repetitions: 15, Sets: 1, Hold.: 5 sec Seconds, Additional Detail: seated, Charge As: Therapeutic Exercise, Billing Code: 97110.

**Exercise Activities: Flexibility(U. Quarter):**

**Exercise Activities: Dynamic Training: C-K-C Activity ( U. Quarter):**

• Push-Ups

Time Elapsed: 3 Minutes, Repetitions: 5, Sets: 2, Position: Into Wall, Charge As: Therapeutic Exercise, Billing Code: 97110.

**Manual Interventions: Upper Quarter Soft Tissue:**

- Cervicothoracic PVM

Time Elapsed: 12 Minutes, Technique: Strumming, Additional Detail: focus on posterior, Charge As: Manual Therapy Techniques, Billing Code: 97140.

**Modalities:**
- Electric Stim, Unattended

Time Elapsed: 15 Minutes, Location: cervical, Performed With: Cryotherapy, Mode: Continuous, Type: Interferential, Additional Detail: 28 mA, Clinical Use: Post Activity, Charge As: E-Stim, Unattended, Billing Code: 97014.

- Iontophoresis(This visit)
- Ultrasound

Did Not Perform: This visit

Time Elapsed: 8 Minutes, Location: R UTM, Watts/cm2: 1.50, Method: Direct application, Waves: Continuous, MHz: 1, Additional Detail: right rhomboid and right levator, Pulse %: 100, Charge As: Ultrasound, Billing Code: 97035.

Did Not Perform: This visit

**Pt./Family Education:**
- Patient Education 1(This visit)

**Timed Code Total Time:**
- 52 Minutes

## Assessment

**The client tolerated today's treatment/therapeutic activity with mild complaints of pain and difficulty.**

**Tolerance:**
- Decreased Complaints: of pain after manual therapy and modalities

## Plan

**Daily Plan:**
- Advance as tolerated. Progression Under Current Plan.

Electronically authenticated.

Leah Hamoy, DPT(SC Lic: 2655)
Signed on Apr 18, 2013 16:43:52

DYNAMIC PHYSICAL THERAPY
OF FLORENCE

2724 W. Palmetto Street, Suite 2
Florence, SC USA 29526
Phone: (843) 292-1900 Fax: (843) 292-1902

Patient: Victor Benjamin
Acct #:
DOB:
Physician: Karl Lozanne
Phys Fax: (803) 794-0322
Physician: Not Specified
Clinician: Leah Hamoy
FSC: Workers Compensation
Case Mgr:
Payor:
Pol/Claim#:

Visit Date: Apr 22, 2013
Phys Phone: (803) 794-3700
SSN:
Inj. Date: Jun 15, 2011
Surg. Date:
Visits: 9
Cxl/Ns: 0
Employer:
Insured:

# Daily Note

## Diagnoses

Spine

| | |
|---|---|
| 7231 | CERVICALGIA |
| 7197 | DIFFICULTY IN WALKING |
| 7234 | BRACHIAL NEURITIS NOS |
| 71959 | JT STIFFNESS NEC-MULT JT |

## General Information

**Surgery:**

- Pt underwent cervical fusion on 2-18-13 at C4-/5, 5/6, 6/7.

## Subjective Examination

**ADL / Functional Status: ADL's: Activities:**

| | |
|---|---|
| • Driving/Traveling | 1 hr, slow |
| • Heavy Housework | Unable to perform |
| • Light Housework | Unable to perform |
| • Meal Preparation | heat up food in microwave |
| Sitting: | To 51-60 minutes |
| Sleeping. | 3-5 hrs |
| • Standing. | To 5-10 minutes |
| • Walking. | < 5 min |

**ADL / Functional Status:**

- Current Status: Work status: Unable to work secondary to dysfunction.

**Chief Complaint:**

- Pain: Severity at Worst: 8/10.

**Daily Comments:**

- Pain increased over the weekend for some reason and had to take more medicine than usual.

**Questionnaires: Disability Index:**

| | |
|---|---|
| • Test Name | Oswestry Disability Index |
| • Percentage | 88.00% |

## Objective Examination

**Functional Tests: Balance:**

| | |
|---|---|
| • Left Leg, Eyes Open, Firm | 5 seconds |
| • Right Leg, Eyes Open, Firm | 4 seconds |

**Muscle Testing: Grip/Pinch: Five Position Grip Test: Grip Dynamometer III:**

| | Left | Right |
|---|---|---|
| • Gross Assessment | 40 lbs | 20 |

**Muscle Testing: Upper Extremity MMT:**

| | Left | Right |
|---|---|---|
| • Gross Assessment | +4/5 | +3/5 |

**Muscle Testing: Lower Extremity MMT:**

| | Left | Right |
|---|---|---|
| • Gross Assessment | +3/5 | +3/5 |
| • Ankle Dorsiflexion | +4/5 | +4/5 |

**Observations:**

Gross Movements: Protective Posturing: Guarding: Severe.

| Palpation: Cervical Region: Musculature, Posterior: Decreased Mobility: | Left | Right |
|---|---|---|
| • General Muscle Mass | Moderate | Moderate |

**Posture:**
- Laterally: Cervical Lordosis: Decreased.

**Range of Motion: Spine: Cervical Degrees:**

| | |
|---|---|
| • Active Extension. | 25 Degrees |
| • Active Flexion | 25 Degrees |
| • Active Rotation Left | 40 Degrees |
| • Active Rotation Right | 40 Degrees |
| • Active Side Bend Left | 20 Degrees |
| • Active Side Bend Right | 20 Degrees |

# Treatments

**Documented Procedural Code Summary:**

| Description | Code | Units | Minutes |
|---|---|---|---|
| • Electrical Stimulation (unattended) | 97014 | 1 | n/a |
| • Manual Therapy Techniques | 97140 | 1 | 12 |
| • Strapping - Thorax | 29200 | 1 | n/a |
| • Therapeutic Procedure | 97110 | 3 | 32 |
| • Ultrasound | 97035 | 2 | 20 |

**Exercise Activities: Range of Motion:**

• ROM Activity 1

Time Elapsed: 4 Minutes, Repetitions: 10, Sets: 1, Technique: Active, Body Position: seated shoulders relaxed, Hold.: 5 Seconds, Description: Cervical all planes, Charge As: Therapeutic Exercise, Billing Code: 97110.

• ROM Activity 2

Time Elapsed: 4 Minutes, Repetitions: 10, Sets: 1, Side: Bilateral, Technique: Active, Body Position: standing back doral palm against wall, Hold.: 1 Seconds, Description: wall angels for scapular mozilization/stabilization, Charge As: Therapeutic Exercise, Billing Code: 97110.

**Exercise Activities: Isometrics:**

• Isometric Activity 1

Time Elapsed: 4 Minutes, Repetitions: 10, Sets: 1, Hold.: 5 Seconds, Additional Detail: supine with auto manual pain free resistance, Description: cervical, Charge As: Therapeutic Exercise, Billing Code: 97110.

**Exercise Activities: Aerobic Conditioning:**

• Airgometer (Airdyne)

Time Elapsed: 10 Minutes, Additional Detail: for aerobic conditioning., Charge As: Therapeutic Exercise, Billing Code: 97110.

**Exercise Activities: Tubing/Bands(U. Quarter):**

• Rows

Time Elapsed: 3 Minutes, Repetitions: 10, Sets: 1, Tubing/Band Color: Yellow, Hold.: 5 Seconds, Resistance: Concentric/Eccentric, Additional Detail: standing, Charge As: Therapeutic Exercise, Billing Code: 97110.

**Exercise Activities: Isotonics(U. Quarter):**

• Shoulder Shrugs

Time Elapsed: 4 Minutes, Weight - Pounds: 1 Pounds, Repetitions: 15, Sets: 1, Hold.: 5 sec Seconds, Additional Detail: seated, Charge As: Therapeutic Exercise, Billing Code: 97110.

**Exercise Activities: Flexibility(U. Quarter):**

**Exercise Activities: Dynamic Training: C-K-C Activity ( U. Quarter):**

• Push-Ups

Time Elapsed: 3 Minutes, Repetitions: 5, Sets: 2, Position: Into Wall, Charge As: Therapeutic Exercise, Billing Code: 97110.

**Manual Interventions: Upper Quarter Soft Tissue:**

• Cervicothoracic PVM

Time Elapsed: 12 Minutes, Technique: Strumming, Additional Detail: focus on posterior, Charge As: Manual Therapy Techniques, Billing Code: 97140.

**Manual Interventions: Taping To Stabilize/Align:**
• Thorax Complex

Time Elapsed: 8 Minutes, Technique: Kinesiotape, Additional Detail: thoracic paraspinals, cervical, Clinical Use: Decrease Pain, Vector Applied 1: vertical, Charge As: Strapping - Thorax, Billing Code: 29200.

**Modalities:**
• Electric Stim, Unattended

Time Elapsed: 15 Minutes, Location: cervical, Performed With: Cryotherapy, Mode: Continuous, Type: Interferential, Additional Detail: 28 mA, Clinical Use: Post Activity, Charge As: E-Stim, Unattended, Billing Code: 97014.

• Iontophoresis(This visit)
Did Not Perform: This visit

• Ultrasound

Time Elapsed: 20 Minutes, Location: R UTM, Watts/cm2: 1.50, Method: Direct application, Waves: Continuous, MHz: 1, Additional Detail: right rhomboid and cervical paraspinals, Pulse %: 100, Charge As: Ultrasound, Billing Code: 97035.

**Pt./Family Education:**
• Patient Education 1(This visit)

Did Not Perform: This visit

**Timed Code Total Time:**
• 64 Minutes

## Assessment

**Decreased pain to 5/10 at end of session.**

## Plan

**Daily Plan:**
• Continue w/ Current Rehabilitation Program. Reassess objective measurements next visit.

Electronically authenticated.

Leah Hamoy, DPT(SC Lic: 2655)
Signed on Apr 22, 2013 11:41:23

DYNAMIC PHYSICAL THERAP.
OF FLORENCE

2724 W. Palmetto Street, Suite 2
Florence, SC USA 29526
Phone: (843) 292-1900 Fax: (843) 292-1902

Patient: Victor Benjamin
Acct #:
DOB:
Physician: Kart Lozanne
Phys Fax: (803) 794-0322
Physician: Not Specified
Clinician: Leah Hamoy
FSC: Workers Compensation
Case Mgr:
Payor:
Pol/Claim#:

Visit Date: Apr 24, 2013
Phys Phone: (803) 794-3700
SSN:
Inj. Date: Jun 15, 2011
Surg. Date:
Visits: 10
Cxl/Ns: 0
Employer:
Insured:

# Re-Evaluation *Progress Report (No Re-eval Charge)*

## Diagnoses Spine

| | |
|---|---|
| 7231 | CERVICALGIA |
| 7197 | DIFFICULTY IN WALKING |
| 7234 | BRACHIAL NEURITIS NOS |
| 71959 | JT STIFFNESS NEC-MULT JT |

## General Information

**Surgery:**
- Pt underwent cervical fusion on 2-18-13 at C4-/5, 5/6, 6/7.

## Subjective Examination

**ADL / Functional Status: ADL's: Activities:**

| | |
|---|---|
| • Driving/Traveling | 1 hr, slow |
| • Heavy Housework | Unable to perform |
| • Light Housework | Unable to perform |
| • Meal Preparation | heat up food in microwave |
| Sitting: | To 51-60 minutes |
| Sleeping. | 3-5 hrs |
| • Standing. | To 5-10 minutes |
| • Walking. | < 5 min |

**ADL / Functional Status:**
- Current Status: Work status: Unable to work secondary to dysfunction.

**Chief Complaint:**
- Pain: Severity at Worst: 10/10.

**Daily Comments:**
- Pt states that for some reason his pain increased to 10/10 yesterday on the way back from Myrtle Beach from his visit to the neurologist and wonders if the kinesiotape caused it.

**Questionnaires: Disability Index:**

| | |
|---|---|
| • Test Name | Neck Disability Index |
| • Percentage | 70.00% |

## Objective Examination

**Functional Tests: Balance:**

| | |
|---|---|
| • Left Leg, Eyes Open, Firm | 5 seconds |
| • Right Leg, Eyes Open, Firm | 4 seconds |

**Muscle Testing: Grip/Pinch: Five Position Grip Test: Grip Dynamometer III:**

| | Left | Right |
|---|---|---|
| • Gross Assessment | 40 lbs | 20 |

**Muscle Testing: Upper Extremity MMT:**

| | Mar 25, 2013 | | Apr 24, 2013 | |
|---|---|---|---|---|
| | Left | Right | Left | Right |
| • Gross Assessment | +4/5 | +3/5 | +4/5 | +3/5 |

**Muscle Testing: Lower Extremity MMT:**

| | Mar 25, 2013 | | Apr 24, 2013 | |
|---|---|---|---|---|
| | Left | Right | Left | Right |
| Gross Assessment | +3/5 | +3/5 | +3/5 | +3/5 |

| | | | | |
|---|---|---|---|---|
| • Ankle Dorsiflexion | +4/5 | +4/5 | +4/5 | +4/5 |

**Observations:**
• Gross Movements: Protective Posturing: Guarding: Severe.
**Palpation: Cervical Region: Musculature, Posterior: Decreased**

| **Mobility:** | **Left** | **Right** |
|---|---|---|
| • General Muscle Mass | Mild | Mild |

**Posture:**
• Laterally: Cervical Lordosis: Decreased.

| **Range of Motion: Spine: Cervical Degrees:** | **Mar 25, 2013** | **Apr 24, 2013** |
|---|---|---|
| • Active Extension. | 40 Degrees | 55 Degrees |
| • Active Flexion | 5 Degrees | 10 Degrees |
| • Active Rotation Left | 10 Degrees | 35 Degrees |
| • Active Rotation Right | 25 Degrees | 45 Degrees |
| • Active Side Bend Left | 10 Degrees | 20 Degrees |
| • Active Side Bend Right | 10 Degrees | 20 Degrees |

# Treatments

**Documented Procedural Code Summary:**

| Description | Code | Units | Minutes |
|---|---|---|---|
| • Electrical Stimulation (unattended) | 97014 | 1 | n/a |
| • Manual Therapy Techniques | 97140 | 1 | 12 |
| • Therapeutic Procedure | 97110 | 3 | 34 |
| • Ultrasound | 97035 | 2 | 16 |

**Exercise Activities: Range of Motion:**

• ROM Activity 1

Time Elapsed: 4 Minutes, Repetitions: 10, Sets: 1, Technique: Active, Body Position: seated shoulders relaxed, Hold.: 5 Seconds, Description: Cervical all planes, Charge As: Therapeutic Exercise, Billing Code: 97110.

• ROM Activity 2

Time Elapsed: 4 Minutes, Repetitions: 10, Sets: 1, Side: Bilateral, Technique: Active, Body Position: standing back doral palm against wall, Hold.: 1 Seconds, Description: wall angels for scapular mozilization/stabilization, Charge As: Therapeutic Exercise, Billing Code: 97110.

**Exercise Activities: Isometrics:**

• Isometric Activity 1

Time Elapsed: 4 Minutes, Repetitions: 10, Sets: 1, Hold.: 5 Seconds, Additional Detail: supine with auto manual pain free resistance, Description: cervical, Charge As: Therapeutic Exercise, Billing Code: 97110.

**Exercise Activities: Aerobic Conditioning:**

• Airgometer (Airdyne)

Time Elapsed: 10 Minutes, Additional Detail: for aerobic conditioning., Charge As: Therapeutic Exercise, Billing Code: 97110.

**Exercise Activities: Tubing/Bands(U. Quarter):**

• Rows

Time Elapsed: 3 Minutes, Repetitions: 10, Sets: 1, Tubing/Band Color: Yellow, Hold.: 5 Seconds, Resistance: Concentric/Eccentric, Additional Detail: standing, Charge As: Therapeutic Exercise, Billing Code: 97110.

**Exercise Activities: Isotonics(U. Quarter):**

• Shoulder Shrugs

Time Elapsed: 4 Minutes, Weight - Pounds: 1 Pounds, Repetitions: 15, Sets: 1, Hold.: 5 sec Seconds, Additional Detail: seated, Charge As: Therapeutic Exercise, Billing Code: 97110.

**Exercise Activities: Flexibility(U. Quarter):**

**Exercise Activities: Dynamic Training: C-K-C Activity ( U. Quarter):**

- Push-Ups

Time Elapsed: 3 Minutes, Repetitions: 5, Sets: 2, Position: Into Wall, Charge As: Therapeutic Exercise, Billing Code: 97110.

**Exercise Activities: Stabilization Training: Supine Position:**
- Isometric Cervical Retraction

Time Elapsed: 2 Minutes, Repetitions: 10, Hold.: 10 Seconds, Charge As: Therapeutic Exercise, Billing Code: 97110.

**Manual Interventions: Upper Quarter Soft Tissue:**
- Cervicothoracic PVM

Time Elapsed: 12 Minutes, Technique: Strumming, Additional Detail: focus on posterior, Charge As: Manual Therapy Techniques, Billing Code: 97140.

**Manual Interventions: Taping To Stabilize/Align:**
- Thorax Complex(This visit)

Did Not Perform: This visit

**Modalities:**
- Electric Stim, Unattended

Time Elapsed: 15 Minutes, Location: cervical, Performed With: Cryotherapy, Mode: Continuous, Type: Interferential, Additional Detail: 28 mA, Clinical Use: Post Activity, Charge As: E-Stim, Unattended, Billing Code: 97014.

- Iontophoresis(This visit)

Did Not Perform: This visit

- Ultrasound

Time Elapsed: 16 Minutes, Location: R UTM, Watts/cm2: 1.50, Method: Direct application, Waves: Continuous, MHz: 1, Additional Detail: right rhomboid and cervical paraspinals, Pulse %: 100, Charge As: Ultrasound, Billing Code: 97035.

**Pt./Family Education:**
- Patient Education 1(This visit)

Did Not Perform: This visit

**Timed Code Total Time:**
- 62 Minutes

## Assessment

**The patient and/or family were educated regarding their diagnosis, prognosis and related pathology. The client exhibits good understanding and performance of the therapeutic activity and instructions outlined in this skilled rehabilitation session.**

**Assessment of Improvement:**
- Pt has been noted w/ decreased pain from excruciating to severe levels until yesterday for no apparent reason. Pt locus for pain in the R medial scapular area, and cervical region which does tend to improve after modalities and manual intervention at the end of each session. Pt also noted w/ improved CROM, flexibility and exercise tolerance. Pt encouraged to start doing simple, easy activities at home to improve activity tolerance. Pt will benefit from continued PT services to address residual impairments and pain symptoms, and also focus on strengthening for BUE. Pt has only been seen twice weekly instead of 3 x/wk as MD ordered due to lack of insurance authorization.

## Problems & Goals

***Problem #1*** **Chief Complaint: Pain: Severity at Worst: 10/10.**

*STG Achieve by May 08, 2013.*

**Symptomatic Improvements:**
- Decreasing Pain: Decrease worst pain to 6/10

*LTG Achieve by May 22, 2013.*

**Symptomatic Improvements:**
- Decreasing Pain: Decrease worst pain to 5/10 for ease w/ self care and chores

*Goal Achieved Apr 22, 2013.*

**Symptomatic Improvements:**
- Decreasing Pain: to 7/10.

***Problem #2*** **ADL / Functional Status: ADL's: Activities.**

*STG Achieve by May 08, 2013.*

**ADL Improvements In: Activities:**
- Light Housework To 5-10 minutes

*LTG Achieve by May 22, 2013.*

**ADL Improvements In: Activities:**

- Light Housework To 11-20 minutes

***Problem #3*** **Range of Motion: Spine: Cervical Degrees.**

*STG Achieve by May 08, 2013.*

**Range of Motion Improvements to: Cervical:**

| | |
|---|---|
| • Active Flexion | 15 Degrees |
| • Active Rotation Left | 20 Degrees |

*Goal Achieved Apr 15, 2013.*

**Range of Motion Improvements to: Cervical:**

| | |
|---|---|
| • Active Flexion | 10 Degrees |
| • Active Rotation Left | 15 Degrees |

***Problem #4*** **Muscle Testing: Upper Extremity MMT.**

*STG Achieve by May 08, 2013.*

| **Musculoskeletal Improvements In: Upper Extremity Strength to:** | **Right** |
|---|---|
| • Gross Assessment | 4/5 |

*LTG Achieve by May 22, 2013.*

| **Musculoskeletal Improvements In: Upper Extremity Strength to:** | **Right** |
|---|---|
| • Gross Assessment | +4/5 |

***Problem #5*** **Questionnaires: Disability Index.**

*LTG Achieve by May 22, 2013.*

**Questionnaire Improvements: Disability Index:**

| | |
|---|---|
| • Test Name | Neck Disability Index |
| • Percentage | 60.00% |

*Goal Achieved Apr 24, 2013.*

**Questionnaire Improvements: Disability Index:**

| | |
|---|---|
| • Test Name | Neck Disability Index |
| • Percentage | 78.00% |

***Problem #6*** **Palpation: Cervical Region: Musculature, Posterior: Decreased Mobility.**

*STG Achieve by May 08, 2013.*

**Palpable Improvements:**

- Soft Tissue Mobility/Pliability Improving to: Mild Restrictions.

*LTG Achieve by May 22, 2013.*

**Palpable Improvements:**

- Soft Tissue Mobility/Pliability Improving to: Slight Restrictions.

# Plan

**Amount, Frequency and Duration:**

- Frequency and Duration: It is recommended that the client attend rehabilitative therapy for 2 visits a week with an expected duration of 4 weeks. Interventions during the course of treatment will be directed toward addressing the problems and achieving the goals previously outlined.

**Therapeutic Contents:**

- Client Education. Joint Mobilization Techniques. Joint Protection. Home Exercise Program. Manual Range of Motion Activities. Manual Therapy Techniques. Soft Tissue Mobilization Techniques. Stretching/Flexibility Activities. Therapeutic Activities. Therapeutic Exercise.
- Modalities:
  - As Needed. Iontophoresis.

**Therapeutic Contents: Modalities: Iontophoresis: Medication:**

- Medication — Name: Dexamethazone, Dosage: 1.2-2.0cc@40-80mA/mi

Electronically authenticated.

Leah Hamoy, DPT(SC Lic: 2655)
Signed on Apr 25, 2013 14:32:03

DYNAMIC PHYSICAL THERAP.
OF FLORENCE

2724 W. Palmetto Street, Suite 2
Florence, SC USA 29526
Phone: (843) 292-1900 Fax: (843) 292-1902

Patient: Victor Benjamin
Acct #:
DOB:
Physician: Karl Lozanne
Phys Fax: (803) 794-0322
Physician: Not Specified
Clinician: Leah Hamoy
FSC: Workers Compensation
Case Mgr:
Payor:
Pol/Claim#:

Visit Date: Apr 24, 2013
Phys Phone: (803) 794-3700
SSN:
Inj. Date: Jun 15, 2011
Surg. Date:
Visits: 10
Cxl/Ns: 0
Employer:
Insured:

# Plan of Care

## Diagnoses

Spine

| | |
|---|---|
| 7231 | CERVICALGIA |
| 7197 | DIFFICULTY IN WALKING |
| 7234 | BRACHIAL NEURITIS NOS |
| 71959 | JT STIFFNESS NEC-MULT JT |

## Assessment

**The patient and/or family were educated regarding their diagnosis, prognosis and related pathology. The client exhibits good understanding and performance of the therapeutic activity and instructions outlined in this skilled rehabilitation session.**

**Assessment of Improvement:**

- Pt has been noted w/ decreased pain from excruciating to severe levels until yesterday for no apparent reason. Pt locus for pain in the R medial scapular area, and cervical region which does tend to improve after modalities and manual intervention at the end of each session. Pt also noted w/ improved CROM, flexibility and exercise tolerance. Pt encouraged to start doing simple, easy activities at home to improve activity tolerance. Pt will benefit from continued PT services to address residual impairments and pain symptoms, and also focus on strengthening for BUE. Pt has only been seen twice weekly instead of 3 x/wk as MD ordered due to lack of insurance authorization.

## roblems & Goals

*Problem #1* **Chief Complaint: Pain: Severity at Worst: 10/10.**

*STG Achieve by May 08, 2013.*

**Symptomatic Improvements:**

- Decreasing Pain: Decrease worst pain to 6/10

*LTG Achieve by May 22, 2013.*

**Symptomatic Improvements:**

- Decreasing Pain: Decrease worst pain to 5/10 for ease w/ self care and chores

*Goal Achieved Apr 22, 2013.*

**Symptomatic Improvements:**

- Decreasing Pain: to 7/10.

*Problem #2* **ADL / Functional Status: ADL's: Activities.**

| | |
|---|---|
| • Driving/Traveling | 1 hr, slow |
| • Heavy Housework | Unable to perform |
| • Light Housework | Unable to perform |
| • Meal Preparation | heat up food in microwave |
| • Sitting: | To 51-60 minutes |
| • Sleeping. | 3-5 hrs |
| • Standing. | To 5-10 minutes |
| • Walking. | < 5 min |

*STG Achieve by May 08, 2013.*

**ADL Improvements In: Activities:**

- Light Housework To 5-10 minutes

*LTG Achieve by May 22, 2013.*

**ADL Improvements In: Activities:**

- Light Housework To 11-20 minutes

*Problem #3* **Range of Motion: Spine: Cervical Degrees.**

| | |
|---|---|
| • Active Extension. | 55 Degrees |
| • Active Flexion | 10 Degrees |
| • Active Rotation Left | 35 Degrees |
| • Active Rotation Right | 45 Degrees |
| • Active Side Bend Left | 20 Degrees |
| • Active Side Bend Right | 20 Degrees |

*STG Achieve by May 08, 2013.*

**Range of Motion Improvements to: Cervical:**

| | |
|---|---|
| • Active Flexion | 15 Degrees |
| • Active Rotation Left | 20 Degrees |

*Goal Achieved Apr 15, 2013.*

**Range of Motion Improvements to: Cervical:**

| | |
|---|---|
| • Active Flexion | 10 Degrees |
| • Active Rotation Left | 15 Degrees |

*Problem #4* **Muscle Testing: Upper Extremity MMT.**

| | Left | Right |
|---|---|---|
| • Gross Assessment | +4/5 | +3/5 |

*STG Achieve by May 08, 2013.*

| **Musculoskeletal Improvements In: Upper Extremity Strength to:** | | **Right** |
|---|---|---|
| • Gross Assessment | | 4/5 |

*LTG Achieve by May 22, 2013.*

| **Musculoskeletal Improvements In: Upper Extremity Strength to:** | | **Right** |
|---|---|---|
| • Gross Assessment | | +4/5 |

*Problem #5* **Questionnaires: Disability Index.**

| | |
|---|---|
| • Percentage | 70.00% |
| • Test Name | Neck Disability Index |

*LTG Achieve by May 22, 2013.*

**Questionnaire Improvements: Disability Index:**

| | |
|---|---|
| • Test Name | Neck Disability Index |
| • Percentage | 60.00% |

*Goal Achieved Apr 24, 2013.*

**Questionnaire Improvements: Disability Index:**

| | |
|---|---|
| • Test Name | Neck Disability Index |
| • Percentage | 78.00% |

*Problem #6* **Palpation: Cervical Region: Musculature, Posterior: Decreased Mobility.**

| | Left | Right |
|---|---|---|
| • General Muscle Mass | Mild | Mild |

*STG Achieve by May 08, 2013.*

**Palpable Improvements:**

- Soft Tissue Mobility/Pliability Improving to: Mild Restrictions.

*LTG Achieve by May 22, 2013.*

**Palpable Improvements:**

- Soft Tissue Mobility/Pliability Improving to: Slight Restrictions.

# Plan

**Amount, Frequency and Duration:**

- Frequency and Duration: It is recommended that the client attend rehabilitative therapy for 2 visits a week with an expected duration of 4 weeks. Interventions during the course of treatment will be directed toward addressing the problems and achieving the goals previously outlined.

**Therapeutic Contents:**

- Client Education. Joint Mobilization Techniques. Joint Protection. Home Exercise Program. Manual Range of Motion Activities.

Manual Therapy Techniques. Soft Tissue Mobilization Techniques. Stretching/Flexibility Activities. Therapeutic Activities. Therapeutic Exercise.

- Modalities:
  - As Needed. Iontophoresis.

**Therapeutic Contents: Modalities: Iontophoresis: Medication:**

- Medication

Name: Dexamethazone, Dosage: 1.2-2.0cc@40-80mA/mi

Electronically authenticated.

Leah Hamoy, DPT(SC Lic: 2655)
Signed on Apr 25, 2013 14:32:03

## Please sign and return

I have reviewed this Plan of Care and certify that the skilled therapy services identified are required to meet the patient's need. Comments and/or revisions to this Plan of Care are noted below.

**Comments/Revisions**

| Physician/NPP Signature | Date | Print Name and Credentials |
|---|---|---|

DYNAMIC PHYSICAL THERAP
OF FLORENCE

2724 W. Palmetto Street, Suite 2
Florence, SC USA 29526
Phone: (843) 292-1900 Fax: (843) 292-1902

Patient: Victor Benjamin
Acct #:
DOB:
Physician: Karl Lozanne
Phys Fax: (803) 794-0322
Physician: Not Specified
Clinician: Leah Hamoy
FSC: Workers Compensation
Case Mgr:
Payor:
Pol/Claim#:

Visit Date: Apr 29, 2013
Phys Phone: (803) 794-3700
SSN:
Inj. Date: Jun 15, 2011
Surg. Date:
Visits: 11
Cxl/Ns: 0
Employer:
Insured:

# Daily Note

## Diagnoses

Spine

| | |
|---|---|
| 7231 | CERVICALGIA |
| 7197 | DIFFICULTY IN WALKING |
| 7234 | BRACHIAL NEURITIS NOS |
| 71959 | JT STIFFNESS NEC-MULT JT |

## General Information

**Surgery:**
- Pt underwent cervical fusion on 2-18-13 at C4-/5, 5/6, 6/7.

## Subjective Examination

**ADL / Functional Status: ADL's: Activities:**

| | |
|---|---|
| • Driving/Traveling | 1 hr, slow |
| • Heavy Housework | Unable to perform |
| • Light Housework | Unable to perform |
| • Meal Preparation | heat up food in microwave |
| • Sitting: | To 51-60 minutes |
| • Sleeping. | 3-5 hrs |
| • Standing. | To 5-10 minutes |
| • Walking. | < 5 min |

**ADL / Functional Status:**
- Current Status: Work status: Unable to work secondary to dysfunction.

**Chief Complaint:**
- Pain: Severity at Worst: 10/10.

**Daily Comments:**
- Pt states he doesn't know what happened but pain got worse over the weekend for no apparent reason.

**Questionnaires: Disability Index:**

| | |
|---|---|
| • Test Name | Neck Disability Index |
| • Percentage | 70.00% |

## Objective Examination

**Functional Tests: Balance:**

| | |
|---|---|
| • Left Leg, Eyes Open, Firm | 5 seconds |
| • Right Leg, Eyes Open, Firm | 4 seconds |

**Muscle Testing: Grip/Pinch: Five Position Grip Test: Grip Dynamometer III:**

| | Left | Right |
|---|---|---|
| • Gross Assessment | 40 lbs | 20 |

**Muscle Testing: Upper Extremity MMT:**

| | Left | Right |
|---|---|---|
| • Gross Assessment | +4/5 | +3/5 |

**Muscle Testing: Lower Extremity MMT:**

| | Left | Right |
|---|---|---|
| • Gross Assessment | +3/5 | +3/5 |
| • Ankle Dorsiflexion | +4/5 | +4/5 |

**Observations:**
- Gross Movements: Protective Posturing: Guarding: Severe.

| Palpation: Cervical Region: Musculature, Posterior: Decreased | Left | Right |
|---|---|---|
| **Mobility:** | | |
| • General Muscle Mass | Mild | Mild |
| **Posture:** | | |
| • Laterally: Cervical Lordosis: Decreased. | | |
| **Range of Motion: Spine: Cervical Degrees:** | | |
| • Active Extension. | 55 Degrees | |
| • Active Flexion | 10 Degrees | |
| • Active Rotation Left | 35 Degrees | |
| • Active Rotation Right | 45 Degrees | |
| • Active Side Bend Left | 20 Degrees | |
| • Active Side Bend Right | 20 Degrees | |

# Treatments

**Documented Procedural Code Summary:**

| Description | Code | Units | Minutes |
|---|---|---|---|
| • Electrical Stimulation (unattended) | 97014 | 1 | n/a |
| • Manual Therapy Techniques | 97140 | 1 | 12 |
| • Therapeutic Procedure | 97110 | 1 | 13 |
| • Ultrasound | 97035 | 2 | 16 |

**Exercise Activities: Range of Motion:**
- ROM Activity 1(This visit) — Did Not Perform: This visit
- ROM Activity 2(This visit) — Did Not Perform: This visit

**Exercise Activities: Isometrics:**
- Isometric Activity 1 — Time Elapsed: 8 Minutes, Repetitions: 10, Sets: 1, Hold.: 5 Seconds, Additional Detail: supine with auto manual pain free resistance, Description: cervical planes, Charge As: Therapeutic Exercise, Billing Code: 97110.

**Exercise Activities: Aerobic Conditioning:**
- Airgometer (Airdyne)(This visit) — Did Not Perform: This visit

**Exercise Activities: Tubing/Bands(U. Quarter):**
- Rows — Time Elapsed: 3 Minutes, Repetitions: 10, Sets: 1, Tubing/Band Color: Yellow, Hold.: 5 Seconds, Resistance: Concentric/Eccentric, Additional Detail: standing, Charge As: Therapeutic Exercise, Billing Code: 97110.

**Exercise Activities: Isotonics(U. Quarter):**
- Shoulder Shrugs(This visit) — Did Not Perform: This visit

**Exercise Activities: Flexibility(U. Quarter):**

**Exercise Activities: Dynamic Training: C-K-C Activity ( U. Quarter):**
- Push-Ups(This visit) — Did Not Perform: This visit

**Exercise Activities: Stabilization Training: Supine Position:**
- Isometric Cervical Retraction — Time Elapsed: 2 Minutes, Repetitions: 10, Hold.: 10 Seconds, Charge As: Therapeutic Exercise, Billing Code: 97110.

**Manual Interventions: Upper Quarter Soft Tissue:**
- Cervicothoracic PVM — Time Elapsed: 12 Minutes, Technique: Strumming, Additional Detail: focus on posterior, Charge As: Manual Therapy Techniques, Billing Code: 97140.

**Manual Interventions: Taping To Stabilize/Align:**
- Thorax Complex(This visit) — Did Not Perform: This visit

**Modalities:**
- Electric Stim, Unattended — Time Elapsed: 15 Minutes, Location: cervical, Performed With: Cryotherapy, Mode: Continuous, Type: Interferential, Additional Detail: 28 mA, Clinical Use: Post Activity, Charge As: E-Stim, Unattended, Billing Code: 97014.

- Iontophoresis(This visit)
- Ultrasound

Did Not Perform: This visit
Time Elapsed: 16 Minutes, Location: R UTM, Watts/cm2: 1.50, Method: Direct application, Waves: Continuous, MHz: 1, Additional Detail: right rhomboid and cervical paraspinals, Pulse %: 100, Charge As: Ultrasound, Billing Code: 97035.

**Pt./Family Education:**
- Patient Education 1(This visit)

Did Not Perform: This visit

**Timed Code Total Time:**
- 41 Minutes

## Assessment

**Pt reports pain levels to 5/10 at the end of the session.**

## Plan

**Daily Plan:**
- Continue w/ Current Rehabilitation Program. Progression Under Current Plan.

**Hold Rehabilitation Secondary to:**
- awaiting insurance authorization.

Electronically authenticated.

Leah Hamoy, DPT(SC Lic: 2655)
Signed on Apr 30, 2013 17:30:47

DYNAMIC PHYSICAL THERAP.
OF FLORENCE

2724 W. Palmetto Street, Suite 2
Florence, SC USA 29526
Phone: (843) 292-1900 Fax: (843) 292-1902

Patient: Victor Benjamin
Acct #:
DOB:
Physician: Karl Lozanne
Phys Fax: (803) 794-0322
Physician: Not Specified
Clinician: Leah Hamoy
FSC: Workers Compensation
Case Mgr:
Payor:
Pol/Claim#:

Visit Date: May 01, 2013
Phys Phone: (803) 794-3700
SSN:
Inj. Date: Jun 15, 2011
Surg. Date:
Visits: 12
Cxl/Ns: 0
Employer:
Insured:

# Daily Note

## Diagnoses Spine

| | |
|---|---|
| 7231 | CERVICALGIA |
| 7197 | DIFFICULTY IN WALKING |
| 7234 | BRACHIAL NEURITIS NOS |
| 71959 | JT STIFFNESS NEC-MULT JT |

## General Information

**Surgery:**
- Pt underwent cervical fusion on 2-18-13 at C4-/5, 5/6, 6/7.

## Subjective Examination

**ADL / Functional Status: ADL's: Activities:**

| | |
|---|---|
| • Driving/Traveling | 1 hr, slow |
| • Heavy Housework | Unable to perform |
| • Light Housework | Unable to perform |
| • Meal Preparation | heat up food in microwave |
| • Sitting: | To 51-60 minutes |
| • Sleeping. | 3-5 hrs |
| • Standing. | To 5-10 minutes |
| • Walking. | < 5 min |

**ADL / Functional Status:**
- Current Status: Work status: Unable to work secondary to dysfunction.

**Chief Complaint:**
- Pain: Severity at Worst: 10/10.

**Daily Comments:**
- Pt states he's been up since 5:30 am since he didn't take his sleeping meds last noc since he didn't want to be hooked to it.

**Questionnaires: Disability Index:**

| | |
|---|---|
| • Test Name | Neck Disability Index |
| • Percentage | 70.00% |

## Objective Examination

**Functional Tests: Balance:**

| | |
|---|---|
| • Left Leg, Eyes Open, Firm | 5 seconds |
| • Right Leg, Eyes Open, Firm | 4 seconds |

**Muscle Testing: Grip/Pinch: Five Position Grip Test: Grip Dynamometer III:**

| | Left | Right |
|---|---|---|
| • Gross Assessment | 40 lbs | 20 |

**Muscle Testing: Upper Extremity MMT:**

| | Left | Right |
|---|---|---|
| • Gross Assessment | +4/5 | +3/5 |

**Muscle Testing: Lower Extremity MMT:**

| | Left | Right |
|---|---|---|
| • Gross Assessment | +3/5 | +3/5 |
| • Ankle Dorsiflexion | +4/5 | +4/5 |

**Observations:**
- Gross Movements: Protective Posturing: Guarding: Severe.

**Palpation: Cervical Region: Musculature, Posterior: Decreased**

| | Left | Right |
|---|---|---|
| **Mobility:** | | |
| • General Muscle Mass | Mild | Mild |
| **Posture:** | | |
| • Laterally: Cervical Lordosis: Decreased. | | |
| **Range of Motion: Spine: Cervical Degrees:** | | |
| • Active Extension. | 55 Degrees | |
| • Active Flexion | 10 Degrees | |
| • Active Rotation Left | 35 Degrees | |
| • Active Rotation Right | 45 Degrees | |
| • Active Side Bend Left | 20 Degrees | |
| • Active Side Bend Right | 20 Degrees | |

# Treatments

**Documented Procedural Code Summary:**

| Description | Code | Units | Minutes |
|---|---|---|---|
| • Electrical Stimulation (unattended) | 97014 | 1 | n/a |
| • Manual Therapy Techniques | 97140 | 1 | 12 |
| • Therapeutic Procedure | 97110 | 2 | 30 |
| • Ultrasound | 97035 | 2 | 16 |

**Exercise Activities: Range of Motion:**

| | |
|---|---|
| • ROM Activity 1(This visit) | Did Not Perform: This visit |
| • ROM Activity 2(This visit) | Did Not Perform: This visit |

**Exercise Activities: Isometrics:**

• Isometric Activity 1

Time Elapsed: 8 Minutes, Repetitions: 10, Sets: 1, Hold.: 10 Seconds, Additional Detail: supine with auto manual pain free resistance, Description: cervical planes, seated except flexion in supine, Charge As: Therapeutic Exercise, Billing Code: 97110.

**Exercise Activities: Aerobic Conditioning:**

• Airgometer (Airdyne)

Time Elapsed: 10 Minutes, Additional Detail: for aerobic conditioning., Charge As: Therapeutic Exercise, Billing Code: 97110.

**Exercise Activities: Tubing/Bands(U. Quarter):**

• Rows

Time Elapsed: 3 Minutes, Repetitions: 10, Sets: 1, Tubing/Band Color: Yellow, Hold.: 5 Seconds, Resistance: Concentric/Eccentric, Additional Detail: standing, Charge As: Therapeutic Exercise, Billing Code: 97110.

**Exercise Activities: Isotonics(U. Quarter):**

• Shoulder Shrugs

Time Elapsed: 4 Minutes, Weight - Pounds: 1 Pounds, Repetitions: 15, Sets: 1, Hold.: 5 sec Seconds, Additional Detail: seated, Charge As: Therapeutic Exercise, Billing Code: 97110.

**Exercise Activities: Flexibility(U. Quarter):**

**Exercise Activities: Dynamic Training: C-K-C Activity ( U. Quarter):**

• Push-Ups

Time Elapsed: 3 Minutes, Repetitions: 5, Sets: 2, Position: Into Wall, Charge As: Therapeutic Exercise, Billing Code: 97110.

**Exercise Activities: Stabilization Training: Supine Position:**

• Isometric Cervical Retraction

Time Elapsed: 2 Minutes, Repetitions: 10, Hold.: 10 Seconds, Additional Detail: supine nodding, Charge As: Therapeutic Exercise, Billing Code: 97110.

**Manual Interventions: Upper Quarter Soft Tissue:**

• Cervicothoracic PVM

Time Elapsed: 12 Minutes, Technique: Strumming, Additional Detail: focus on posterior, Charge As: Manual Therapy Techniques, Billing Code: 97140.

**Manual Interventions: Taping To Stabilize/Align:**

- Thorax Complex(This visit)

Did Not Perform: This visit

**Modalities:**

- Electric Stim, Unattended

Time Elapsed: 15 Minutes, Location: cervical, Performed With: Cryotherapy, Mode: Continuous, Type: Interferential, Additional Detail: 28 mA, Clinical Use: Post Activity, Charge As: E-Stim, Unattended, Billing Code: 97014.

- Iontophoresis(This visit)

Did Not Perform: This visit

- Ultrasound

Time Elapsed: 16 Minutes, Location: R UTM, Watts/cm2: 1.50, Method: Direct application, Waves: Continuous, MHz: 1, Additional Detail: right rhomboid and cervical paraspinals, Pulse %: 100, Charge As: Ultrasound, Billing Code: 97035.

**Pt./Family Education:**

- Patient Education 1(This visit)

Did Not Perform: This visit

**Timed Code Total Time:**

- 58 Minutes

## Assessment

**Pt able to perform all exercises today in spite of pain levels. Pt instructed on correct supine nodding and flexion isometric since tend to exert more effort than what's tolerable.**

## Plan

**Daily Plan:**

- Continue w/ Current Rehabilitation Program. Progression Under Current Plan.

Electronically authenticated.

Leah Hamoy, DPT(SC Lic: 2655)
Signed on May 03, 2013 10:51:31

DYNAMIC PHYSICAL THERAP
OF FLORENCE

2724 W. Palmetto Street, Suite 2
Florence, SC USA 29526
Phone: (843) 292-1900 Fax: (843) 292-1902

| | | | |
|---|---|---|---|
| Patient: | Victor Benjamin | Visit Date: | May 06, 2013 |
| Acct #: | | Phys Phone: | (803) 794-3700 |
| DOB: | | SSN: | |
| Physician: | Karl Lozanne | Inj. Date: | Jun 15, 2011 |
| Phys Fax: | (803) 794-0322 | Surg. Date: | |
| Physician: | Not Specified | Visits: | 13 |
| Clinician: | Leah Hamoy | Cxl/Ns: | 0 |
| FSC: | Workers Compensation | | |
| Case Mgr: | | | |
| Payor: | | Employer: | |
| Pol/Claim#: | | Insured: | |

# Daily Note

## Diagnoses

Spine

| | |
|---|---|
| 7231 | CERVICALGIA |
| 7197 | DIFFICULTY IN WALKING |
| 7234 | BRACHIAL NEURITIS NOS |
| 71959 | JT STIFFNESS NEC-MULT JT |

## General Information

**Surgery:**

- Pt underwent cervical fusion on 2-18-13 at C4-/5, 5/6, 6/7.

## Subjective Examination

**ADL / Functional Status: ADL's: Activities:**

| | |
|---|---|
| • Driving/Traveling | 1 hr, slow |
| • Heavy Housework | Unable to perform |
| • Light Housework | Unable to perform |
| • Meal Preparation | heat up food in microwave |
| Sitting: | To 51-60 minutes |
| Sleeping. | 3-5 hrs |
| • Standing. | To 5-10 minutes |
| • Walking. | < 5 min |

**ADL / Functional Status:**

- Current Status: Work status: Unable to work secondary to dysfunction.

**Chief Complaint:**

- Pain: Severity at Worst: 10/10.

**Daily Comments:**

- Pt states 8/10 pain this morning. Pt also reports having "laid up" in bed all day Sunday due to R sided upper back pain.

**Questionnaires: Disability Index:**

| | |
|---|---|
| • Test Name | Neck Disability Index |
| • Percentage | 70.00% |

## Objective Examination

**Functional Tests: Balance:**

| | |
|---|---|
| • Left Leg, Eyes Open, Firm | 5 seconds |
| • Right Leg, Eyes Open, Firm | 4 seconds |

**Muscle Testing: Grip/Pinch: Five Position Grip Test: Grip Dynamometer III:**

| | Left | Right |
|---|---|---|
| • Gross Assessment | 40 lbs | 20 |

**Muscle Testing: Upper Extremity MMT:**

| | Left | Right |
|---|---|---|
| • Gross Assessment | +4/5 | +3/5 |

**Muscle Testing: Lower Extremity MMT:**

| | Left | Right |
|---|---|---|
| • Gross Assessment | +3/5 | +3/5 |
| • Ankle Dorsiflexion | +4/5 | +4/5 |

**Observations:**

Gross Movements: Protective Posturing: Guarding: Severe.

**Palpation: Cervical Region: Musculature, Posterior: Decreased**

| **Mobility:** | **Left** | **Right** |
|---|---|---|
| • General Muscle Mass | Mild | Mild |

**Posture:**
• Laterally: Cervical Lordosis: Decreased.

**Range of Motion: Spine: Cervical Degrees:**

| | |
|---|---|
| • Active Extension. | 55 Degrees |
| • Active Flexion | 10 Degrees |
| • Active Rotation Left | 35 Degrees |
| • Active Rotation Right | 45 Degrees |
| • Active Side Bend Left | 20 Degrees |
| • Active Side Bend Right | 20 Degrees |

# Treatments

**Documented Procedural Code Summary:**

| Description | Code | Units | Minutes |
|---|---|---|---|
| • Electrical Stimulation (unattended) | 97014 | 1 | n/a |
| • Manual Therapy Techniques | 97140 | 1 | 12 |
| • Therapeutic Procedure | 97110 | 3 | 33 |

**Exercise Activities: Range of Motion:**
• ROM Activity 1(This visit) — Did Not Perform: This visit
• ROM Activity 2(This visit) — Did Not Perform: This visit

**Exercise Activities: Isometrics:**
• Isometric Activity 1 — Time Elapsed: 8 Minutes, Repetitions: 10, Sets: 1, Hold.: 10 Seconds, Additional Detail: supine with auto manual pain free resistance, out of neutral, Description: cervical planes, seated except flexion in supine, Charge As: Therapeutic Exercise, Billing Code: 97110.

**Exercise Activities: Aerobic Conditioning:**
• Airgometer (Airdyne) — Time Elapsed: 10 Minutes, Additional Detail: for aerobic conditioning., Charge As: Therapeutic Exercise, Billing Code: 97110.

**Exercise Activities: Tubing/Bands(U. Quarter):**
• Rows — Time Elapsed: 3 Minutes, Repetitions: 10, Sets: 1, Tubing/Band Color: Yellow, Hold.: 5 Seconds, Resistance: Concentric/Eccentric, Additional Detail: standing, Charge As: Therapeutic Exercise, Billing Code: 97110.

**Exercise Activities: Isotonics(U. Quarter):**
• Abduction. — Time Elapsed: 1 Minutes, Weight - Pounds: 1 Pounds, Repetitions: 5, Sets: 2, Position: Standing, Charge As: Therapeutic Exercise, Billing Code: 97110.
• Flexion. — Time Elapsed: 2 Minutes, Weight - Pounds: 1 Pounds, Repetitions: 5, Sets: 2, Position: Standing, Charge As: Therapeutic Exercise, Billing Code: 97110.
• Shoulder Shrugs — Time Elapsed: 4 Minutes, Weight - Pounds: 1 Pounds, Repetitions: 15, Sets: 1, Hold.: 5 sec Seconds, Additional Detail: seated, Charge As: Therapeutic Exercise, Billing Code: 97110.

**Exercise Activities: Flexibility(U. Quarter):**

**Exercise Activities: Dynamic Training: C-K-C Activity ( U. Quarter):**
• Push-Ups — Time Elapsed: 3 Minutes, Repetitions: 5, Sets: 2, Position: Into Wall, Charge As: Therapeutic Exercise, Billing Code: 97110.

**Exercise Activities: Stabilization Training: Supine Position:**

- Isometric Cervical Retraction

Time Elapsed: 2 Minutes, Repetitions: 10, Hold.: 10 Seconds, Additional Detail: supine nodding, Charge As: Therapeutic Exercise, Billing Code: 97110.

**Manual Interventions: Upper Quarter Soft Tissue:**
- Cervicothoracic PVM

Time Elapsed: 12 Minutes, Technique: Strumming, Additional Detail: focus on posterior, Charge As: Manual Therapy Techniques, Billing Code: 97140.

**Manual Interventions: Taping To Stabilize/Align:**
- Thorax Complex(This visit)

Did Not Perform: This visit

**Modalities:**
- Electric Stim, Unattended

Time Elapsed: 25 Minutes, Location: cervical, Performed With: Moist Heat, Mode: Continuous, Type: Interferential, Additional Detail: 28 mA, Clinical Use: Post Activity, Charge As: E-Stim, Unattended, Billing Code: 97014.

- Iontophoresis(This visit)

Did Not Perform: This visit

- Ultrasound(This visit)

Did Not Perform: This visit

**Pt./Family Education:**
- Patient Education 1(This visit)

Did Not Perform: This visit

**Timed Code Total Time:**
- 45 Minutes

## Assessment

**Pt reported decreased pain symptoms at end of session and always feels good during the treatments until he gets home.**

## Plan

**Daily Plan:**
Continue w/ Current Rehabilitation Program. Progression Under Current Plan. add prone HA and rows

Electronically authenticated.

Leah Hamoy, DPT(SC Lic: 2655)
Signed on May 06, 2013 11:26:54

| Palpation: Cervical Region: Musculature, Posterior: Decreased Mobility: | Left | Right |
|---|---|---|
| • General Muscle Mass | Mild | Mild |
| Posture: | | |
| • Laterally: Cervical Lordosis: Decreased. | | |
| Range of Motion: Spine: Cervical Degrees: | Mar 25, 2013 | May 06, 2013 |
| • Active Extension. | 40 Degrees | 55 Degrees |
| • Active Flexion | 5 Degrees | 10 Degrees |
| • Active Rotation Left | 10 Degrees | 35 Degrees |
| • Active Rotation Right | 25 Degrees | 45 Degrees |
| • Active Side Bend Left | 10 Degrees | 20 Degrees |
| • Active Side Bend Right | 10 Degrees | 20 Degrees |

## Assessment

Pt reported decreased pain symptoms at end of session and always feels good during the treatments until he gets home. In my professional opinion, this client exhibits a fair prognosis at time of discharge from skilled rehabilitative therapy in conjunction with a home exercise program. The client was educated regarding the discharge prognosis and related pathology. The client exhibits good understanding and is independent in their home exercise program and instructions outlined in this skilled rehabilitation program.

## Problems & Goals

*Problem #1* **Chief Complaint: Pain: Severity at Worst: 10/10.**

*Goal Abandoned May 08, 2013. discharge per worker's comp*

**Symptomatic Improvements:**

- Decreasing Pain: Decrease worst pain to 6/10
- Decreasing Pain: Decrease worst pain to 5/10 for ease w/ self care and chores

*Problem #2* **ADL / Functional Status: ADL's: Activities.**

*Goal Abandoned May 08, 2013. discharge per worker's comp*

**ADL Improvements In: Activities:**

- Light Housework To 5-10 minutes

**ADL Improvements In: Activities:**

- Light Housework To 11-20 minutes

*Problem #3* **Range of Motion: Spine: Cervical Degrees.**

*Goal Abandoned May 08, 2013. discharge per worker's comp*

**Range of Motion Improvements to: Cervical:**

- Active Flexion 15 Degrees
- Active Rotation Left 20 Degrees

*Problem #4* **Muscle Testing: Upper Extremity MMT.**

*Goal Abandoned May 08, 2013. discharge per worker's comp*

| Musculoskeletal Improvements In: Upper Extremity Strength to: | Right |
|---|---|
| • Gross Assessment | 4/5 |
| Musculoskeletal Improvements In: Upper Extremity Strength to: | Right |
| • Gross Assessment | +4/5 |

*Problem #5* **Questionnaires: Disability Index.**

*Goal Abandoned May 08, 2013. discharge per worker's comp*

**Questionnaire Improvements: Disability Index:**

| | |
|---|---|
| • Test Name | Neck Disability Index |
| • Percentage | 60.00% |

*Problem #6* **Palpation: Cervical Region: Musculature, Posterior: Decreased Mobility.**

*Goal Abandoned May 08, 2013. discharge per worker's comp*

**Palpable Improvements:**

- Soft Tissue Mobility/Pliability Improving to: Mild Restrictions.
- Soft Tissue Mobility/Pliability Improving to: Slight Restrictions.

# Plan

**Discharge due to:**

- discharge per worker's comp pt is going to be transferred to a facility closer to his home

Electronically authenticated.

Leah Hamoy, DPT(SC Lic: 2655)
Signed on May 08, 2013 19:24:04

BENJAMIN, VICTOR
Patient #
DOB:
November 5, 2012

Victor has a difficult problem in that he has posterior stenosis with cervical myelomalacia secondary to a cord contusion at the C3-4 level. He was in an accident 18 months ago, which had the effect of causing him to have a head injury with unconsciousness. He has some persistent symptoms into his arms and legs. He has a positive Lhermitte's sign.

He has myelomalacia in his cord. He has severe stenosis. He has spasticity. He has a positive Babinski, upgoing toes, hyperreflexia, positive Hoffmann's sign, severe stenosis at C3-4 with myelomalacia. Other levels have some spondylitic changes, but this C3-4 myelomalacia and cord contusion necessitates posterior cervical decompression. I have seen him and examined him with Dr. Rick Frisch. I do think that posterior cervical decompression with fusion is indicated.

He understands the severity of the procedure and that he certainly has to do it or else he will worsen, and he wishes to proceed. We will go ahead in the coming weeks pending surgical approval.

Steven C. Poletti, M.D.

SCP/dmp
T- 11/6/12

1106 Chuck Dawley Blvd., Suite 200 ■ Mt. Pleasant, SC 29464

Patient Name: Victor Benjamin Encounter Date: 1/20/2014 Date of Birth:

Account Number

Mr. Benjamin returns to the office today with complaints of neck, shoulder, and right arm pain. He has continued issues with difficulty walking and imbalance. He denies any bowel or bladder issues.

Mr. Benjamin has had somewhat of an unusual history over the past year or two. He was seen in 2012 with cervical myelomalacia at C3-4. Then, he had surgery through his work comp carrier in Columbia. He had three level fusion surgery done by Dr. Lozanne at C4-5, C5-6, and C6-7. He did not have surgery at C3-4.

He's had AP and lateral views of the cervical spine today, which show appropriate positioning of the anterior plate and interbodies at C4-5, C5-6, and C6-7. No settling or shifting has been detected. There's a solid-appearing fusion. There's continued evidence of disc-height collapse, spondylosis, and kyphosis noted at C3-4.

He has had some persistent issues. He had a laceration on his right arm, but no further treatment was recommended by the upper extremity specialist.

His neurologic exam continues to show lower extremity hyperreflexia. He has an altered gait. He has loss of motion in his cervical spine. Hand myelopathy signs are seen.

Ultimately, he requires an immediate cervical MRI scan with and without contrast. We will reassess this C3-4 problem that he had more than a year ago. We will discuss treatment options with him once the images are obtained.

**Diagnosis Codes:**

722.81 POSTLAMINECTOMY SYND CERVICAL

**Impression:** Cervical pain.

**Treatment Plan:** Valium 5 mg tablets were prescribed; side effects were discussed and appropriate instructions were provided. An MRI of the cervical spine was ordered. The patient is to return when the result of MRI is available.

Seen By: Justin P. Swain, PA

Date:1/20/2014

sk

**DIGITALLY SIGNED**

1106 Chuck Dawley Blvd., Suite 200 ■ Mt. Pleasant, SC 29464

## MRI REQUEST FORM

Name: Victor Benjamin
DOB:
ACTT #:

Home Phone: (803) 428-3352
Cell Phone: (803) 316-6766

Weight: Weight 181lbs
Sex: male

Reason for test: Pain
Referring Provider: Steven C. Poletti, MD
Referring Provider NPID: 1508841859
Suggested Diagnosis: 722.81 POSTLAMINECTOMY SYND CERVICAL
793.7 - ABNORMAL FIND MUSCULOSKEL SYS
Test Requested: MRI of the cervical spine

☑ 3D Holograph Images ☑ With/Without Contrast ☐ With Contrast ☐ Without Contrast

X-ray Screening Cleared: Oral Sedation Given ☐ Yes ☐ No
Claustrophobic: ☐ Yes ☐ No
MRI Appointment: Date: 1/20/2014 Time: 1:20 ARRIVAL 12:50 Bldg: ☐ A ☑ B
Doctor Appointment: Date: 1/21/2014 Time: 11:10 BUILDING A
Instructions: take Sedation @ 12:20

Seen By: Justin P. Swain, PA

Date: 1/20/2014

SOUTHEASTERN SPINE
1106 CHUCK DAWLEY BLVD STE 200
MT PLEASANT, SC 29464
843-849-1551

Merchant ID: 0EU7005568
Term ID: 6522

Sale

VISA
XXXXXXXXXXXX5016
Entry Method: Swiped
Apprvd: Online Batch#: 000007
01/20/14 13:33:12
Invl: 00000001 Appr Code: 945224

Total: $ 206.41

Customer Copy
THANK YOU

1106 Chuck Dawley Blvd.
Mt. Pleasant, SC 29464
(843) 849-1551

1 of 2

(532)

12 - Surgery

**Superbill: Benjamin, Victor**
Encounter #: 4811240
DOS: 1/21/2014
Visit Reason: PFU

**Southeastern Spine Institute**
Attending Provider: Steven C. Poletti, MD
Seen By: Poletti, Steven
Referring Physician:

| | | |
|---|---|---|
| Benjamin, Victor<br>1841 Holman Rd<br>Sumter, SC, 29153 | DOB:<br>Acct #:<br>Phone #: (803) 428-3352 | Insurance 1: Uhc<br>Insurance 2:<br>WC Insurance: Sedgwick Cms |

**E/M:** 99214-57 (Office/outpatient Visit, Est)

**Exam:** Disc Degeneration, Cervical - 722.4 (Onset: )

- 722.4 , DEGENERATION CERVICAL IV DISC

Copay $25
CASH

**Treatment Plan:**

**Surgery:**

- Surgery Scheduling Worksheet

MRI 1/20/14 NW
DX4 1/20/14

**Medical Conditions**

- High Cholesterol
- Hypertension
- headaches

**Medications**

- metoclopramide 10 mg tablet, Prescriber: RAZICK
- NuLYTELY with Flavor Packs 420 gram Oral Solution, Prescriber: RAZICK
- Norco 10 mg-325 mg tablet, Prescriber: Justin P. Swain, PA
- Valium 5 mg tablet, Prescriber: Justin P. Swain, PA
- pravastatin 40 mg tablet, Prescriber: FRANCO
- hydrocodone 10 mg-acetaminophen 325 mg tablet, Prescriber: SWAIN, JUSTIN
- clonazepam 2 mg tablet, Prescriber: DEAL, ROGER

**Allergies**

Demerol

Supervising Physician:

Richard C. Holgate, M.D.

The Southeastern Spine Institute
1106 Chuck Dawley Blvd.
Mount Pleasant, SC 29464
843-849-1551

# FINAL REPORT

**Patient:** Victor Benjamin

**Patient Phone:** –

**SSN:**

**Patient #:**

**Exam Date:** 1/20/2014

**Exam Name:** Cervical

**Modality:** MRI

**Referring Doctor:** Poletti, Steven

**Clinical Information:** M/51 WITH NECK AND RIGHT ARM PAIN SINCE 6/2011. NO RECENT TRAUMA. HT-6'0" WT-181 LBS.

**TECHNIQUE:** The patient is examined on the High Field GE Horizon LX High Speed MR System . A phased array coil is used to obtain high resolution images of the cervical spine. **SERIES:** 1) COR, T1, SE, 7 mm; 2) SAG, T2, FSE, 3 mm; 3) AX, T2, GRE, 4 mm. **ADDITIONAL SERIES:** 1) AX, T1, SE, 5 mm; 2) SAG, T1, SE/Fat Sat, 3 mm; 3) AX, T1, SE, 3 mm. **3D REFORMATIONS:** 3mm REFORMATIONS PERFORMED IN 1) AX; 2) COR; 3)SAG/OBL RT; 4) SAG/OBL LT; 5) CORONAL PLANES.

**CONTRAST:** The last two T1 weighted axial sequences were carried out following injection of 8 cc of contrast. ( With and Without Contrast )

**OVERVIEW:** Overview of the cervical spine shows there is normal marrow signal and normal bony alignment with no evidence of a congenital; anomaly of the spine. The visualized paraspinal soft tissues which include the pulmonary apices and the proximal brachial plexus are within normal limits. Hardware shows previous surgery at C4-5, C5-6 and C6-7.

**SPINAL CORD** The spinal cord is demonstrated from the craniocervical junction down to the upper thoracic region. It is of normal caliber throughout showing no evidence of compression or enlargement and no area of focal signal abnormality to indicate the presence of intrinsic spinal cord disease. There is no evidence of abnormal enhancement within the spinal cord.

**C2-3.** Mild noncompressive spondylosis.

**C3-4.** Osteophytes with severe bilateral foraminal stenosis.

**C4-5.** Fusion with hardware and moderate bilateral foraminal stenosis.

**C5-6.** Fusion with hardware and moderate severe right and moderate left foraminal stenosis.

**C6-7.** Fusion with hardware and severe left with moderate to moderately severe right foraminal stenosis.

**C7-T1..** Osteophytes with moderate to severe bilateral foraminal stenosis more pronounced on the left.

**3D REFORMATIONS:** Because of movement between sagittal and axial sequences

multiplanar 3D reformations were performed for accuracy and confirm the findings set out above. Please refer to the axial and oblique sagittal reformations for accuracy.

**Opinion:** MRI of the cervical spine including multi-planar reformations show a normal spinal cord, multilevel surgery and multilevel spondylosis with probable root compression at levels showing severe or moderately severe foraminal stenosis. No abnormal enhancement is seen in the cervical spine.

**Patient:** Victor Benjamin
**Patient #:** 666500
**Exam Name:** Cervical
**Exam Date:** 1/20/2014

Richard C. Holgate, MD
DISC Radiologists
1341C Old Georgetown Road - Mount Pleasant, SC 29464
(843) 884-8095 - (800) 898-1294 - Fax (843) 856-7312

## X-RAY REPORT

**Patient:** Benjamin, Victor
**DOB:**
**Date of X-Ray:** 1/20/2014

**Reason for X-Ray:** Pain Cervical
**Body Part:** Cervical
**X-Ray ordered:** X-Ray 72050 - Cervical Spine, 4v - AP Lat F/E

**Imaging Findings:**

**Impression:** 722.81 POSTLAMINECTOMY SYND CERVICAL Cervical pain.

Seen By: Justin P. Swain, PA

1106 Chuck Dawley Blvd.
Mt. Pleasant, SC 29464
(843) 849-1551

1106 Chuck Dawley Blvd, Suite 200 ■ Mt. Pleasant, SC 29464

Patient Name: Victor Benjamin Encounter Date: 1/21/2014 Date of Birth:

Account Number

Mr. Benjamin has had his follow-up MRI and it shows that he has edema within his spinal canal and progressive stenosis at the C3-4 level. This man has edema changes in his spinal canal at the C3-4 level and he has signs of spastic cervical myelopathy.

I have re-reviewed the medical records form Dr. Lasane and it does indicate that he did not feel that C3-4 required surgical intervention because he did not see significant neural compression despite the fact that there is spinal cord signal change at that level.

I do agree that the C3-4 level is the site of his original contusion, that is were his spinal cord edema is and the thought of fusing the spine to the level of the spinal cord contusion is one that while theoretically sensible, has unfortunately resulted in a situation where he has gotten worsening stenosis or progressing cervical stenosis at the C3-4 level where there is noted to be edema changes in the cord, some measure of settling and posterior disc bulging at the C3-4 level with spinal cord compression with high signal in the cord at the C3-4 level.

**Diagnosis Codes:**

722.4 DEGENERATION CERVICAL IV DISC

**Impression:** Degeneration of Cervical Disc

**Treatment Plan:** I do believe this man should consider surgery. He has spastic reflexes, he has hand myelopathy signs. I absolutely think that a functional capacity evaluation is contraindicated here and I am absolutely not recommending it at this point. He should be on off duty status.

Posterior decompression, laminectomy and fusion at the C3-4 level is indicated. I would ask Dr. Frisch to do this surgery with my assistance as that is the level of his expertise. I have cautioned Mr. Benjamin that he is most likely not to improve with surgery, but the surgery could prevent him from worsening. Unfortunately he has had the fusion from the front, he has developed progressive myelopathic symptoms and stenosis at C3-4 and requires the posterior decompression and ankylosis as described.

Since non operative measures have not given lasting relief and pain persists, surgery was advised. Nature of the procedure, risks, problems, possible complications, sequelae of complications as well as rehabilitation involved all were discussed and explained. All questions were answered.

Seen By: Steven C. Poletti, MD

**DICTATED, NOT READ**

East Cooper Medical Center
2000 Hospital Drive
Mount Pleasant, SC 29464
(843) 881-0100

**History and Physical**

| | | | |
|---|---|---|---|
| Patient Name: | BENJAMIN, VICTOR | RICHARD F FRISCH, M.D. | |
| MRN: | | ADM: | 02/13/2014 |
| ACCT: | | Pt. Class: | P |
| DOB: | | Room / Bed: | |

CHIEF COMPLAINT:
1. Neck pain.
2. Right upper extremity pain.
3. Difficulty with walking and weakness.

HISTORY OF PRESENT ILLNESS: Mr. Victor Benjamin is a 51-year-old gentleman who complaints of neck, shoulder and right arm pain. He has had continued issues with difficulty walking and imbalance. We have seen him in the past as a patient of Dr. Poletti's with cervical myelomalacia in 2012 at C3-C4. He has had a 3-level fusion done by Dr. ___ at C4-C5, C5-C6 and C6-C7.

PAST MEDICAL HISTORY: Includes hypertension, concussion, hypercholesterolemia and seizures.

PAST SURGICAL HISTORY: Aforementioned cervical fusion.

MEDICATIONS: Oxycodone, Valium, clonazepam, pravastatin, Norco, metoclopramide.

DRUG ALLERGIES: DEMEROL.

SOCIAL HISTORY: Denies smoking, was never a previous smoker.

PHYSICAL EXAMINATION:
GENERAL: Healthy-appearing well-nourished male, alert and oriented x 3, cooperative for examination today.
MUSCULOSKELETAL: He has myelopathic signs in his hands, lower extremity hyperreflexia and altered gait. He has decreased cervical range of motion.

IMAGING: Cervical MRI shows progressive spinal stenosis at C3-C4 with _____ changes in the spinal canal.

ASSESSMENT: C3-C4 spinal stenosis and cervical myelopathy.

PLAN: After a long discussion of clinical and radiographic symptoms, we do feel he needs a posterior decompression and laminectomy and fusion at C3-C4. Risks of surgery were discussed to include, but not be limited to paralysis, neurologic injury, failure to relieve symptoms, no guaranteed return of strength, cerebrospinal fluid leakage, bleeding, infection or death; benefits being partial relief of his upper extremity symptoms. He understands and would like to proceed.

East Cooper Medical Center

Patient Name: BENJAMIN VICTOR RICHARD F FRISCH, M.D.
MRN: ACCT:

"I have examined the patient and there are no changes to the H&P."

Signature: _____ Date:_____ Time:_____

RICHARD F FRISCH, M.D.

Dictated by KELLY M. EDDINGER, PA
DATE ____ TIME__.

SPKR: KME DD: 02/13/2014 09:39 EST DT: 02/13/2014 10:35 EST
JOB#: 5056728 MT#: FI
DOCUMENT#: 11497409
R:

ECH - East Cooper Medical Center
2000 Hospital Drive
Mt. Pleasant, SC 29464
(843)881-0100

Date and Time Generated: Wed Feb 26 15:45:59 EST 2014
Generated by: Ianisha Vann

BENJAMIN, VICTOR G ( SU 0421 0 )

SIGNED

| | | | |
|---|---|---|---|
| Report Name | ECH-Operative Report | Dictation Date/Time | 02/14/2014 10:26:00 |
| Dictating Physician | FRISCH, RICHARD F | Transcription Date/Time | 02/14/2014 11:13:09 |
| Medical Record Number | | Document ID | 11506895 |
| Account Number | | Admit Date | 02/13/2014 10:36:00 |
| Date Of Birth | | Discharge Date | 02/15/2014 13:45:00 |

System copy - not from charted Original. This is not an official and legal document.

DATE OF SERVICE:

PREOPERATIVE DIAGNOSES: Cervical spondylitic myelopathy.

POSTOPERATIVE DIAGNOSES: Cervical spondylitic myelopathy.

PROCEDURES:
1. C3 laminectomy.
2. C3-C4 posterior spinal fusion.
3. C3-C4 nonsegmental instrumentation.
4. Application cranial tongs.
5. Local autograft.

SURGEON: Richard Frisch, M.D.

ASSISTANT: Steven Polenti, M.D.

ANESTHESIA: General.

ESTIMATED BLOOD LOSS: 50 mL

IMPLANTS: Globus.

NEUROMONITORING: MEPs, SSEPs and EMGs.

INDICATIONS: The patient is a 51-year-old gentleman with the aforementioned diagnoses. Please refer to clinic notes for explanation of indications.

DESCRIPTION OF PROCEDURE: On the day of surgery, I met the patient in the preoperative holding area. A - final questions were answered. His back was marked. He was taken to the operating room, given general anesthetic, endotracheally intubated. TEDs and SCDs were placed, a Foley was placed, intravenous access obtained and monitoring leads for measurements of MEPs, SSEPs and EMGs were placed. I then placed cranial tongs in standard fashion and he was then transferred to a prone position on the operating room table and attached to Mayfield headholder. His arms were appropriately positioned as well as his neck. All bony prominences adequately padded. X-rays were then taken to confirm appropriate access to C3-C4 level, then he was prepped and draped in usual sterile fashion. Timeout performed and IV antibiotics were given.

Next, with the assistance of fluoroscopic-guided imaging, an approximate 50-mm incision was made midline centered over the C3-C4 disk space with a 15-blade

scalpel. Standard dissection was then performed and the bilateral C3 and C4 lamina were exposed as well as the interior aspect of C3, retractors were placed and x-rays were taken to confirm appropriate level. Next, the drill holes for the screws were placed bilaterally into the C3 and C4 lateral masses.

Next, we turned our attention to the laminectomy portion of the case in which an AM-8 burr and #1 Kerrisons were used to create troughs to the lateral edge of the lamina and release the underlying ligamentum flavum, which was then removed in 1 block allowing for decompression of the spinal cord. Once complete, the spinal cord was found to be without further compression and 14-mm screws were placed bilaterally into the lateral masses of C3 and C4. The intervening facets were burred and local autograft was placed. Rods were then placed within the screw heads and secured to the screws with caps, which were counter torqued. Once complete, x-rays were taken for appropriate placement of instrumentation. Incision was copiously irrigated, deep JP drain was placed. A gram of vancomycin powder was placed. Incision was closed in a layered fashion. Sterile dressings were applied. The patient was then released from the Mayfield headholder and transferred supine onto the stretcher and the cranial tongs were removed. He was extubated and found to have flexion and extension of bilateral wrists and ankles. Sponge and needle counts correct x 2 at the end of the case. There were no changes in MEPs or SSEPs and EMGs were quiet at the end of the case.

RICHARD F. FRISCH, M.D.

TR:RFF/AN
DD:02/14/2014 10:26 EST
DT:02/14/2014 11:13 EST
Dictation ID: 11506895/Confirmation #: 5061677
R:

Authenticated by Richard Frisch, MD On 02/17/2014 08:59:30 AM

End of Report

SIGNED

End of Report

1106 Chuck Dawley Blvd., Suite 200 ■ Mt. Pleasant, SC 29464

Patient Name: Victor Benjamin  Encounter Date: 2/27/2014  Date of Birth:
Account Number:

Mr. Benjamin returns for follow-up visit today. He is still in the postoperative course after posterior decompression and fusion done at C3-4. He has had AP/lateral x-rays of the cervical spine which appropriate position of the screws. His previous fusion site is unchanged and stable.

Mr. Benjamin is wearing his collar. He still has a slow gait. He has not worsened with regards to altered gait or unsteadiness. He has maintained strength in his upper and lower extremities with no further decline.

I think he does have some measure of improvement. He does continue to take Oxycodone for pain.

**Diagnosis Codes:**
V45.89 POSTSURGICAL STATUS

**Treatment Plan:** We have gone over generalized precautions with him. I recommend he continue with the collar for the most part. he can continue with Oxycodone for pain. I will give him a refill today. We will plan to see him back in the next 1 months time for re-evaluation and repeat x-rays. He will call with any questions or concerns prior to this visit. Oxycodone 10 mg tablets were prescribed; side effects were discussed and appropriate instructions were provided. Patient to return in 1 month for follow up.

Seen By: Justin P. Swain, PA

Date:2/28/2014
JPS/dam

DIGITALLY SIGNED

1106 Chuck Dawley Blvd., Suite 200 ■ Mt. Pleasant, SC 29464

Patient Name: Victor Benjamin  Encounter Date: 4/3/2014  Date of Birth:
Account Number:

**History of Present Illness:** Mr. Benjamin is being seen today for his second postoperative visit. He is status post posterior cervical laminectomy and fusion at the C3-4 level for cervical myelopathy. He is approximately six weeks status post surgical intervention. He continues to report issues with his balance which are more than likely a permanent situation. He has off and on pain. He states that he is currently taking Hydrocodone prescribed by his neurologist that he was following with prior to surgery. He denies any worsening symptoms. Overall, he is stable.

**Past Medical History:** High Cholesterol (272.0 ), Hypertension (401.9 ), Headaches.

**Current Medications:** NuLYTELY with Flavor Packs 420 gram Oral Solution SolR, metoclopramide 10 mg tablet Oral, Norco 10 mg-325 mg tablet 2 by mouth as directed take 2 tablets 30 min prior to MRI, Valium 5 mg tablet 3 by mouth as directed 30 minutes before MRI, pravastatin 40 mg tablet Oral, clonazepam 2 mg tablet Oral, Valium 10 mg tablet 1 by mouth TID prn spasms, oxycodone 10 mg tablet 1-2 by mouth prn pain, hydrocodone 10 mg-acetaminophen 325 mg tablet Oral, doxycycline hyclate 100 mg capsule Oral.

**Drug Allergies:** Demerol.

**Imaging:** AP and lateral cervical films were reviewed. They show good positioning of his posterior screws at C3-4 and solid fusion from previous surgery below.

**Diagnosis Codes:**
V45.89 POSTSURGICAL STATUS

**Treatment Plan:** I have discussed with Mr. Benjamin continuation of wearing his collar. He continues to ambulate with unsteadiness and uses a cane for assistance with ambulation. He has had no further neurological decline, however has had very little improvement. I will have Dr. Poletti step in to review x-rays and address any other questions that Mr. Benjamin may have today. I have discussed with Mr. Benjamin his pain medication situation. He would like to continue following with his neurologist. We have discussed that he should only receive pain medications from one provider and he does understand this.

Patient to return in 6 weeks for follow up.

Seen By: Steven C. Poletti, MD

**DICTATED, NOT READ**

Date:4/4/2014
SCP/GRA/js

X-RAYS:

X-ray Report: AP and lateral cervical films were reviewed. They show good positioning of his posterior screws at C3-4 and solid fusion from previous surgery below.

DICTATED, NOT READ

SOUTHEASTERN SPINE INSTITUTE
1105 Chuck Dawley Blvd., Suite 200 ■ Mt. Pleasant, SC 29464

Patient Name: Victor Benjamin  Encounter Date: 4/3/2014  Date of Birth:
Account Number:

**History of Present Illness:** Mr. Benjamin is being seen today for his second postoperative visit. He is status post posterior cervical laminectomy and fusion at the C3-4 level for cervical myelopathy. He is approximately six weeks status post surgical intervention. He continues to report issues with his balance which are more than likely a permanent situation. He continues to ambulate with unsteadiness and uses a cane for assistance with ambulation. He has had no further neurological decline, however has had very little improvement. He has off and on pain. He states that he is currently taking Hydrocodone prescribed by his neurologist that he was following with prior to surgery. I have discussed with Mr. Benjamin his pain medication situation. He would like to continue following with his neurologist. We have discussed that he should only receive pain medications from one provider and he does understand this. He denies any worsening symptoms. Overall, he is stable.

**Past Medical History:** High Cholesterol (272.0), Hypertension (401.9), Headaches.

**Current Medications:** NuLYTELY with Flavor Packs 420 gram Oral Solution SolR, metoclopramide 10 mg tablet Oral, Norco 10 mg-325 mg tablet 2 by mouth as directed take 2 tablets 30 min prior to MRI, Valium 5 mg tablet 3 by mouth as directed 30 minutes before MRI, pravastatin 40 mg tablet Oral, clonazepam 2 mg tablet Oral, Valium 10 mg tablet 1 by mouth TID prn spasms, oxycodone 10 mg tablet 1-2 by mouth prn pain, hydrocodone 10 mg-acetaminophen 325 mg tablet Oral, doxycycline hyclate 100 mg capsule Oral.

**Drug Allergies:** Demerol.

**Imaging:** AP and lateral cervical films were reviewed. They show good positioning of his posterior screws at C3-4 and solid fusion from previous surgery below.

**Diagnosis Codes:**
V45.89 POSTSURGICAL STATUS

**Treatment Plan:** Mr. Benjamin has had the posterior cervical decompression and fusion done 2/13/14. He is medically stationary in that he has not worsened since his operation. He had posterior cervical fusion extending up to the C3-4 level. He is medically stationary at this point.

This man has a difficult situation in that he has had multilevel ankylosis or fusion. The situation in his spine is a difficult one in that he has this spinal cord compression and cervical myelopathy and has had two fusion operations. The fusion has been done anteriorly at three levels and posteriorly at an additional level and impairment for ankylosis anteriorly and posteriorly is at least 28% at each side giving him an impairment greater than 50%. This man is totally and permanently disabled. He has signs of spasticity, he has inability to use his hands for repetitive fine motor activities. He meets the obvious criteria for pursuing permanent disability, Social Security disability and there is no amount of

DIGITALLY SIGNED Steven C. Poletti, MD
4/18/2014

vocational retraining or therapy that can change that. He unfortunately neurologically has "got what he's got." The rationale behind the surgery was to prevent him from worsening which I believe was happening.

This man has had comprehensive care for a difficult problem. My above opinions are held to a reasonable degree of medical certainty. He is going to follow up with me in one month's time and continue using the collar.

Patient to return in 6 weeks for follow up.



Seen By: Steven C. Poletti, MD

Date:4/4/2014
SCP/GRA/js

X-RAYS:

X-ray Report: AP and lateral cervical films were reviewed. They show good positioning of his posterior screws at C3-4 and solid fusion from previous surgery below.

CC: Jeff C. Chandler, Esquire

JEFFREY C. CHANDLER, P.C.
FEIN 20-0523540

April 08, 2014

Southeastern Spine Institute
Attn: Dr. Steven Poletti
1106 Chuck Dawley Blvd. Suite 200
Mt. Pleasant, SC 29464

Re: Victor Benjamin DOB: DOI:

Dear Dr. Poletti:

I represent the above named client regarding a work-related injury that you have provided treatment for. My client was injured when a protective guard came off a machine and he was hit with a piece of metal. He had a three level cervical fusion by Dr. Karl Lozanne on 02-18-2013 at levels C4-5, C5-6, 6-7. Prior to this surgery, Mr. Benjamin came to your office on 11-05-2012 for a surgical consult. At that time, your recommendation was posterior decompression, laminectomy with fusion at C3-4. He returned to your office on 01-20-2014 for a second surgical opinion. I have reviewed your office note dated 1-21-2014, wherein it was your recommendation that Mr. Benjamin proceed with posterior decompression, laminectomy and fusion at the C3-4 level.

1. Are you able to state to a reasonable degree of medical certainty that the posterior decompression, laminectomy and fusion at the C3-4 level you performed on 02-13-2014 was casually related to the work injury Mr. Benjamin sustained on 06-15-2011?

yes

2. Was the surgery you performed on 02-13-2014 of an urgent/emergent nature and performed to prevent possible paralysis or greater damage to Mr. Benjamin?

yes

My opinions are to a reasonable degree of medical certainty. yes

Dr. Steven Poletti Date 4/20/14

Best Regards,

Jeff Chandler

cc: file

P.O. Drawer 1689 • Myrtle Beach, SC 29578-1689
Office (843) 448-4357 • Fax (843) 448-400 (547) ler@aol.com • www.jeffchandlerlaw.com

SOUTHEASTERN SPINE INSTITUTE
1105 Chuck Dawley Blvd., Suite 200 ■ Mt. Pleasant, SC 29464

Patient Name: Victor Benjamin  Encounter Date: 5/15/2014  Date of Birth:
Account Number:

Mr. Benjamin is being seen today for a 6 week follow-up appointment. He is approximately 3 months S/P posterior cervical laminectomy and fusion at the C3-4 level. He has a previous history of a three level cervical fusion done from C-4 through C-7. Today he feels that he is slowly improving regarding his neck pain. He does continue to have some intermittent neck pain but denies any radiating arm pain. He feels that his strength is slightly improving in his upper extremities. He is continuing to wear his hard cervical collar. He does feel that he is improving. Today he complains of right sided back pain, buttock pain and leg pain. This has been going on since his accident but the cervical pain had been more severe. He recalls that his pants that he was wearing when the accident occurred were shredded and damaged as a result. This is evident on the right side of his body. He states that the pain in his right leg is intermittent and describes it as an achy pain with occasional sharp stabbing pains. He quantifies his pain as a 10/10 on the pain scale. He does feel some tingling into his right foot as well as weakness on the right side. The pain is worse when he is laying in bed at night. He feels it has gotten progressively worse over the past few months. He denies any bowel or bladder disturbance or any paralysis. He continues to take Hydrocodone from his neurologist. He continues to use a cane for assistance with ambulation due to feeling unstable.

Imaging: AP/lateral views of his cervical spine were reviewed with him today. They do show appropriate positioning of the posterior screws at the C3-4 level. His prior fusion from C-4 to C-7 does appear stable. There is solid fusion at this level. Four views of his lumbar spine were reviewed with him today. There is a possible pars defect at the L-5 level. There is some mild to moderate disc height space collapse at the L5-S1 level.

On physical exam he is a well developed, well nourished male alert and oriented x3 in no acute distress. He is ambulatory with a cane. He has a slightly antalgic gait. He has positive straight leg raise on the right, negative on the left. He has diminished deep tendon reflexes on the right. He has diminished range of motion in his lumbar spine with pain on extension. He has 5/5 strength regarding ankle dorsiflexion, EHL extension on the left. He has 3/5 strength on the right. His cervical spine exam is stable. He has negative Hoffman's sign bilaterally. He has diminished grip strength bilaterally but this is stable. He has diminished range of motion of his cervical spine. He is currently wearing his cervical collar.

**Diagnosis Codes:**
V45.89 POSTSURGICAL STATUS
724.4 UNS THORACIC/LUMB NEURITIS/RADICUL

**Impression:** Cervical pain
Lumbar Radiculitis

**Treatment Plan:** I would like for Mr. Benjamin to get a lumbar MRI scan to better evaluate the potential for a pars defect and determine the cause of his leg pain. We will have him follow-up in the office after this has been completed.

DIGITALLY SIGNED Justin P. Swain, PA
6/2/2014

We will continue to monitor his neck issues. I would like for him to continue to wear the hard collar, but he can switch to the soft cervical collar to sleep in. He is someone who will continue to have restrictions and limitations regarding his cervical and lumbar spine. This is a permanent situation for him. He is totally and permanently disabled at this point. This was documented at his last office visit dating April 3, 2014. We discussed if he is having any worsening pain or changes in his symptoms he will contact our office and we will be happy to see him about this. Otherwise we will have him undergo the lumbar MRI scan and see him back after this.

Valium 5 mg tablets were prescribed; side effects were discussed and appropriate instructions were provided. Norco 10-325 mg tablets were prescribed; side effects were discussed and appropriate instructions were provided. An MRI of the lumbar spine was ordered. A work status report was created and given to the patient. The patient is instructed to call us if pain persists or get worse. The patient is to return when the result of MRI is available.

Seen By: Justin P. Swain, PA

Date:5/20/2014
JS/LT/dam

Imaging: AP/lateral views of his cervical spine were reviewed with him today. They do show appropriate positioning of the posterior screws at the C3-4 level. His prior fusion from C-4 to C-7 does appear stable. There is solid fusion at this level. Four views of his lumbar spine were reviewed with him today. There is a possible pars defect at the L-5 level. There is some mild to moderate disc height space collapse at the L5-S1 level.

DISCRAD

Richard C Holgate, MD

The Southeastern Spine Institute
1106 Chuck Dawley Blvd.
Mount Pleasant, SC 29464
843-849-1551

# FINAL REPORT

**Patient:** Victor Benjamin

**Patient Phone:** --

**SSN:**

**Patient #:**

**Exam Date:** 5/15/2014

**Exam Name:** Lumbar

**Modality:** MRI

**Referring Doctor:** Poletti, Steven

**Clinical Information:** 52/M WITH PAIN IN RT LEG SINCE 2011, PROGRESSIVELY WORSE SINCE 2014. NO RECENT TRAUMA. HT:6'0" WT:185LBS

**TECHNIQUE:** The patient is examined on the High Field GE Horizon LX High Speed MR System . A phased array coil is used to obtain high resolution images of the lumbar spine. **SERIES:** 1) COR, T1, SE, 7 mm; 2) SAG, Proton, FSE, 3 mm; 3) AX, Oblique, Proton, T2, FSE, 3 mm; 4) AX, T1, SE, 5 mm. 5) AX, Proton, FSE, 4 mm.; **ADDITIONAL SEQUENCES:** 1) MR myelotomography. **3D REFORMATIONS:** 1)COR-OBL,T2FSE/FS, 20mm MIPS. 2) SAG-OBL reformations both right and left.

**SEDATION:** Oral Valium = 15 mg Dramamine = 50 mg
Sedation was administered for the control of anxiety and patient comfort.

**OVERVIEW:** Overview of the lumbar spine shows normal bony alignment and normal marrow signal apart from Modic changes with no evidence of a congenital anomaly of the spine. The visualized paraspinal soft tissues are unremarkable. Images of the hips, sacroiliac joints, piriformis muscles and proximal sciatic nerves reveal no abnormality.

**THORACIC SPINE:** Views of the distal thoracic spine show a normal spinal cord and conus medullaris, normal vertebrae and mild noncompressive spondylosis.

**INTERVERTEBRAL DISCS:**
**L1-2, L2-3, L3-4, L5-S1.** Mild noncompressive spondylosis.

**L4-5.** Moderate facet arthropathy and a diffuse shallow protrusion. There is a moderately severe bilateral lateral recess stenosis.

**3D REFORMATIONS AND MYELOTOMOGRAPHY:** MR myelotomography is a 3D sequence which displays the distribution of cerebral spinal fluid within the lumbar subarachnoid space and simulates an x-ray myelogram without spinal injection. Multiple oblique projections were performed and confirm the findings set out above.

**Opinion:** MRI of the lumbar spine including 3D myelotomographic images and multiplanar reformations shows spondylosis with potential bilateral root compression at L4-5

| | |
|---|---|
| Patient: | Victor Benjamin |
| Patient #: | 066000 |
| Exam Name: | Lumbar |
| Exam Date: | 5/15/2014 |

Richard C. Holgate, MD
DISC Radiologists
1341C Old Georgetown Road - Mount Pleasant, SC 29464
(843) 884-8095 - (800) 898-1294 - Fax (843) 856-7312

SSI SPINE INSTITUTE

## STATUS / PROGRESS REPORT OF ILLNESS / INJURY

Date: 5/15/2014

Employee Name: Victor Benjamin DOB:

Physician: Steven Poletti

Work Related? ☐ Yes ☐ No ☐ Indeterminate at this time

### Work Status

- ☑ Cannot work
- ☐ Return to work immediately
- ☐ Released from office
- ☐ PPI assessed
- ☐ Return to work with modified duties
- ☐ Modified duties effective until return visit
- ☐ These restrictions are permanent
- ☐ Do not return to work until

### Work Restrictions

Upper Extremity ☐ Right ☐ Left

- ☐ No use of affected extremity
- ☐ No firm gripping
- ☐ Must wear sling/cast
- ☐ No outward wrist position
- ☐ No lifting over lbs:
- ☐ No repetitive motion
- ☐ No vibratory tools
- ☐ No overhead work (above shoulder)
- ☐ No commercial driving

Lower Extremity ☐ Right ☐ Left

- ☐ Seated work only/mainly
- ☐ No squatting/kneeling/twisting
- ☐ No climbing stairs/ladders
- ☐ No prolonged standing or walking
- ☐ Work with brace/cast
- ☐ No lifting over lbs.
- ☐ Elevate when possible/continuous
- ☐ Crutches/cane/walker
- ☐ No twisting, pushing, pulling

Other Appropriate Duties / Comments:

If no job is available with the stated modified duties, consider Victor Benjamin to be off work.

Special Instructions:

Out of work. He is permanently disabled.

SOUTHEASTERN SPINE INSTITUTE
1105 Chuck Dawley Blvd., Suite 200 ■ Mt. Pleasant, SC 29464

Patient Name: Victor Benjamin  Encounter Date: 5/22/2014  Date of Birth:
Account Number:

Mr. Benjamin returns with the updated lumbar MRI scan today, which shows disc disruption with right sided protrusion at L4-5. There's slight disc-signal loss at L3-4. The lowest segment at L5-S1 appears to be sacralized. The report is reviewed, which shows evidence of facet arthropathy with a shallow protrusion noted on the report itself. There's root compression bilaterally.

I went over the MRI images with Mr. Benjamin. We discussed the continued pain into his back and right leg. He continues to have chronic neck pain and reports no changes here.

We have discussed the potential for an epidural injection on the right at L4-5, but Mr. Benjamin has some concern as he has a family history of diabetes. He's changing his primary care doctor and will have updated labs obtained; if these check out, we may consider going ahead with the epidural injection.

His cervical spine is stable. No changes to his exam are seen.

**Diagnosis Codes:**
722.81 POSTLAMINECTOMY SYND CERVICAL
722.10 DISPLACED LUMBAR INTERVERT DISC

**Impression:** Cervical pain.
Disc herniation.

**Treatment Plan:** Mr. Benjamin has been recovering from his cervical surgery. He is still utilizing the collar. His x-rays show adequate position of the interbody graft, no further collapse. He is medically stationary. He has an MRI of his low back demonstrating stenosis with disc protrusion at L4-5 and I believe this is most likely contributing to his symptoms. He is off duty. He has continued utilizing the cane and brace. He may be a candidate for an injection in his back. He is going to follow up in one month.

Patient to return in 1 month for follow up.

Seen By: Steven C. Poletti, MD

Date:5/27/2014

DIGITALLY SIGNED Steven C. Poletti, MD
6/10/2014

SCP/JS/js/sk

DIGITALLY SIGNED Steven C. Poletti, MD
6/10/2014

1106 Chuck Dawley Blvd., Suite 200 ■ Mt. Pleasant, SC 29464

Patient Name: Victor Benjamin  Encounter Date: 7/10/2014  Date of Birth:
Account Number:

Mr. Benjamin returns for a follow-up visit today.

He's had AP and lateral views of the cervical spine, which show continued evidence of a posterior fusion and appropriate positioning of the posterior instrumentation. The previous anterior fusion construct is stable and unchanged.

He had surgery in February, which included posterior cervical decompression and fusion for severe cervical stenosis and cervical myelopathy.

He continues to have neck pain. He has pain in the back of his head and neck. He has shoulder pain and pain in between his shoulders. He denies any worsening radiating symptoms but continues to have pain and numbness into his arms and hands, which is more generalized. He also has back pain. He has right sided hip and leg pain. He continues to have evidence of a disc herniation on the right at L4-5.

His exam continues to show loss of motion in the cervical spine. Paracervical trapezius guarding noted.

He continues to use the collar around the clock. We discussed potentially weaning out of the collar at this time and he's in agreement with this.

With regards to his lumbar spine, we discussed the potential for an epidural injection and I think this is reasonable, as he's really not done any focused treatment for this problem.

His exam shows positive straight leg raising and subjective dysesthesias in the right lower extremity. No worsening focal neurologic deficit is detected.

He's in agreement with the plan with regards to his cervical and lumbar spine. We will continue to monitor his cervical issues. We will have him start weaning out of the collar. We will have him do the epidural injection at L4-5 and see how he responds with this. We will see him back in the next one month and at that time we will discuss further long term treatment options with regards to his cervical and lumbar spine.

**Diagnosis Codes:**
722.81 POSTLAMINECTOMY SYND CERVICAL
722.10 DISPLACED LUMBAR INTERVERT DISC

**Impression:** Cervical pain.
Disc herniation.

**Treatment Plan:** Lumbar epidural steroid injection was ordered. Patient to return in 1 month for follow up.

DIGITALLY SIGNED Justin P. Swain, PA
7/30/2014

**Patient Name:** Benjamin, Victor
**Account number:**
**DOB:**
**Encounter Date:** 7/10/2014

Seen By: Justin P. Swain, PA

sk 7/16/14

X-Ray Report:
X-Rays: He's had AP and lateral views of the cervical spine, which show continued evidence of a posterior fusion and appropriate positioning of the posterior instrumentation. The previous anterior fusion construct is stable and unchanged.

DIGITALLY SIGNED Justin P. Swain, PA
7/30/2014

**Southeastern Spine Institute ASC**
**Mt Pleasant – Chuck Dawley**

Patient: Beniamin, Victor Date: July 10, 2014
ID: #
DOB:

Physician: G. Robert Richardson, M.D.

Preoperative Diagnosis: Lumbar disc displacement.

Postoperative Diagnosis: Lumbar disc displacement.

Operation: Right L4-5 Lumbar Epidural Steroid Injection

Procedure Note:

After informed consent was obtained from the patient, and IV placed, the patient was taken to the Block Suite and placed prone on the fluoroscopy table. Conscious sedation obtained using IV Versed. Under fluoroscopy the appropriate sites of injection were identified and the overlying skin marked. The area was then prepped and draped in the usual sterile fashion. The skin and subcutaneous tissues were anesthetized with 1% Lidocaine. A 3.5 inch, 17 gauge Tuohy needle was advanced to the appropriate interspace. The epidural space was reached utilizing loss of resistance technique. Correct positioning was confirmed under fluoroscopy with 1 cc Isovue contrast dye (200 mg/mL iodine) with good epidural flow. Aspiration was negative for blood and CSF. Then a solution of 2 cc normal saline and 160 mg of methylprednisolone was injected.

Vital signs were monitored including blood pressure, pulse, and $0_2$ saturation prior to, during, and after the procedure. The patient tolerated the procedure well without complications and was discharged without incident.

G. Robert Richardson, M.D.

GRR/jbb
T: 07/11/2014

CC: G. Robert Richardson, M.D

1106 Chuck Dawley Blvd., Suite 200 ■ Mt. Pleasant, SC 29464

## BLOCK SUITE ORDER FORM

Name: **Victor Benjamin**
DOB: /

Home Phone: **(803) 428-3352**
Work Phone:

Date: **7/10/2014**
ACCT #:

### Procedure Information:

Procedure: 62311 LESI L4/5 Right

Diagnosis: 722.81 POSTLAMINECTOMY SYND CERVICAL
722.10 DISPLACED LUMBAR INTERVERT DISC

Procedure Date: 7/10/14 Time: add don

Physician:

Blood Thinners: ☐ Yes ☑ No

If yes, Type of Blood thinner:

Special Instruction/Notes:

Electronically signed by: Justin P. Swain, PA
Date:7/10/2014

1106 Chuck Dawley Blvd.
Mt. Pleasant, SC 29464
(843) 849-1551

1105 Chuck Dawley Blvd., Suite 200 # Mt. Pleasant, SC 29464

Patient Name: Victor Benjamin  Encounter Date: 8/14/2014  Date of Birth:
Account Number

**History of Present Illness:** Mr. Benjamin is seen today for a 1 month follow-up appointment. He is approximately 6 months status post cervical fusion at the C3-4 level. He is fused from C-4 through C-7 which was done previously. He is someone who continues to have neck and low back pain. He had a right sided L4-5 LESI done July 10, 2014. He states this seemed to exacerbate the pain for approximately 2 weeks. He then started feeling some slight improvement. He has good days and bad days. He continues to have right sided back pain that radiates through his right buttock and leg. He has had issues with balance as of late and is using a cane for ambulation. He denies any bowel or bladder disturbance, any paralysis. He continues to require pain medication which he gets from another provider.

He has weaned out of his cervical collar at this point in time. He does continue to wear this when driving or when his neck muscles feel fatigued. He has been doing well otherwise without the collar. He has neck pain and shoulder pain. He continues to experience numbness into his hands.

**Past Medical History:** High Cholesterol (272.0 ), Hypertension 401.9 (401.9 ), headaches

**Current Medications:** NuLYTELY with Flavor Packs 420 gram Oral Solution SolR, metoclopramide 10 mg tablet Oral, Norco 10 mg-325 mg tablet 2 by mouth as directed 30 min prior to MRI, Valium 5 mg tablet 3 by mouth as directed 30 minutes before MRI, pravastatin 40 mg tablet Oral, clonazepam 2 mg tablet Oral, Valium 10 mg tablet 1 by mouth TID prn spasms, oxycodone 10 mg tablet 1-2 by mouth prn pain, hydrocodone 10 mg-acetaminophen 325 mg tablet Oral, doxycycline hyclate 100 mg capsule Oral, diazepam 5 mg tablet Oral, ciprofloxacin 0.3 % Eye Drops Opht, amlodipine 5 mg tablet Oral, amoxicillin 500 mg-potassium clavulanate 125 mg tablet Oral, CIPRODEX 0.3 %-0.1 % Ear Drops, Susp DrpS Otic, fluticasone 50 mcg/actuation Nasal Spray, Susp SpSn Nasl

**Drug Allergies:** Demerol

**Imaging:** AP/lateral views of his cervical spine were reviewed with him today. There is appropriate positioning of the screws at the C3-4 level. There is evidence of solid fusion at the C-4 through C-7 level. He did have an updated lumbar MRI scan that shows disc disruption and right sided disc protrusion at the L4-5 level. He has a sacralized segment at L5-S1. There is loss of signal at the L3-4 level.

**Diagnosis Codes:**
722.81 POSTLAMINECTOMY SYND CERVICAL
722.10 DISPLACED LUMBAR INTERVERT DISC

**Treatment Plan:** His x-rays are stable. He is to continue with off duty status. We will keep a close eye on him regarding his neck and low back. We discussed the possibility of him seeing a physical therapist to work on balance and gait. This is something he could potentially benefit from. We will see him back in the office in 1 month's time for re-

**DIGITALLY SIGNED Lane Tuggle, PA-C**
**9/18/2014**

Patient Name: Benjamin, Victor
Account number:
DOB
Encounter Date: 8/14/2014

evaluation. We discussed that if he were to have any worsening pain or changes in his symptoms he will contact our office for a sooner appointment. Otherwise we will see him in 1 month for updated cervical x-rays.The patient is instructed to call us if pain persists or get worse. Patient to return in 1 month for follow up.

Seen By: Lane Tuggle, PA-C

LT/dam

X-ray: AP/lateral views of his cervical spine were reviewed with him today. There is appropriate positioning of the screws at theC3-4 level. There is evidence of solid fusion at the C-4 through C-7 level.

DIGITALLY SIGNED Lane Tuggle, PA-C
9/18/2014

**Southeastern Spine Institute ASC**
**Mt Pleasant – Chuck Dawley**

Patient: Benjamin, Victor Date: October 2, 2015
ID: #
DOB:

Physician: Leonard E. Forrest, M.D.

Preoperative Diagnosis: Disc disruption.

Postoperative Diagnosis: Disc disruption.

Operation: Right L4-5 Lumbar Epidural Steroid Injection

Procedure Note:

After informed consent was obtained from the patient, and IV placed, the patient was taken to the Block Suite and placed prone on the fluoroscopy table. Conscious sedation obtained using IV Versed. Under fluoroscopy the appropriate sites of injection were identified and the overlying skin marked. The area was then prepped and draped in the usual sterile fashion. The skin and subcutaneous tissues were anesthetized with 1% Lidocaine. A 3.5 inch, 17 gauge Tuohy needle was advanced to the appropriate interspace. The epidural space was reached utilizing loss of resistance technique. Correct positioning was confirmed under fluoroscopy with 1 cc Isovue contrast dye (200 mg/mL Iodine) with good epidural flow. Aspiration was negative for blood and CSF. Then a solution of 2 cc 1% Lidocaine and 80 mg of methylprednisolone was injected.

Vital signs were monitored including blood pressure, pulse, and $O_2$ saturation prior to, during, and after the procedure. The patient tolerated the procedure well without complications and was discharged without incident.

Leonard E. Forrest, M.D.

LEF/jbb
T: 10/07/2015

CC: Leonard E. Forrest, M.D.

1105 Chuck Dawley Blvd., Suite 200 ■ Mt. Pleasant, SC 29464

Patient Name: Victor Benjamin  Encounter Date: 11/20/2014  Date of Birth:
Account Number:

Mr. Benjamin returns for a follow-up visit today. He's had AP/lateral views of his cervical spine, which show appropriate position of the posterior instrumentation at C3-4. His previous anterior fusion site is stable.

Mr. Benjamin has had continued issues with neck pain. He notices it more on the right side. He continues to have right arm pain, which has flared up recently. He continues to have numbness in his hands. He has burning into his hands. He has continued hand myelopathy signs seen. He has difficulty sitting in one position in the chair in the office. He has limited motion in his cervical spine. He continues to have issues with ADLs and fine manipulation with his hands.

**Imaging Orders:**
AP and Lateral views of the cervical spine were ordered, obtained and interpreted from an orthopedic standpoint.
**Diagnosis Codes:**
722.81 POSTLAMINECTOMY SYND CERVICAL
722.10 DISPLACED LUMBAR INTERVERT DISC

**Treatment Plan:** He continues to have chronic pain and limitations overall. His exam has been outlined. He has had no significant changes with his overall condition. We discussed some further long-term pain management options if needed. We may potentially set up a referral to a pain management doctor depending on his progression of symptoms over time. Currently his condition is unchanged, and I recommend he follow up with us in the next two months' time.

Patient to return in 2 months for follow up.

Justin P. Swain, PA

JPS/dmp

X-rays: He's had AP/lateral views of his cervical spine, which show appropriate position of the posterior instrumentation at C3-4. His previous anterior fusion site is stable.

DIGITALLY SIGNED Justin P. Swain, PA
11/26/2014

1106 Chuck Dawley Blvd., Suite 200 ■ Mt. Pleasant, SC 29464

Patient Name: Victor Benjamin  Encounter Date: 3/19/2015  Date of Birth:
Account Number:

Mr. Benjamin is being seen today for follow up visit. He is status post posterior instrumentation of C3-4 level with previous anterior fusion status post accident while at work. We continue to monitor him. He continues to have chronic pain complaints in his right upper extremity. He describes nummbness, tingling, and upper extremity weakness, all which has not changed since last visit. He does still have burning into his right hand and myelopathic sign seen. He has difficulty with some ADLS and fine motor movements involving hands. He is requiring Norco 2-3 times daily for pain control which is provided by his PCP, Dr. Belmor. He states he has had a 20 pound weight loss in the past two months which is unintentional. This is being worked up by his PCP. He denies any fever, chills, night sweats, cough, recent hospitalization.

On physical exam he is alert and oriented x 3 with an appropriate affect. He has decreased strength on the right compared to the left with shoulder abduction, tricept extension, wrist flexion. Negative Hoffman sign. He is ambulating with cane.

Xrays of the cervical spine were obtained and reviewed today and compared to previous films in January. He has stable implementation at the posterior C3-4 level. Previous anterior fusion C4-7 is also stable and unchanged.

**Diagnosis Codes:**
723.4 Cervical Radiculitis

**Treatment Plan:** Mr. Benjamin continues to have chronic pain and functional limitations. Overall his xrays and physical exam are unchanged. He is to undergo EMG and MRI with Dr. Sandalls which I would like to follow up with. I have written prescription for Brown's cream today for adjunct pain relief. He will follow with us in the office in 3 months. I have advised him to call sooner with any concerns. Patient to return in 3 months for follow up.

Justin Swain, PAC

DIGITALLY SIGNED Justin P. Swain, PA
3/24/2015

SOUTHEASTERN SPINE INSTITUTE

MAIN CAMPUS
1106 Chuck Dawley Blvd.
Mt. Pleasant, SC 29464

1122 Chuck Dawley Blvd.
Mt. Pleasant, SC 29464

(843) 849-1551
Fax (843) 884-0629
1-800-432-0274

SPINAL SURGERY
Donald R. Johnson, II, MD
Steven C. Poletti, MD
R. Blake Dennis, MD
Richard F. Frisch, MD
Daniel R. Butler, PA-C
Justin C. Swain, PA-C
Courtney E. Bock, PA-C
G.Ryan Aprill, PA-C
Kelly Eddinger, PA-C

CONSERVATIVE SPINE CARE
Leonard E. Forrest, MD
John F. Johnson, MD
G. Robert Richardson III, MD
Kirsten W. Loeffler, PA-C
Carolyn Hyatt, PA-C
Meghan Patton, PA-C

PAIN MANAGEMENT
Mark D. Netherton, MD
W. Blane Richardson, MD
Virginia G. Blease, PA-C
Kathleen L. Bukowsky, PA-C
Christina Chandler, PA-C

AFFILIATED PHYSICIANS

NEURORADIOLOGY
Richard C. Holgate, MD.

NEUROLOGY-INTRAOPERATIVE NEUROMONITORING
George "Trey" Lee, MD

VASCULAR SPINE ACCESS SURGERY
Thomas C. Appleby, MD

Date: 5/27/2015
Re: Victor Benjamin
DOB:
MR:

Jeffrey C. Chandler, P.C.
Chandler Law Firm
P.O. Drawer 1889
Myrtle Beach, SC 29578-1889

Dear Mr. Chandler:

I first saw Mr. Benjamin at the request of Dr. Sandoz in November of 2012. He had severe spinal stenosis at the C3-4 level after an accident, which rendered him unconscious. He has obvious spinal cord compression and bruising of the spinal cord or myelomalacia. It was recommended that he consider surgical intervention; and he was ultimately sent to Dr. Lozanne where he had surgery at C4-5, C5-6, and C6-7 but did not have surgery at C3-4. He developed progressive spondylosis or disc space collapse at the C3-4 level with worsening of stenosis at the C3-4 level but more importantly continued presence of spinal cord edema or bruising. On his physical examination, he was developing progressive loss of use of his upper extremities with an altered gait and imbalance.

I saw Mr. Benjamin on 1/21/12 with the MRI scan showing the edema within his spinal canal and believed that he should consider surgery, and I felt absolutely that he should not do any type of therapy and that surgery was mandatory. He underwent the operative intervention on what I would describe as an urgent basis in February of 2014 to involve posterior cervical decompression and fusion. Dr. Lozanne saw the patient, and I received records from him noting that he saw myelomalacia or spinal cord edema at the C3-4 level. Dr. Lozanne did state that the spinal cord itself "looked to have been damaged to some degree at the C3-4 level".

I would invite really any neurosurgeon or neuroradiologist to review the MRI scan from January 20, 2014; and I think it would be obvious that there is severe stenosis at the C3-4 level. When comparing the stenosis with spinal cord compression at the C3-4 level on the MRI scan from January 20, 2014 compared to the MRI scan from October 15, 2012, it is clearly worse at the adjacent level after the fusion. I would describe his problem as obviously surgical and obviously

urgent. I honestly don't know of anyone who would feel different in terms of worsening cervical stenosis with spinal cord compression and evidence of myelomalacia. Apparently there is some determination by the Workman's Compensation Commission that operative intervention was either not urgent or necessary in 2014. I would respectfully opine that I don't know of a spinal surgeon who would have that opinion.

Suffice it to say this man had a serious or catastrophic neurologic injury. He has signs and symptoms of upper and lower extremity weakness. This type of spinal cord edema or compression is what commonly would be referred to as incomplete quadriparesis or as a form of incomplete quadriplegia. He has a disabling problem that will prevent him from walking normally or using his hands normally for fine motor activities. He is obviously permanently disabled from returning to any type of employment and meets what I would describe as the necessary criteria for pursuing Social Security disability.

With regards to the urgency of the clinical situation for Mr. Benjamin, when you have spinal stenosis of this severity with edema or bruising in the spinal cord, if you don't decompress the stenosis the patient's symptoms will get worse. Again, I would invite this man's imaging studies and clinical records to be reviewed by any other spinal or neurosurgeon; and I'm confident that their opinion would match mine with regards to the urgent nature of the surgery and its absolute necessity.

Specifically with regards to impairment, Mr. Benjamin has undergone a multilevel fusion operation. Specific impairment would be due to alteration of motion-segment integrity requiring fusion. This would be per DRE Cervical Category IV. He would have a 28-percent impairment rating.

With regards to impairment in addition from the spinal cord injury as both I and Dr. Lozanne have described, he has additional impairment not only from the fusion but from the myelomalacia or spinal cord compression. He has station and gait disorders and impairment to both his upper and lower extremity. He is limited to level surfaces of walking and has criteria for impairment due to station and gait disorder, and he does not have digital dexterity in his hands as a consequence of the injury. Impairment with regards to whole-person impairment, which is in addition for criteria of impairment for the upper extremities, is per table 15-6, page 396 of the AMA Guides for Permanent Impairment Fifth Edition. This would be an additional 39-percent whole-person impairment rating and is added to the previous impairment. Therefore, his total numerical impairment is 67 percent to the whole person.

Again, this man has a form of spinal cord injury or incomplete quadriplegia, and this is the rationale behind him having this level of disabling impairment and injury. Again, my opinions are held to a reasonable degree of medical certainty. I would be glad to see him back at any time.

Sincerely,

Steven C PolettiMD

SCP/dmp

South Carolina Workers' Compensation Con ion
1333 Main Street, Suite 500 ▪ Post Office Box 1715
Columbia, South Carolina 29202-1715
(803) 737-5723
www.wcc.sc.gov

#666600

# Physician's Statement

Claimant's Name: Victor Benjamin

Physician's Name: Dr. Steven Poletti

Practice/Clinic: Southeastern Spine Institute

Preparer's Name: Dr. Steven Poletti

Phone: (843) 849-1551

Employer's Name: Rexam Beverage Can Company DBA Rexam Beverages

Insurance Carrier: Hartford Insurance Co of the Midwest

SCWCC File No: 1106789

The undersigned physician has been authorized by the Employer/Carrier to treat this Claimant for his or her injury by accident pursuant to**§§42-15-60, 42-1-172 or 42-11-10.**

**Date of Injury or Illness:** 01-24-2011

Date of first office visit: 11-5-2012 Date of last visit: 11-20-2014

Diagnosis or nature of injury or illness: Cervical post laminectomy syndrome
Lumbar disc displacement

Body part(s) injured: Cervical + lumbar spine Body part(s) affected: cervical + lumbar spine

Date of **Maximum Medical Improvement:** _____

Based on the **AMA Guidelines**, the claimant has sustained a 28 **% medical impairment** to cervical spine part(s) and a 67 **% medical impairment** to whole person injured body other affected body part(s).

____ The claimant is **able to return to work** without restriction.

____ The claimant is **able** to return to work **with the following restrictions:** 39% for spinal cord injury plus 28% for cervical fusions

X The claimant is **unable to return to work** at his or her current employment.

As of the date I last saw this patient, it is **my professional medical opinion** the claimant:

____ **will not** need future medical care related to his or her work related injury or illness based on a reasonable degree of medical certainty (more likely than not).

✓ **will** need future medical care and treatment related to his or her work related injury or illness based on a reasonable degree of medical certainty (more likely than not) and that medical care and treatment including medication is as follows:

pain management

**Treating Physician** Steven C. Poletti, MD

**Date** 5/27/16

1106 Chuck Dawley Blvd., Suite 200 ■ Mt. Pleasant, SC 29464

Patient Name: Victor Benjamin  Encounter Date: 6/26/2015  Date of Birth:
Account Number:

Mr. Benjamin is being seen is being seen for follow-up visit. He has previous surgical history of C4-5 anterior fusion as well as a secondary C3-4 posterior fusion with bilateral screw fixation. He has had a difficult course and we continue to monitor him in addition to him being seen by Dr. Sandalls for neck and back pain. He underwent EMG/NCS of the upper extremity and MRI with Dr. Sandalls since his last visit with us and was told that he had some degree of chronic radiculopathy in the right upper extremity. We do not have this report available today. He is in the process of obtaining approval for lumbar MRI and potential LESI with Dr. Sandalls. He feels that his pain in his lumbar spine has worsened since his last visit and he has been followed appropriately with Dr. Sandalls. He continues to require pain medication and the use of a cane for assistance with ambulation on a daily basis. He denies any change in distribution of his symptoms. He denies any bladder or bowel dysfunction. He underwent a colonoscopy and upper endoscopy secondary to unintentional weight loss since his last visit. Both tests were inconclusive however he has started to regain some of his weight. He denies any fevers, chills, shortness of breath or chest pain.

He is alert and oriented x 3 with an appropriate affect. He uses the assistance of a cane for ambulation. He has 4/5 strength bilaterally with hip abduction, hip adduction, hip flexion, knee extension, ankle plantar and dorsiflexion and great toe extension. He has diminished patellar and achilles deep tendon reflexes bilaterally.

**Diagnosis Codes:**
723.4 Cervical Radiculitis

**Treatment Plan:** We will continue to follow Mr. Benjamin for his pain complaints and limitations. He will also continue to follow with Dr. Sailors who is managing his back issues and pain medications. He will return with results from his Lumbar MRI and lower extremity EMG/NCS at his next visit. He will call sooner with any concerns. Patient to return in 3 months for follow up. The patient is instructed to call us if pain persists or get worse.

Kimsey Cooper, PA-C

DIGITALLY SIGNED Kimsey Cooper, PA-C
6/26/2015

1106 Chuck Dawley Blvd., Suite 200 ■ Mt. Pleasant, SC 29464

Patient Name: Victor Benjamin  Encounter Date: 10/2/2015  Date of Birth:
Account Number:

CC: Follow up neck and right upper extremity pain, low back and right lower extremity pain.

HPI: Mr. Benjamin presents today, accompanied by his wife, for follow up evaluation. He is someone we continue to follow for complaints of chronic neck pain with radiation into the right upper extremity, as well as low back pain with radiation into his right hip. He has previous surgical history of C4-7 done at an outside facility with posterior fusion of C3-4 done by Dr. Richard Frisch and Dr. Steven Poletti in February, 2014. His is a difficult situation as he reports chronic radiculopathy of the right upper extremity after undergoing an EMG with his pain management physician Dr. Sandoz. He states he is considering a possible cervical rhizotomy and remains stable with regards to his cervical spine. He also has chronic low back pain with radiation into his right buttock and posterolateral hip. He previously underwent a right L4-5 LESI 7/10/2015 and states this helped his pain. He states that his pain in his lower extremity seems to be worsening and he feels subjective weakness when ascending stairs. He denies any focal muscle deficits, paralysis, or changes in bowel and bladder function.

Imaging: AP and lateral lumbar plane Films were obtained and reviewed with him today. They show evidence of diffuse lumbar spondylosis with degeneration at the L5-S1 level and facet arthropathy. These are compared with his previous images from 5/15/2014 And appear relatively stable. We have also reviewed cervical plain films which the patient brought with him today. They show appropriate positioning of posterior instrumentation at the C3-4 level. His previous fusion site appear stable.

Physical exam: He is well-developed, well-nourished, 53-year-old male who is alert and oriented ×3 and in no acute distress. He is ambulatory with slightly antalgic gait using the assistance of a cane primarily for fall prevention. Strength of the lower extremity is 5/5 with hip flexion, ankle dorsi flexion and 4/5 with knee flexion, knee extension, plantar flexion bilaterally. Positive straight leg raise on the right, negative on the left. Negative Hoffman's sign. Strength of the upper extremity is intact. Restricted, painful, cervical range of motion.

**Diagnosis Codes:**
M54.12 Radiculopathy, cervical region
M47.27 Other spondylosis with radiculopathy, lumbosacral region

**Treatment Plan:** Greater than 15 minutes of face to face time was spent with Mr. Benjamin and his wife discussing his current pain complaints, updated imaging, and plan of care. Recommendation today is for an updated lumbar MRI scan in order to evaluate his neurologic structures given his persistent and increasing pain. We will also place an order for a right L4-5 years thigh as he has historically done well with this and present with similar symptoms. This is to be completed at his convenience. With regards to cervical spine he does remain stable and he is to continue to follow up with Dr. Sandoz for further pain management. He is to return for follow-up evaluation in 3 months time or on completion of his lumbar MRI scan. He is instructed to contact our office if his symptoms progress or worsen in any way.Lumbar epidural steroid injection was ordered. An MRI of the lumbar spine was ordered. The scan will need to

**DIGITALLY SIGNED Anne E. Buck, PA-C**
**10/2/2015**

**Patient Name:** Benjamin, Victor
**Account number:**
**DOB:**
**Encounter Date:** 10/2/2015

Include 3-D reformations to evaluate for any potential extraforaminal herniations as well as anticipation of injection therapy or surgical intervention. The patient is instructed to call us if pain persists or get worse. Patient to return in 3 months for follow up. The patient is to return when the result of MRI is available.

Anne E. Buck, PA-C

DIGITALLY SIGNED Anne E. Buck, PA-C
10/2/2015

1106 Chuck Dawley Blvd., Suite 200 N Mt. Pleasant, SC 29464

## BLOCK SUITE ORDER FORM

Name: **Victor Benjamin**
DOB:

Home Phone: **(803) 428-3352**
Work Phone:

Date: **10/2/2015**
ACCT #:

### Procedure Information:

Procedure: 62311 LESI L4-5 Right

Diagnosis: M54.12 Radiculopathy, cervical region
M47.27 Other spondylosis with radiculopathy, lumbosacral region

Procedure Date: 10/2/15 Time: addon

Physician: Dr Netherton

Blood Thinners: ☐ Yes ☑ No

If yes, Type of Blood thinner:

Special Instruction/Notes:

Anne E. Buck PA-C

Electronically signed by: Anne E. Buck, PA-C
Date: 10/2/2015

1106 Chuck Dawley Blvd.
Mt. Pleasant, SC 29464
(843) 849-1551

1106 Chuck Dawley Blvd., Suite 200 B Mt. Pleasant, SC 29464

Patient Name: Victor Benjamin  Encounter Date: 10/19/2015  Date of Birth:
Account Number:

Mr. Benjamin is seen in follow-up. He has lumbar spinal stenosis with posterior disc protrusion at the L4-5 level. I've addressed this issue in a separate dictation documenting the medical necessity for treatment related to his low back. Mr. Benjamin's situation is a difficult one in that he has corticospinal tract injury from disc herniation and has continued signs of spasticity. It is my strong belief that he is totally and permanently disabled from returning to any form of work. I do think that surgery on his low back is a possibility but something that I would try to avoid. I think that repeating the injection would be reasonable. I think continued nonoperative care with pain management to include Dr. Sandoz is a reasonable long-term option for him.

**Diagnosis Codes:**
M54.12 Radiculopathy, cervical region
M47.27 Other spondylosis with radiculopathy, lumbosacral region

**Treatment Plan:** He is going to follow up with me in three months' time.

Patient to return in 2 months for follow up.

Steven C. Poletti, MD

SCP/dmp

**DIGITALLY SIGNED Steven C. Poletti, MD**
**11/12/2015**

Richard C. Holgate, M.D.

The Southeastern Spine Institute
1106 Chuck Dawley Blvd.
Mount Pleasant, SC 29464
843-849-1551

# FINAL REPORT

**Patient:** Victor Benjamin
**Patient Phone:** –
**SSN:**
**Patient #:**

**Exam Date:** 10/19/2015
**Exam Name:** Lumbar
**Modality:** MRI
**Referring Doctor:** Poletti, Steven

**Clinical Information:** M/53 WITH LOW BACK AND RIGHT LEG PAIN FOR FOUR YEARS. NO RECENT TRAUMA. HT-6'0" WT-171 LBS.

**TECHNIQUE:** The patient is examined on the High Field GE Horizon LX High Speed MR System . A phased array coil is used to obtain high resolution images of the lumbar spine. **SERIES:** 1) COR, T1, SE, 7 mm; 2) SAG, Proton, FSE, 3 mm; 3) AX, Oblique, Proton, T2, FSE, 3 mm; 4) AX, T1, SE, 5 mm. 5) AX, Proton, FSE, 4 mm.; **ADDITIONAL SEQUENCES:** 1) MR myelotomography. **3D REFORMATIONS:** 1)COR-OBL,T2FSE/FS, 20mm MIPS. 2) SAG-OBL reformations both right and left.

**OVERVIEW:** Overview of the lumbar spine shows normal bony alignment and normal marrow signal apart from Modic changes with no evidence of a congenital anomaly of the spine. Images of the hips, sacroiliac joints, piriformis muscles and proximal sciatic nerves reveal no abnormality.

**THORACIC SPINE:** Views of the distal thoracic spine show a normal spinal cord and conus medullaris, normal vertebrae and mild noncompressive spondylosis.

**INTERVERTEBRAL DISCS:**
**L1-2, L2-3.** Mild noncompressive spondylosis.

**L3-4.** Mild facet arthropathy, signal loss and a minimal bulge but no sign of root compression.

**L4-5.** Moderate facet arthropathy, signal loss and a diffuse shallow protrusion of disc. There is moderate to severe bilateral lateral recess stenosis (see myelogram).

**L5-S1.** Mild noncompressive spondylosis.

**3D REFORMATIONS AND MYELOTOMOGRAPHY:** MR myelotomography is a 3D sequence which displays the distribution of cerebral spinal fluid within the lumbar subarachnoid space and simulates an x-ray myelogram without spinal injection. Multiple oblique projections were performed and confirm the findings above.

**Opinion:** MRI of the lumbar spine including 3D myelotomographic images and multiplanar reformations shows spondylosis with moderate to severe lateral recess stenosis and potential root compression at L4-5.

**Patient:** Victor Benjamin
**Patient #:**

**Exam Name:** Lumbar

**Exam Date:** 10/19/2015

Richard C. Holgate, MD
**DISC Radiologists**
1341C Old Georgetown Road - Mount Pleasant, SC 29464
(843) 884-8095 - (800) 898-1294 - Fax (843) 856-7312




1106 Chuck Dawley Blvd., Suite 200 ■ Mt. Pleasant, SC 29464

Patient Name: Victor Benjamin  Encounter Date: 12/17/2015  Date of Birth:
Account Number:

Mr. Benjamin is being seen today for a 2 month follow-up appointment. He has surgical history to involve posterior decompression and fusion at the C3-4 level done in 2014. He previously underwent anterior cervical discectomy and fusion at the levels below his fusion through C7 at an outside facility. We also monitor him for low back pain secondary to lumbar spinal stenosis and a posterior disc protrusion at the L4-5 level. He underwent a right-sided L4-5 epidural injection in October. He states he got good pain relief with this injection and continues to benefit from this. His main complaint today is of left-sided neck pain that radiates down his left arm. He states he noticed an increase in his pain this past Sunday. He denies any inciting incident or known trauma. He has been resting which helped some. He continues to ambulate with a cane. He was debating using his hard collar secondary to increased neck pain. He denies loss of bowel or bladder function, any focal muscle deficits, or paralysis.

He continues to be monitored by Dr. Sandoz for pain management. He also sees Dr. Saarb. He has been well-maintained with his medication.

AP and lateral views of his cervical spine were obtained and reviewed with him today. There is appropriate positioning of the instrumentation at C3-4. There is no further shifting or collapse of his previous fusion site.

We discussed generalized precautions and restrictions. He is someone who is totally and permanently disabled from returning to any form of work. I will give him a Medrol Dosepak for acute pain control of his neck. If he were to have no relief from the Medrol Dosepak we could potentially move forward with updated imaging to include an MRI scan of the cervical spine. He understands this. I will give him an order for a soft cervical collar for adjunct pain control to be used intermittently. We will see him back in the office for a routine follow-up in 3 months time for reevaluation and updated imaging. He could potentially undergo a repeat epidural injection for his lumbar spine depending on his symptoms. He'll contact our office with any further issues in the meantime.

**Imaging Orders:**
AP and Lateral views of the cervical spine were ordered, obtained and interpreted from an orthopedic standpoint.
**Diagnosis Codes:**
M54.12 Radiculopathy, cervical region
M47.27 Other spondylosis with radiculopathy, lumbosacral region

**Treatment Plan:** A Medrol Dosepak was prescribed; side effects were discussed and appropriate instructions were provided. Prescription is written for the patient to be fitted with a soft cervical collar today and begin wearing immediately for weak spinal musculature and pain reduction. This should increase the ability to preform activities of daily living while limiting further progression of disc pathology. The patient is instructed to call us if pain persists or get worse. Patient to return in 3 months for follow up.

DIGITALLY SIGNED Lane Tuggle, PA-C
1/20/2016

# Southeastern Spine Institute

## PATIENT INFORMATION

| | |
|---|---|
| Name: Victor Benjamin | Patient Number: |
| Address One: 1841 Holman Rd | SSN: |
| Address Two: | Date of Birth: 04/19/1962 |
| City: Sumter | Sex: M |
| State: SC County:43 | Ethnicity:African American |
| Zip: 29153 | Emergency Phone#: |
| Home Phone#: (803) 428-3352 | Emergency Contact: |
| Work Phone#: | Employer: |
| Cell Phone#: (803) 316-6766 | Referring Doctor:Sandoz, George |

## GUARANTOR INFORMATION

| | |
|---|---|
| Name: Victor Benjamin | Date of Birth: |
| Address One: 1841 Holman Rd | |
| Address Two: | |
| City: Sumter | Employer: |
| State: SC Zip: 29153 | Employer Address: |
| Home Phone#: (803) 428-3352 | Employer City: |
| Work Phone#: | Employer State: Zip: |
| Cell Phone#: (803) 316-6766 | |

## INSURANCE INFORMATION

| | |
|---|---|
| Primary Insurance: UHC | Secondary Insurance: |
| Certificate#: 835141625 | Certificate#: |
| Group Number:228776 | Group Number: |
| Group Name: | Group Name: |
| Address:Po Box 740800<br>Atlanta GA 30374-0800 | Address: |
| Subscriber Name:Victor Benjamin | Subscriber Name: |
| Workers Comp Insurance: | Certificate# |

**Authorization To Pay Benefits To Physician:** I authorize the release of medical or other information necessary to process health insurance claims. I also request payment of benefits to myself or to my Provider, when he accepts assignment.
**Authorization To Release Medical Information.** I hereby authorize my Provider, to release any information necessary for my course of treatment.

Signed (patient or parent if minor) _____ Date _____

Patient Name: Benjamin, Victor
Account number:
DOB: -
Encounter Date: 12/17/2015

Lane Tuggle, PA-C

DIGITALLY SIGNED Lane Tuggle, PA-C
1/20/2016

1106 Chuck Dawley Blvd., Suite 200 ■ Mt. Pleasant, SC 29464

Patient Name: Victor Benjamin  Encounter Date: 4/21/2016  Date of Birth:
Account Number

CC: Follow-up neck and back pain.

HPI: Mr. Benjamin returns today for 3 month follow-up evaluation. He has previous surgical history to include posterior decompression and fusion at the C3-4 level done in 2014 and previous C4-C7 fusion done at an outside facility. We also continue to monitor him for low back pain with documented evidence of posterior disc protrusion at the L4-5 level on lumbar spinal stenosis. He completed a right L4-5 LESI in October which provided substantial improvement. He has been recommended for continued conservative management. His is a difficult situation as he has a history of corticospinal tract injury he has continued spasticity in her chronic pain. He is totally and permanently disabled. At this point in time he remains relatively stable although his pain fluctuates depending on his activity. He continues to see Dr. Sandoz for pain management. He denies any significant progression of his symptoms.

He presents today with updated plain films of his cervical spine from Dr. Sandoz's office. These were reviewed with him today. I compared these with his previous images. Overall they appear stable.

Greater than 15 minutes face-to-face time was spent with Mr. Benjamin discussing his current pain complaint, updated imaging, and plan of care. He is been recommended for conservative management although he theoretically has a potential surgical indication for his lumbar spine. He is encouraged to continue with Dr. Sandoz as previously recommended and we will continue to monitor him. He is to return for follow-up evaluation in 3 months time or sooner should his symptoms dictate.

**Diagnosis Codes:**
M54.12 Radiculopathy, cervical region
M47.27 Other spondylosis with radiculopathy, lumbosacral region

**Treatment Plan:** The patient is instructed to call us if pain persists or get worse. Patient to return in 3 months for follow up.

Anne E. Buck, PA-C

**DIGITALLY SIGNED Anne E. Buck, PA-C**
**4/21/2016**

# COLUMBIA NEUROSURGICAL ASSOCIATES, P.A.

137270

Please complete this medical questionnaire. The answers to these questions are very important in helping us take care of you. Where appropriate, fill in complete answers. Thank-you for your time and patience.

Name: Victor Benjamin (M) / F (circle one) Date of Visit: 1-22-13

Age: 50 Height 60' Weight: _____ Date of Birth: _____

Referring Doctor: _____ Family Doctor: Roosevelt Daniels

1. I am ( ) right handed ( ✓ ) left handed.
2. Chief complaint or reason for visit: Serious Neck Pains, hard Pains, Arms + hand. Pains - ringing in both ears, numbness of hands, sleeping in sleep or when sitting
3. When did your symptoms first appear? After the accident 6-15-2011
4. Did you have an injury? (✓) Yes ( ) No If yes, was it work related? (✓) Yes ( ) No ( ) Other _____
5. I have been treated for this problem by: Dr. Saab - had injections Dr. Sander with medication
6. What did they do or recommend? They also recommended surgery

7. PAST MEDICAL HISTORY: List prior injuries & illnesses, conditions, medical problems that you have (ex: diabetes, high blood pressure, heart disease) Write HOSP. beside any for which you were admitted to the hospital.

| Approx. date | Reason (Give Diagnosis of problem if known) |
|---|---|
| Dec. 2007 | Twisted Ankle |

8. PAST SURGICAL HISTORY: List all surgeries, even if done as an outpatient:

| Date | Procedure |
|---|---|
| 6-17-2011 | Operated on Right Arm - repair tendons from the accident @ McLeods Hospital - Florence, SC |

9. SOCIAL HISTORY: Check box or fill in blank:
(✓) I do not use tobacco. ( ) I do use tobacco: _____ packs/per day
(✓) I do not use beer, wine or liquor. ( ) I do use beer, wine or liquor ( ) daily ( ) weekly ( ) monthly
I am (✓) married ( ) widowed ( ) divorced ( ) single Years of formal education 12th + Vocational
I have (2) children, ages: 13 + 20
I work as a Frontend Maintainer Prior to injury for Rexam for 30 yrs
(✓) I have been disabled since 6-15-2011 due to (list reason) injury @ work 6-15-11

10. FAMILY HISTORY: Please list any illness that your grand parents, parents, brothers, sisters or children have had. (for example: cancer, diabetes, heart disease, high blood pressure, stroke)

Grand Mother _____ Grand Father _____
Mother High blood Pressure Father High blood Pressures
Sister _____ Brother _____
Children Allergies

11. SYSTEMS REVIEW: Please check any that apply to you:

Constitutional: ____ Fever in last 72 hrs. ____ hot or cold spells
____ generalized weakness ✓ generalized lack of energy
____ unplanned weight loss _____ lbs over _____ months.
____ Other: _____

Eyes: ____ declining vision ✓ blurred vision ____ double vision ✓ seeing spots of light
____ black areas in field of vision ____ eye disease ( cataracts, glaucoma, etc.) _____
____ Other: _____

Ear Nose, Mouth Throat:
____ ear aches ____ decreased hearing ✓ ringing in ears both
____ frequent nosebleeds ____ chronic sinus ____ mouth ulcers
____ mouth/throat cancer ✓ voice changes or hoarseness
Other: _____

Cardiovascular:

___ chest pain ( ) sharp ( ) dull ( ) happens only when exercising
___ history of heart attack ___ heart surgery or catheterization
___ palpitations ___ heart murmur ___ heart rhythm disturbance
✓ shortness of breath ( ) happens only when exercising
___ I have a pacemaker
Other: _____

Respiratory: History of:

___ pneumonia ___ bronchitis ___ tuberculosis
___ asthma ___ emphysema ___ lung cancer
___ I cough up blood from time to time
___ Other: _____

Gastrointestinal:

___ difficulty swallowing ___ nausea/vomiting last 48hrs
___ stomach ulcers ___ heart burn
___ diarrhea ___ change in appetite
___ stomach or bower cancer ___ liver disease
___ bulimia ___ anorexia
___ hernia ___ hepatitis
Other: _____

Genitourinary:

___ frequent urinary tract infection ___ difficulty urinating ___ painful urination
___ blood in urine ___ prostate problems ___ vaginal infections
___ miscarriage ___ venereal disease : ( ) gonorrhea ( ) herpes ( ) syphilis
___ Other: _____

Musculoskeletal:

___ joints that dislocate ___ leg or ankle swelling ___ osteoporosis
___ arthritis ___ gout ___ fractures ___ polio
✓ back pain ___ leg pain ( ) right ( ) left
___ back pain is relieved completely when I lie down
___ back pain is relieved mostly when I lie down
___ Lying down does not help my back pain
✓ neck pain ( ✓ right side ( ✓ left side ( ✓ both sides
___ arm pain ( ) right ( ) left ( ✓ both

Hematologic/lymphatic:

___ bleeding disorder ___ easy bruising ___ anemia
___ tendency to form blood clots in legs ___ swollen lymph nodes
___ Aids ___ HIV

Immunologic: ___ Lupus ___ Scleroderma ___ Rheumatoid arthritis

Other:

___ chicken pox ___ measles ___ mumps ___ Mononucleosis
___ scarlet fever ___ whooping cough ___ typhoid fever ___ rheumatic fever

Integumentary:

___ skin rashes
___ skin cancer– Type: _____
___ breast disease _____

Neurological:

✓ headaches: How often daily Sharp pains ___ with nausea ___ with blurred vision
___ fainting spells ___ history of migraines
✓ confusion ✓ declining memory
✓ history of head trauma ___ history of brain tumor
___ facial numbness ✓ dizziness
___ multiple sclerosis ✓ epilepsy on medicine
✓ numbness in hands or arms ( ✓ right ( ) left ( ) both
✓ difficulty using hands ( ✓ right ( ✓ left ( ✓ both
✓ difficulty walking/numbness in legs ( ) right ( ) left ( ) both walk toward right off balance

Psychiatric: ___ I have been treated/hospitalized for:

___ schizophrenia ___ depression ___ suicide attempt
___ alcoholism ___ chemical dependency

Endocrine: ___ thyroid ___ goiter ___ diabetes

12. If you have back, leg, neck or [illegible] pain, please answer the following:
___ I have taken physical therapy in the last 6 months for this problem
✓ I have taken medicines like Motrin, Aleve, muscle relaxents or pain medicine to help relieve the pain.
✓ I have had steroid injections in my back or neck for this problem.

Rate the severity of your pain on a scale from 1 to 10, with 1 the least painful and 10 being the most severe. _____

Type of pain:
10 sharp ___ dull 7 throbbing 10 aching 10 shooting 7 burning
9 tingling 5 numbness ___ stiffness ___ swelling ___ cramps
Other: _____

✓ the pain comes and goes
___ the pain is constant

If so, how often do you have this pain? In my head the pains comes/goes About 5-8 times a day - last Sometimes over 5 minutes

Does the pain interfere with ___ work ✓ sleep ✓ daily routine ✓ recreation
Activities or movements that are painful to perform:
___ sitting ✓ standing ___ walking ✓ bending ✓ lying down
How do you sleep? ___ back ✓ side ___ stomach

13. I am claustrophobic ( fear of being in a closed/confined place ) ( ) Yes ( ) No
I have metal in my body. ( ) Yes ( ✓ ) No If yes, where? _____

14. Mark an X on the picture where you have pain, numbness or tingling.

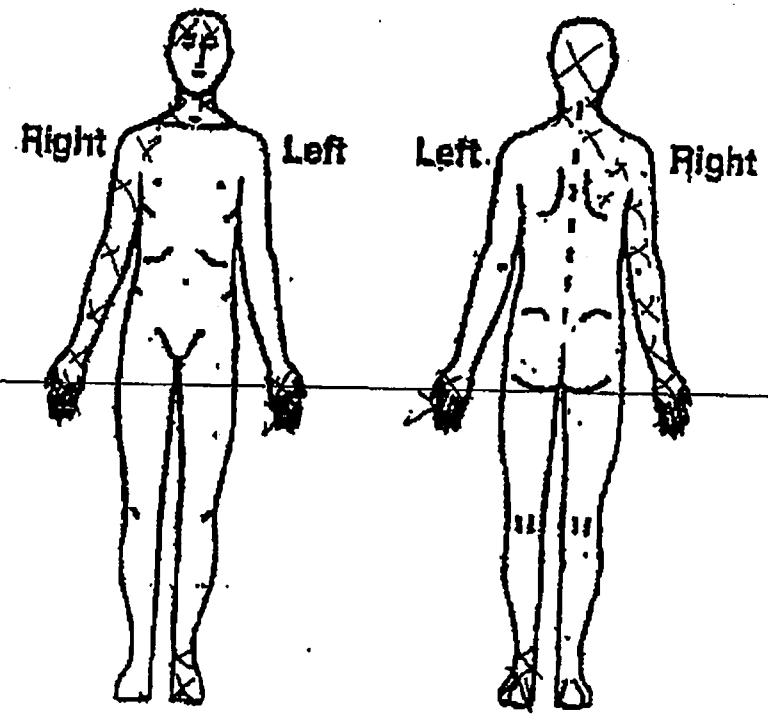


15. Date of your last:
Physical exam _____ Spinal exam _____ MRI, CT or Bone Scan _____
Spinal X-ray _____ Chest x-ray _____ Blood test _____

# COLUMBIA NEUROSURGICAL ASSOCIATES, P.A.

137270

Please complete this medical questionnaire. The answers to these questions are very important in helping us take care of you. Where appropriate, fill in complete answers. Thank-you for your time and patience.

Name: Victor Benjamin (M) / F (circle one) Date of Visit: 1-22-13

Age: _____ Height 60' Weight: _____ Date of Birth: _____

Referring Doctor: _____ Family Doctor: Roosevelt Daniels

1. I am ( ) right handed ( ✓ ) left handed.
2. Chief complaint or reason for visit: Serious Neck Pains, head Pains, Arms + hand. Pains - ringing in both ears, numbness of hands, Jumping in sleep or when sitting
3. When did your symptoms first appear? After the accident 6-15-2011
4. Did you have an injury? ( ✓ ) Yes ( ) No If yes, was it work related? ( ✓ ) Yes ( ) No ( ) Other _____
5. I have been treated for this problem by: Dr. Saab - had injections Dr. Sandor with medication
6. What did they do or recommend? They also recommended surgery

7. PAST MEDICAL HISTORY: List prior injuries & illnesses, conditions, medical problems that you have (ex: diabetes, high blood pressure, heart disease) Write HOSP. beside any for which you were admitted to the hospital.

| Approx. date | Reason (Give Diagnosis of problem if known) |
|---|---|
| Dec 2007 | Twisted Ankle |

8. PAST SURGICAL HISTORY: List all surgeries, even if done as an outpatient:

| Date | Procedure |
|---|---|
| 6-17-2011 | Operated on Right Arm - repair leaders from the accident @ McLeods Hospital - Florence, SC |

9. SOCIAL HISTORY: Check box or fill in blank:
( ✓ ) I do not use tobacco. ( ) I do use tobacco: _____ packs/per day
( ✓ ) I do not use beer, wine or liquor. ( ) I do use beer, wine or liquor ( ) daily ( ) weekly ( ) monthly
I am ( ✓ ) married ( ) widowed ( ) divorced ( ) single Years of formal education 12th + vocational
I have (2) children, ages: 13 + 20
I work as a Front end Maintainer Prior to injury for a Person for 30 yrs
( ✓ ) I have been disabled since 6-15-2011 due to (list reason) injury @ Work 6-15-11

10. FAMILY HISTORY: Please list any illness that your grand parents, parents, brothers, sisters or children have had. (for example: cancer, diabetes, heart disease, high blood pressure, stroke)
Grand Mother _____ Grand Father _____
Mother High blood Pressure Father High blood Pressures
Sister _____ Brother _____
Children Allergies

11. SYSTEMS REVIEW: Please check any that apply to you:
Constitutional: ____ Fever in last 72 hrs. ____ hot or cold spells
____ generalized weakness ✓ generalized lack of energy
____ unplanned weight loss _____ lbs over _____ months
____ Other: _____

Eyes: ____ declining vision ✓ blurred vision ____ double vision ✓ seeing spots of light
____ black areas in field of vision ____ eye disease ( cataracts, glaucoma, etc.) _____
____ Other: _____

Ear Nose, Mouth Throat:
____ ear aches ____ decreased hearing ✓ ringing in ears both
____ frequent nosebleeds ____ chronic sinus ____ mouth ulcers
____ mouth/throat cancer ✓ voice changes or hoarseness
Other: _____

Cardiovascular:

___ chest pain ( ) sharp ( ) dull ( ) happens only when exercising
___ history of heart attack ___ heart surgery or catheterization
___ palpitations ___ heart murmur ___ heart rhythm disturbance
✓ shortness of breath ( ) happens only when exercising
___ I have a pacemaker
Other: ___

Respiratory: History of:

___ pneumonia ___ bronchitis ___ tuberculosis
___ asthma ___ emphysema ___ lung cancer
___ I cough up blood from time to time
___ Other: ___

Gastrointestinal:

___ difficulty swallowing ___ nausea/vomiting last 48hrs
___ stomach ulcers ___ heart burn
___ diarrhea ___ change in appetite
___ stomach or bower cancer ___ liver disease
___ bulimia ___ anorexia
___ hernia ___ hepatitis
Other: ___

Genitourinary:

___ frequent urinary tract infection ___ difficulty urinating ___ painful urination
___ blood in urine ___ prostate problems ___ vaginal infections
___ miscarriage ___ venereal disease : ( ) gonorrhea ( ) herpes ( ) syphilis
___ Other: ___

Musculoskeletal:

___ joints that dislocate ___ leg or ankle swelling ___ osteoporosis
___ arthritis ___ gout ___ fractures ___ polio
✓ back pain ___ leg pain ( ) right ( ) left
___ back pain is relieved completely when I lie down
___ back pain is relieved mostly when I lie down
___ Lying down does not help my back pain
✓ neck pain ( ✓ ) right side ( ✓ ) left side ( ✓ ) both sides
___ arm pain ( ) right ( ) left ( ✓ ) both

Hematologic/lymphatic:

___ bleeding disorder ___ easy bruising ___ anemia
___ tendency to form blood clots in legs ___ swollen lymph nodes
___ Aids ___ HIV

Immunologic: ___ Lupus ___ Scleroderma ___ Rheumatoid arthritis

Other:

___ chicken pox ___ measles ___ mumps ___ Mononucleosis
___ scarlet fever ___ whooping cough ___ typhoid fever ___ rheumatic fever

Integumentary:

___ skin rashes
___ skin cancer– Type: ___
___ breast disease ___

Neurological.

✓ headaches: How often daily Sharp pains ___ with nausea ___ with blurred vision
___ fainting spells ___ history of migraines
✓ confusion ✓ declining memory
✓ history of head trauma ___ history of brain tumor
___ facial numbness ✓ dizziness
___ multiple sclerosis ✓ epilepsy on medicine
✓ numbness in hands or arms ( ✓ ) right ( ) left ( ) both
✓ difficulty using hands ( ✓ ) right ( ✓ ) left ( ✓ ) both
✓ difficulty walking/numbness in legs ( ) right ( ) left ( ) both walk toward right off balance

Psychiatric: ___ I have been treated/hospitalized for:

___ schizophrenia ___ depression ___ suicide attempt
___ alcoholism ___ chemical dependency

Endocrine: ___ thyroid ___ goiter ___ diabetes

12. If you have back, leg, neck or [illegible] pain, please answer the following:
___ I have taken physical therapy in the last 6 months for this problem
✓ I have taken medicines like Motrin, Aleve, muscle relaxents or pain medicine to help relieve the pain.
✓ I have had steroid injections in my back or neck for this problem.

Rate the severity of your pain on a scale from 1 to 10, with 1 the least painful and 10 being the most severe. _____

Type of pain:
10 sharp ___ dull 7 throbbing 10 aching 10 shooting 7 burning
9 tingling 5 numbness ___ stiffness ___ swelling ___ cramps
Other: _____

✓ the pain comes and goes
___ the pain is constant

If so, how often do you have this pain? In my head the pains comes/goes About 5-8 times a day - last sometimes over 5 minutes

Does the pain interfere with ___ work ✓ sleep ✓ daily routine ✓ recreation
Activities or movements that are painful to perform:
___ sitting ✓ standing ___ walking ✓ bending ✓ lying down
How do you sleep? ___ back ✓ side ___ stomach

13. I am claustrophobic ( fear of being in a closed/confined place ) ( ) Yes ( ) No
I have metal in my body. ( ) Yes ( ✓ ) No If yes, where? _____

14. Mark an X on the picture where you have pain, numbness or tingling.

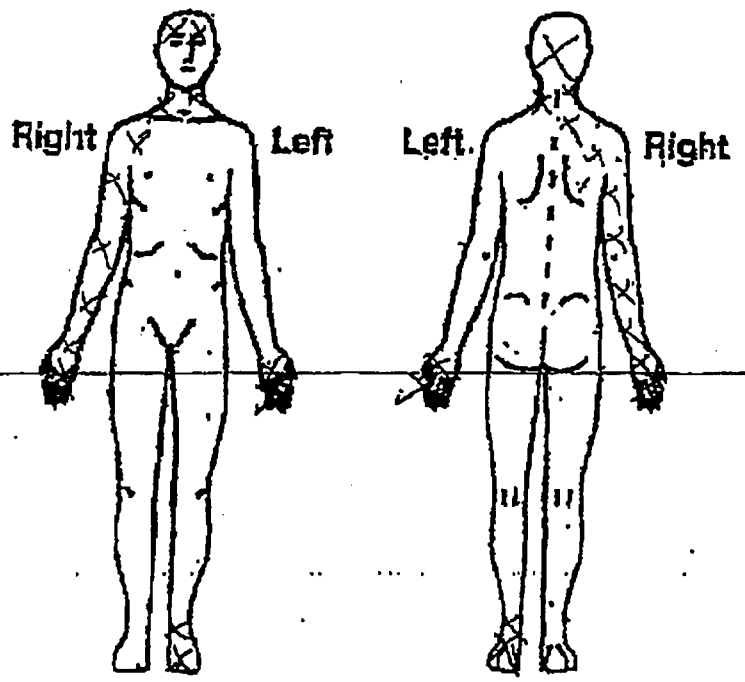


15. Date of your last:
Physical exam _____ Spinal exam _____ MRI, CT or Bone Scan _____
Spinal X-ray _____ Chest x-ray _____ Blood test _____

16.

| List Drug of Food Allergies | DESCRIBE THE REACTION | Allergic To: | Yes | No |
|---|---|---|---|---|
| | | Betadine/Iodine | | |
| | | Latex | | |
| | | IVP dye/CT prep | | |
| | | Other contrast | | |

IMMUNIZATION RECORD- ( PLEASE RECORD YEAR OF THE LAST DOSE TAKEN, IF KNOWN )

Flu Vaccine_____ Hepatitis Vaccine_____ Pneumonia Vaccine_____

Shingles_____ Tetanus_____

LIST ALL MEDICINES YOU ARE CURRENTLY TAKING; prescription and over the counter medications ( aspirin, antacids ) herbal medications ( ginseng, ginkgo ), and vitamins as well as medications that are taken as needed only ( nitroglycerin ).

| Name of Medication and Strength (dose) | Directions | Reason for Taking | Date stopped |
|---|---|---|---|
| Example : Motrin 800mg | One 3 times a day | arthritis | n/a |
| | | | |
| Vimpat 100 MG | 2 a day | Seizures | |
| Tramadol APAP 37.5 MG | 6 hr as Needed | Pains | |
| ZANAFLEX 4 MG | 3 times a day | Pains | |
| XANAX .5 MG | 2 @7 + 2 @9 | Relax-Sleep | |
| DIOVAN 160 MG | 1 a day | Blood Pressure | |
| Pravastatin 40 MG | 1 a day | Cholestoral | |

By: VICTOR BENJAMIN
Patient Signature

1-22-13
Date

Physician Signature

16.

| List Drug of Food Allergies | DESCRIBE THE REACTION | Allergic To: | Yes | No |
|---|---|---|---|---|
| | | Betadine/Iodine | | |
| | | Latex | | |
| | | IVP dye/CT prep | | |
| | | Other contrast | | |

IMMUNIZATION RECORD- ( PLEASE RECORD YEAR OF THE LAST DOSE TAKEN, IF KNOWN )

Flu Vaccine_____ Hepatitis Vaccine_____ Pneumonia Vaccine_____

Shingles_____ Tetanus_____

LIST ALL MEDICINES YOU ARE CURRENTLY TAKING; prescription and over the counter medications ( aspirin, antacids ) herbal medications ( ginseng, ginkgo ), and vitamins as well as medications that are taken as needed only ( nitroglycerin ).

| Name of Medication and Strength (dose) | Directions | Reason for Taking | Date stopped |
|---|---|---|---|
| Example : Motrin 800mg | One 3 times a day | arthritis | n/a |
| | | | |
| Vimpat 100 MG | 2 a day | Seizures | |
| Tramadol APAP 37.5 MG | 6 hr as Needed | Pains | |
| ZANAFLEX 4MG | 3 times a day | Pains | |
| XANAX .5 MG | 2 @ 7 + 2 @ 9 | Relax-Sleep | |
| DIDVAN 100 MG | 1 a day | Blood Pressure | |
| Pravastatin 40 MG | 1 a day | Cholestoral | |

By: VICTOR BENJAMIN
Patient Signature

1-22-13
Date

Physician Signature

# COLUMBIA NEUROSURGICAL ASSOCIATES, P.A.

www.columbianeurosurgical.com

Spine & Neurological Surgery

Thomas J. Holbrook, Jr., MD
William M. Rambo, Jr., MD
Randall G. Drye, MD
Scott B. Boyd, MD
Brett C. Gunter, MD
Karl A. Lozanne, MD

720 Rabon Road
Columbia, SC 29203
(803) 462-0423 - (F) 462-0432

Pain Medicine
Eva J. Rawl, MD

192 Sunset Court
W. Columbia, SC 29169
(803) 794-3700 - (F) 794-0322


**OFFICE CONSULTATION**

Patient: Victor G. Benjamin
Chart:
DOB:
Date: 1/22/13

CHIEF COMPLAINT: Neck pain, right-sided arm pain, bilateral arm numbness and tingling, imbalance.

HISTORY OF PRESENT ILLNESS: Victor Benjamin is a 50-year-old male who works for Rexam, a can manufacturing company. On 6/15/11, he suffered a work-related injury in which a metal piece from the machine he was working on fell on top of his head and onto his shoulder. Per report, the metal piece weighed over 20 pounds. He lost consciousness and was treated for a laceration to his scalp, his concussion, as well as his shoulder and right arm injury. He underwent right arm tendon repair.

He has continued to struggle with headaches, neck pain, right-sided interscapular and shoulder pain that radiates down into his right arm. He has developed difficulties with his balance and has had numbness and tingling worse on the right than the left. He has developed weakness in the right upper extremity. He denies any urinary or bowel symptoms. He has been managed with oral analgesics, physical therapy and more recently epidural steroid injections. The epidural steroid injections initially were effective at relieving his right-sided arm discomfort but the pain has returned. He underwent an MRI of the cervical spine which revealed significant cervical stenosis with disc/osteophyte complexes as well as what appeared to be spinal cord signal change. He was seen by another surgeon who recommended to undergo a surgical intervention. He presents to me for consultation and further discussion of treatment options.

HISTORIES: Please see patient history form for medications/allergies, past medical history, social history, family history, and review of systems which are well documented in the intake sheet dated 1/21/13 and have been reviewed and signed. The information contained is noncontributory except for that in the HPI. He lists no other past medical history. He had a right arm tendon repair in June 2011 at McLeod Hospital in Florence.

He has been out of work since his work-related injury. He is married with two children. He denies any tobacco use.

PHYSICAL EXAMINATION: Awake, alert, and oriented with normal and appropriate speech. Cranial nerves: VFF on confrontation. EOMI. Facial sensation and movements are symmetric. Hearing is normal. Palate elevates symmetrically and tongue protrudes in the midline. Motor: 4+/5 in the right deltoid, bicep, tricep, hand intrinsics. All other muscle groups are 5.5. Sensory: Decreased to light touch in left-sided C7 and C8 distributions. He is globally hyperreflexive with positive Hoffmann's sign bilaterally and two beats of clonus bilaterally. Reflexes: 4+ at the patellas, 3+ at the Achilles, with 3+ bilateral bicep and tricep reflexes. No Babinski or Hoffmann's sign present. Gait is normal. Finger-to-nose testing is normal.

DIAGNOSTIC STUDIES: EMG/nerve conduction study performed 11/3/11 at that time revealed a moderate degree of carpal tunnel syndrome in the right upper extremity as well as an ulnar neuropathy in the right upper extremity.

IMAGING STUDIES: MRI of the cervical spine performed 11/15/12 is available for my direct review. It comes on CD from Florence MRI and reveals what appears to be a small degree of spinal cord signal change at the C3-4 level. He has a generally narrow canal. At C3-4 I see a mild disc bulge with osteophytes and a mild degree of central canal stenosis. However, at C4-5, C5-6 and C6-7 he has disc/osteophyte complexes with a moderate degree of right-sided lateral recess and foraminal stenosis at 4-5 and 5-6 and a severe amount of lateral recess and foraminal stenosis on the left side at C6-7.

IMPRESSION/PLAN: Mr. Victor Benjamin suffered a work-related injury in June of 2011 and has presented to me with cervical myelopathy as well as signs and symptoms of cervical radiculopathy in both the right and left thumb. Imaging studies reveal multi-level degenerative disease with disc/osteophyte complexes at C4-5, C5-6 and C6-7 consistent with his signs and symptoms.

Considering his condition, I have recommended surgical intervention in the form of an anterior cervical discectomy and plated fusion at C4-5, C5-6 and C6-7. It is my opinion that the C3-4 level does not require any surgical intervention at this time because I am not seeing any significant neural compression despite the fact that it does appear that there is some spinal cord signal change at this level. I suspect that this is from his initial injury and contusion. Nonetheless, he is still manifesting radiculopathy and cervical myelopathy.

The surgical procedure offered was described in detail with the aid of models and diagrams. We discussed the potential benefits, treatment alternatives, and risks which include, but are not limited to: worsening of current status, the possible need for further procedures, the risk of infection, headaches, CSF leak, possible spinal nerve injury resulting in paralysis, infection, neck hematoma, hoarseness of voice, injury to major vessels causing hemorrhage, stroke, loss of language function, coma, and even death. No assurance was given whether symptoms would improve following the procedure. The patient voiced understanding of these risks and decided to proceed with the proposed procedure.

Mr. Benjamin does wish to proceed with surgery. I have discussed this in the company of the case manager, Ms. Rena Spencer. We will schedule this procedure at his convenience. He does understand that the surgical procedure itself is aimed at relieving pressure on the central canal as well as the nerve roots but not one that is going to result in complete recuperation of spinal cord function. There is the possibility he may continue to struggle with discomfort considering his injury. They displayed full understanding of this and wish to proceed. They do understand that he should refrain from any activities with the potential of head and neck injury which could result in worsening spinal cord function. They agree to comply.

Karl Lozanne, MD

Karl A. Lozanne, MD
THIS DOCUMENT HAS BEEN ELECTRONICALLY SIGNED
KAL/MAH CNAWT: 5000

COLUMBIA NEUROSURGICAL ASSOCIATES, P.A.
Spine and Neurological Surgery

Carolina Spine Center
A Program of Columbia Neurosurgical Associates

Sylvia Miller, Dir. Industrial Care Dept.
PH (803) 462-3602 Fax (803)462-3847

# WORK STATUS INFORMATION

## PATIENT WORK INJURY INFORMATION

VICTOR BENJAMIN
Patient Name

Patient social security #

Chart #

REXAM INC
Employer Name

SEDGWICK CMS
Insurance Carrier

YYC51304C
Case #

01/22/2013
Date of Service

06/15/2011
Date of Accident

Diagnosis code(s) and/or description of condition for which patient is being treated

Remain out of work for until further notice

## PHYSICAL LIMITATIONS

SURGERY

## FOLLOW UP

Physician:KARL A. LOZANNE, MD

Signature: Karl Lozanne, MD

131270

Palmetto Health Baptist
Taylor @ Marion, Columbia SC 29220

Operative Note

Name: BENJAMIN, VICTOR
MR#:
Dictating: Karl Lozanne, M.D.

DOB:
Admit: 02/18/2013

DATE OF OPERATION: 02/18/2013

SURGEON: Karl Lozanne, M.D.

ATTENDING SURGEON: Karl Lozanne, M.D.

ASSISTANT: Coleman Fravel, PA

POSTOPERATIVE DIAGNOSES:
1. Cervical spondylotic myelopathy.
2. Cervical stenosis.

POSTOPERATIVE DIAGNOSES:
1. Cervical spondylotic myelopathy.
2. Cervical stenosis.
3. Degenerative disc disease.

PROCEDURES PERFORMED:
1. C4-C5 anterior cervical diskectomy and osteophytectomy for decompression of neural elements.
2. C5-C6 anterior cervical diskectomy and osteophytectomy for decompression of neural elements.
3. C6-C7 anterior cervical diskectomy and osteophytectomy for decompression of neural elements.
4. C4-C5 arthrodesis, anterior interbody technique.
5. C5-C6 arthrodesis, anterior interbody technique.
6. C6-C7 arthrodesis, anterior interbody technique.
7. C4-C5 insertion of biomechanical device (DePuy Synthes PEEK).
8. C5-C6 insertion of biomechanical device.
9. C6-C7 insertion of biomechanical device.
10. C4-C7 anterior cervical plate and screws (DePuy Synthes Vectra).
11. Use of autograft bone.
12. Use of allograft osteopromotive material DBX putty).
13. Use of microscope for microdissection.
14. Fluoroscopy for localization and instrumentation.

ANESTHESIA: General endotracheal anesthesia.

ESTIMATED BLOOD LOSS: 50 mL.

Palmetto Health Baptist
Taylor @ Marion, Columbia SC 29220

Operative Note

Name: BENJAMIN, VICTOR
MR#:
Dictating: Ken Lozanne, M.D.

DOB:
Admit: 02/18/2010



FINDINGS: Degenerative disk disease worse at the C5-6 and C6-7 levels, hypermobility of C4 on C5, and C5 on C6. Significant stenosis centrally as well as bilaterally at the foramen at each level.

COMPLICATIONS: None.

DRAINS: None.

DISPOSITION: Stable to the PACU.

INDICATIONS FOR PROCEDURE: Mr. Victor Benjamin is a 50-year-old, who suffered a work-related injury, in which he was struck on the head by a falling piece of machinery. He suffered a neck, as well as right shoulder injury. He presented to me with cervical spondylotic myelopathy and imaging studies revealed severe stenosis, as well as spinal cord signal change. Given the progression of his symptoms and image findings, we decided to proceed with a surgical decompression to help minimize the risk of additional spinal cord deterioration.

The patient was given preoperative prophylactic IV antibiotics and was then transferred to the operating room.

Anesthesia: The patient was sedated and intubated by anesthesia service without complication. Eyes were taped shut after ointment was applied to prevent corneal abrasion.

Positioning: The patient was left supine with a small roll underneath the cervical spine. The cervical spine was placed in slight extension. All pressure points were carefully padded.

Three-inch tape was used to retract the shoulders caudally for appropriate x-ray visualization.

Surgical technique: The anterior neck was prepped and draped in a standard sterile fashion. A right anterior neck transverse incision was then planned opposite the C6 vertebral body. It was opened with a No. 10 scalpel blade. Sharp dissection was carried down through the platysma. A plane was then developed medial to the right sternocleidomastoid musculature and carotid sheath. The anterior longitudinal ligament

Palmetto Health Baptist
Taylor @ Marion, Columbia SC 29220

Operative Note

Name: BENJAMIN, VICTOR
MR#:
Dictating: Ken Lozanne, M.D.

DOB:
Admit: 02/16/2013



was exposed.

The C-arm fluoroscopy machine was draped in a sterile drape and brought into the operative field. Using x-ray fluoroscopy, the C5-C6 interspace was localized. Dissection was then carried bilaterally to expose the C4-5, C5-6 and C6-7 uncovertebral joints. The longus coli musculature was then retracted with a self-retaining retractor.

I first addressed the C4-5 disk space. There was significant movement at C4 on C5. A 15 scalpel blade was used to incise the anulus. The microscope was then draped in a sterile drape and brought into the operative field. Using microsurgical technique, a complete diskectomy was performed at the C4-5 level. The anterior osteophyte was trimmed with a high-speed electric drill. Autograft bone was then obtained from the undersurface of the C4 vertebra.

The posterior longitudinal ligament was pierced with a nerve hook and subsequently removed totally with a small Kerrison rongeur punch. The underlying thecal sac remained intact. Care was taken not to deflect the thecal sac.

For arthrodesis, the endplates were abrasioned with a high-speed electric drill.

I then carried my attention to the C5-C6 and C6-C7 disk spaces. At the C5-6 level due to significant degenerative disk disease, the disk space was fairly collapsed. I placed distraction pins into the C5 and C6 vertebra and using slight distraction, I was able to completely remove the C5-C6 disk space in a similar fashion to the C4-5 disk space. The posterior longitudinal ligament was removed. I confirmed appropriate decompression centrally, as well as bilaterally at the foramina with a nerve hook. Additional autograft bone was taken from the undersurface of the C6 vertebra. For arthrodesis, the endplates were abrasioned with a high-speed electric drill.

In a similar fashion, the C6-C7 disk space was shaved and prepared for arthrodesis. I confirmed appropriate decompression both centrally and bilaterally at the foramina at each of the decompressive levels with a small nerve hook. Hemostasis was meticulously achieved.

Using x-ray fluoroscopy, interbody cages were appropriately sized. These were packed with the patient's autograft bone that was obtained from the undersurface of C4-C5, and C6. Additional Osteo promoter material (DBX putty) was packed into the interbody cages. A large 8 mm cage was placed under direct x-ray fluoroscopy into the C6-C7 disk space, 7 mm cages were placed at the C4-5 and C5-C6 disk spaces. X-ray

Palmetto Health Baptist
Taylor @ Marion, Columbia SC 29220

Operative Note

Name: BENJAMIN, VICTOR
MR#:
Dictating: Karl Lozanne, M.D.

DOB:
Admit: 02/18/2013



fluoroscopy confirmed good placement of the interbody cage. The cage fit well and was snug.

An anterior cervical plate was then appropriately sized. It was secured into the C4-C5, C6, and C7 vertebra under direct x-ray fluoroscopy with fixed angled screws into C5 and C6 and variable angle screws into C4 and C7 (DePuy Synthes Vectra). X-ray fluoroscopy confirmed good placement of the interbody plate and screws.

The wound was irrigated with copious amount of antibiotic saline solution. Hemostasis was meticulously achieved. The wound was then closed in layers with 3-0 Vicryl stitches in the platysma and subcutaneous tissues, and an interrupted 4-0 Vicryl subcuticular stitch approximated the skin.

All needle counts, sponge counts, and instrument counts were correct at the end of the case x2. The patient tolerated the procedure well, was extubated without difficulty and transferred to the recovery area in stable condition. Dr. Lozanne was present for all critical portions of the case.

D: 02/18/2013 11:59 T: 02/18/2013 12:24 TID: 90811
Job #: 49420 Doc #: 30030219
cc: Karl Lozanne, M.D.

137270

**Palmetto Health Baptist**
**SURGICAL PATHOLOGY DIVISION**
One Science Court, Suite 200
Columbia, SC 29203
(803) 252-1913

# Surgical Pathology Report

Patient Name: **BENJAMIN, VICTOR G**
DOB/Age: (Age: 50)/M
Soc. Sec. #:
Client: Palmetto Health Baptist
MRN:
Physician: Karl A. Lozanne, MD

Accession #: **BS13-1308**
Date of Service: 2/18/2013
Date Received: 2/18/2013
Date Reported: 2/19/2013

Account #: 1303700840
Location: OPS (BAP)

**CLINICAL DATA:**
Degenerative disc disease C4-C7

**DIAGNOSIS:**

**DISC MATERIAL C4-7:**
CARTILAGINOUS DISC MATERIAL.

PLG/ls 02-19-13

****Electronically Signed Out by Paul L. Guerry III, MD ****

**GROSS DESCRIPTION:**
Received in formalin labeled "disc material" is a 4.5 x 4.0 x 0.6 cm aggregate of pink-white cartilaginous fragments. Representative piece is submitted in a single cassette.

MU/ls 02-18-13

**MICROSCOPIC DESCRIPTION:**
Fibrocartilage blends into hyaline cartilage. Bone fragments are noted as well. No atypical infiltrates are seen. Neovascularization is not prominent.

PLG/ls 02-19-13



END OF REPORT

Palmetto Health Baptist
Taylor @ Marion, Columbia SC 29220

137270

Discharge Summary

Name: BENJAMIN, VICTOR
MR#:
Dictating: Coleman S. Fravel, PA

DOB:
Admit: 02/18/2013
Discharge: 02/20/2013

Coleman Fravel dictating for Karl Lozanne, M.D.

DATE OF ADMISSION: 02/18/2013

DATE OF DISCHARGE: 02/20/2013

ADMITTING DIAGNOSIS: Cervical myelopathy with degenerative disk disease.

DISCHARGE DIAGNOSIS: Cervical myelopathy with degenerative disk disease.

PROCEDURE DURING HOSPITALIZATION: Anterior cervical diskectomy fusion C4-5, C5-6, and C6-7.

BRIEF HISTORY: This patient is a 50-year-old, African-American male who presented to the office under workman's comp for evaluation of cervical stenosis and myelopathy. Recommendations were made for surgery.

HOSPITAL COURSE: On 02/18/2013 the patient presented to the holding area at Baptist. He was taken to the operating room and under general endotracheal anesthesia underwent the above-mentioned procedure. He tolerated the procedure without complications and went from the operating room to the recovery room and to the surgical ward where he spent the remainder of his hospitalization. The remainder of his hospitalization was spent getting his pain under control and monitoring him closely. Once he was able to manage pain with p.o. medications, void on his own, and take good p.o. intake he was stable for discharge. His preoperative symptoms of pain and tingling in his right arm did not have significant improvement; however, I did discuss with him the importance of the surgery was to prevent further loss of neurologic function. His power in his upper extremities was rated at 4/5. Lower extremities were 5/5. His wound was flat and dry. At this time he is stable for discharge to home.

FINAL DISPOSITION: He will be discharged home today in stable condition. He was given thorough discharge instructions. Avoid aspirin products and nonsteroidals for at least 1 month's time. He will wait until he returns to the clinic before he can be cleared for driving. He is instructed to wear his cervical collar except when showering. He may remove it. He is to call with any questions or concerns.

D: 02/20/2013 08:11 T: 02/20/2013 13:34 TID:

Palmetto Health Baptist
Taylor @ Marion, Columbia SC 29220

Discharge Summary

Name: BENJAMIN, VICTOR
MR#:
Dictating: Coleman S. Fravel, PA

DOB:
Admit: 02/18/2013
Discharge: 02/20/2013

Job #: 50832 Doc #: 00088904
cc: Coleman S. Fravel, PA

# COLUMBIA NEUROSURGICAL ASSOCIATES, P.A.

www.columbianeurosurgical.com
Spine & Neurological Surgery
Thomas J. Holbrook, Jr., MD
William M. Rambo, Jr., MD
Randall G. Drye, MD
Scott B. Boyd, MD
Brett C. Gunter, MD
Karl A. Lozanne, MD
720 Rabon Road
Columbia, SC 29203
(803) 462-0423 - (F) 462-0432
Pain Medicine
Eva J. Rawl, MD
132 Sunset Court
W. Columbia, SC 29169
(803) 794-3700 - (F) 794-0322

**OFFICE VISIT**

Patient: Victor G. Benjamin
Chart:
DOB:
Date: 3/5/13

Victor Benjamin underwent an anterior cervical discectomy and plated fusion of the C4-5 to C5-6 and C6-7 levels on 2/18/13 after presenting with cervical spondylotic myelopathy following a work related injury that occurred in June 2011. He underwent the procedure without complication and returns to the office today for his first follow up visit. Preoperatively he had significant neck pain, right sided arm pain and bilateral arm numbness and tingling with associated imbalance.

Victor reports that postoperatively he was doing well. He started to develop neck discomfort that appears to be a manifestation of muscular spasms. He complains of some discomfort radiating towards his left shoulder, but denies any recurrence of right sided arm pain. He continues to struggle with numbness and tingling in the hands bilaterally. He was discharged with a four wheel walker.

On examination, he continues to manifest right sided 4+/5 strength in the deltoid, biceps, triceps and hand intrinsics. All other muscle groups are 5/5. He has decreased sensation to light touch on the left side at C7 and C8 distribution as he had preoperatively. His incision is healing well.

IMPRESSION/PLAN: We will transition Victor to formal physical therapy. He has taken tramadol intermittently for discomfort as well as the muscle relaxer medication. The physical therapy should be helpful at relieving some of his muscular tension.

We will see him back in the office in eight weeks. I recommended continued out of work status. He is going to continue to use his cervical collar for an additional four weeks.

Karl Lozanne, MD

Karl A. Lozanne, MD
THIS DOCUMENT HAS BEEN ELECTRONICALLY SIGNED
KAL/RS CNAWT: 5010

CI ABIA NEUROSURGICAL ASSOCIA...., P.A.
Spine and Neurological Surgery

Carolina Spine Center
A Program of Columbia Neurosurgical Associates

Sylvia Miller, Dir. Industrial Care Dept.
PH (803) 462-3602 Fax (803)462-3647

# WORK STATUS INFORMATION

## PATIENT WORK INJURY INFORMATION

VICTOR G BENJAMIN
Patient Name | Patient social security # | Chart #

REXAM INC | Sedgwick CMS
Employer Name | Insurance Carrier

YYC51304C | 03/05/2013 | 06/15/2011
Case # | Date of Service | Date of Accident

Diagnosis code(s) and/or description of condition for which patient is being treated

Remain out of work for until further notice

## PHYSICAL LIMITATIONS

PT- f/u 8 weeks

## FOLLOW UP

Physician:KARL A. LOZANNE, MD

Signature: Karl Lozanne, MD

# COLUMBIA NEUROSURGICAL ASSOCIATES, P.A.

www.columbianeurosurgical.com

Spine & Neurological Surgery

Thomas J. Holbrook, Jr., MD
William M. Rambo, Jr., MD
Randall G. Dye, MD
Scott B. Boyd, MD
Brett C. Gunter, MD
Karl A. Lozanne, MD

720 Rabon Road 192 Sunset Court
Columbia, SC 29203 W. Columbia, SC 29169
(803) 462-0423 - (F) 462-0432

Pain Medicine
Eva J. Rawl, MD
(803) 794-3700 - (F) 794-0322


**OFFICE VISIT**

Patient: Victor G. Benjamin
Chart:
DOB:
Date: 05/16/2013
CNAWT: 5010

Victor Benjamin is a 51-year-old who underwent an anterior cervical discectomy and plated fusion at C4-5, C5-6 and C6-7 on 2/18/13 after presenting with cervical spondylotic myelopathy following a work related injury that occurred in June 2011. He had a large piece of metal land on his hand and shoulder and presented with significant right upper extremity weakness and myelopathy. Imaging studies revealed severe cervical stenosis with spinal cord signal change. He underwent the procedure without complication and returns to the office today for additional follow up.

Victor initially had complete resolution of right-sided arm pain. Over the last three to four weeks, however, he has had a recurrence of right-sided arm discomfort. He is also experiencing headaches. He has been undergoing physical therapy, which helps relieve his discomfort, but only during the physical therapy sessions.

On examination, he still manifests 4+/5 right deltoid, biceps, triceps and hand intrinsic weakness on the right. All other muscle groups are 5/5. He has decreased sensation to light touch, right sided C8 at C7 distribution. His left sided decreased sensation has improved. His incision is healing well.

IMPRESSION/PLAN: At this stage I feel that he needs continued physical therapy. He has had episodes of feeling that his legs are going to give out. His reflexes are still elevated as a manifestation of his myelopathy. He has been prescribed a 4-point cane.

With the recurrence of right sided shoulder and arm pain and persistence of weakness in multiple muscle groups in the right upper extremity, I have to consider a shoulder pathology and potentially brachial plexus pathology. Should his symptoms not continue to improve over the next four to six weeks, I would recommend assessment of right shoulder and brachial plexus.

He will continue with oral analgesics as previously prescribed. We will see him back in the office in eight weeks. He should remain with out of work status until seen for follow up. We will obtain AP and lateral x-rays of the cervical spine to rule out any problems with his instrumentation. The above has been discussed in the presence of Ms. Rena Spencer, the case manager.

Electronically signed by Karl Lozanne, MD at 05/17/2013 06:09

Karl Lozanne, MD

KL/rs
DOC#: 00001077/JOB#: 01273
CC: Rena Spencer, CCM

**Patient Demographics**

| Address | Phone |
|---|---|
| 1841 HALMAN RD<br>SUMTER SC 29153 | 803-428-3352 (Home) |

**Admission Information - Patient Record Only**

| | | | | | |
|---|---|---|---|---|---|
| Arrival Date/Time: | None | Admit Date/Time: | 05/16/2013 2:09 PM | IP Adm. Date/Time: | None |
| Admission Type: | Elective | Point of Origin: | Physician Or Clinic Referral | Admit Category: | None |
| Means of Arrival: | None | Primary Service: | None | Secondary Service: | N/A |
| Transfer Source: | None | Service Area: | Lchsd Service Area | Unit: | Lmc Radiology |
| Admit Provider: | None | Attending Provider: | Lozanne, Karl A, MD | Referring Provider: | Lozanne, Karl A, MD |

**Discharge Information - Patient Record Only**

| Discharge Date/Time | Discharge Disposition | Discharge Destination | Discharge Provider | Unit |
|---|---|---|---|---|
| 05/16/2013 11:59 PM | Home Or Self Care | None | None | Lmc Radiology |

## Radiology Results (05/17/13 - 05/17/13)

Resulted: 05/17/13 1036, Result Status: Final result

**XR Cervical Spine 2 or 3 Views or Trauma [15166598] (Normal)**

Resulted by: Hamby, Lon Powell, MD Performed: 05/16/13 1440 - 05/16/13 1446

Narrative:

PATIENT: Benjamin, Victor G MRN: M002006616 DOB: 4/19/1962
STUDY: XR Cervical Spine 2 or 3 Views or Trauma ACC #: 0000019791
DATE OF EXAM: 5/16/2013 2:10 PM

CLINICAL DATA: POST-OP, PAIN

CERVICAL SPINE - TWO VIEWS:

COMPARISON: No comparison studies.

FINDINGS: There is anterior and intervertebral fusion at C4-5, C5-6 and C6-7. There are changes of degenerative disc disease at C3-4. No vertebral subluxation is identified. No prevertebral soft tissue swelling.

Impression:

Previous cervical spine fusion.
Changes of degenerative disc disease at C3-4.

AHK LON P. HAMBY, M.D.

**END OF REPORT**

Lexington Medical Center

LEXINGTON MEDICAL CENTER
2720 Sunset Boulevard
West Columbia, SC 29169
Radiology Report

BENJAMIN,VICTOR G
MRN:
DOB: ..
Enc. Date:05/16/13

## Patient Demographics

| Address | Phone |
|---|---|
| 1841 HALMAN RD<br>SUMTER SC 29153 | 803-428-3352 (Home) |

## Admission Information - Patient Record Only

| | | | | | |
|---|---|---|---|---|---|
| Arrival Date/Time: | None | Admit Date/Time: | 05/16/2013 | IP Adm. Date/Time: | None |
| Admission Type: | None | Point of Origin: | None | Admit Category: | None |
| Means of Arrival: | None | Primary Service: | None | Secondary Service: | N/A |
| Transfer Source: | None | Service Area: | None | Unit: | None |
| Admit Provider: | None | Attending Provider: | None | Referring Provider: | None |

## Discharge Information - Patient Record Only

| Discharge Date/Time | Discharge Disposition | Discharge Destination | Discharge Provider | Unit |
|---|---|---|---|---|
| None | None | None | None | Lmc Radiology |

## Radiology Results

No matching results found

# COLUMBIA NEUROSURGICAL ASSOCIATES, P.A.

www.columbianeurosurgical.com

Spine & Neurological Surgery

Thomas J. Holbrook, Jr., MD
William M. Rambo, Jr., MD
Randall G. Drye, MD
Scott B. Boyd, MD
Brett C. Gunter, MD
Karl A. Lozanne, MD

720 Rabon Road 132 Sunset Court
Columbia, SC 29203 W. Columbia, SC 29169
(803) 452-0423 - (F) 452-0432

Pain Medicine
Eva J. Rawl, MD

(803) 794-3700 - (F) 794-0322


**OFFICE VISIT**

Patient: Victor G. Benjamin
Chart:
DOB:
Date: 07/12/2013
CNAWT:

Mr. Benjamin is a 51-year-old who underwent an anterior cervical discectomy and plated fusion at C4-5, C5-6 and C6-7 on 2/18/13 after presenting with cervical spondylitic myelopathy following a work related injury that occurred in June of 2011. He had a large piece of metal land on his head and shoulder and presented with significant right upper extremity weakness as well as myelopathy. He has been struggling with headaches. He returns to the office today for additional follow up. During the last visit, I was concerned about recurrence of right-sided shoulder discomfort after initial improvement. He also had persistence of weakness. He started physical therapy.

Victor states that he is still struggling with discomfort in the right shoulder girdle region that traverses into his right upper arm. He still has imbalance and ambulates with the aid of a four-pronged cane. He has been struggling with intermittent headaches.

On examination, he still manifests 4+/5 right deltoid, bicep, tricep and hand intrinsic weakness on the right. All other muscle groups are 5/5. He has decreased sensation to light touch in a right-sided C8 and C7 distributions,

IMAGING: X-rays of the cervical spine reveal good placement of the plate and interbodies.

IMPRESSION/PLAN: Considering persistence of multiple myotomes involved with weakness in the right upper extremity and pain across the right shoulder girdle, I feel that further imaging is indicated. I recommend an MRI of the right shoulder and brachial plexus for further assessment considering his mechanism of injury.

In regards to his myelopathy, I feel that surgical decompression has been appropriate. He does have persistence of hyperreflexia and he is no longer manifesting continued compression of his spinal cord.

I will see him back in the office following completion of his studies. In the interim, I do not recommend any work activity. He is to continue with out of work status until seen for follow up.

The above has been discussed in the presence of Rena Spencer, the case manager.

Electronically signed by Karl Lozanne, MD at 07/15/2013 05:58

Karl Lozanne, MD
KL/sb
DOC#: 00003073/JOB#: 03259
CC: Rena Spencer, CCM

***

# IMAGECARE, LLC

710 RABON ROAD
COLUMBIA, SC 29203
803-462-3680

Name: Benjamin, Victor G
Patient ID:
DOB:
Acc#:
Patient Phone #: (803) 428-3352
***

Exam Date: 08/02/2013
Exam: MRI ST Neck Wo
Reason:
Referrer: Lozanne, Karl a

PROCEDURE: MRI SOFT TISSUE NECK FOR BRACHIAL PLEXUS

CLINICAL HISTORY: Right shoulder pain, right upper extremity weakness, claims work injury June 15, 2011.

TECHNIQUE: 5 mm thick sagittal T1, 4 mm thick axial T1, inversion recovery and MEDIC relative T2 weighted sequences are obtained with 4 mm thick coronal T1 and inversion recovery sequences.

FINDINGS:

Previous anterior cervical fusion and discectomy is noted at C4-5, C5-6 and C6-7. The cervical spine shows normal alignment on sagittal and coronal views. There is no significant central spinal canal stenosis throughout the cervical spine. There are no visible levels of significant foraminal stenosis identified.

There is no visible nerve root avulsion. There is limited visualization of the nerves of the brachial plexus with no abnormalities noted. The soft tissues of the neck appear unremarkable.

IMPRESSION:

1. STATUS POST CERVICAL SPINE FUSION WITH ACDF FROM C4 THROUGH C7, WITHOUT RESIDUAL SPINAL CANAL STENOSIS AND WITHOUT APPARENT NEURAL FORAMINAL STENOSIS.

2. NO APPARENT EVIDENCE OF BRACHIAL PLEXUS INJURY.

Timothy P. Close, M.D.
Electronic Signature
Date Finalized: 08/05/2013

DD: 08/02/2013 DT:08/05/2013

***

# IMAGECARE, LLC

710 RABON ROAD
COLUMBIA, SC 29203
803-462-3680

Name: Benjamin, Victor G
Patient ID:
DOB:
Acc#:
Patient Phone #: (803) 428-3352
***

Exam Date: 08/02/2013
Exam: MRI UE Joint WO
Reason:
Referrer: Lozanne, Karl a

PROCEDURE: MRI OF THE RIGHT SHOULDER

CLINICAL HISTORY: Right shoulder pain, right upper extremity weakness, claims work injury 06/15/2011.

TECHNIQUE: Axial, off-axis sagittal oblique and multisequence multislice off-axis coronal oblique views are obtained throughout the right shoulder.

FINDINGS:

There is no significant hypertrophic change at the acromioclavicular joint; however, there is a type 3 configuration of the anterior inferior margin of the distal acromion. The right should joint demonstrates a small shoulder joint effusion, with a small subdeltoid bursal effusion noted, as well. There is mild increased signal in the central supraspinatus tendon near its osseous insertion, consistent with mild tendinopathy without full thickness tear. There is no significant muscle atrophy. The infraspinatus tendon demonstrates increased signal along its inferior or bursal surface fibers, with what appears to be a localized delamination tear in the subacromion space. There is no significant infraspinatus muscle atrophy. The teres minor muscle and tendon appear unremarkable. There is increased signal also identified in the superior fibers of the subscapularis tendon, consistent with subscapularis tendinopathy, without apparent coracohumeral impingement. The long head biceps tendon demonstrates mild increased signal within its intraarticular portion, consistent with intraarticular tendinopathy, with normal appearance at the bicipital groove. There is increased signal within the superior labrum, at and posterior of the biceps labral complex consistent with a type 2 SLAP tear. The remainder of the labrum appears unremarkable.

IMPRESSION:

1. MILD DISTAL SUPRASPINATUS TENDINOPATHY WITH TENDINOPATHY ALSO IN THE ANTERIOR FIBERS OF THE INFRASPINATUS TENDON. THERE IS A MILD TYPE 3 CONFIGURATION OF THE ANTERIOR INFERIOR MARGIN OF THE DISTAL ACROMION.

2. INTRAARTICULAR TENDINOPATHY OF THE LONG HEAD BICEPS TENDON WITH TENDINOPATHY ALSO NOTED IN THE SUPERIOR FIBERS OF THE SUBSCAPULARIS TENDON.

3. TYPE 2 SLAP TEAR PRIMARILY POSTERIOR OF THE BICEPS LABRAL COMPLEX.

4. SMALL SHOULDER JOINT EFFUSION AND SMALL EFFUSION OF THE SUBDELTOID BURSA. THERE IS NO SIGNIFICANT HYPERTROPHIC CHANGE AT THE ACROMIOCLAVICULAR JOINT.

Timothy P. Close, M.D.
Electronic Signature
Date Finalized: 08/05/2013

DD: 08/02/2013 DT:08/05/2013

137270

CHANDLER
LAW FIRM

JEFFREY C. CHANDLER, P.C.
FEIN 20-0523540

August 19, 2013

VIA FAX & HAND DELIVERY

Columbia Neurosurgical Associates
Attn: Dr. Karl Lozanne
720 Rabon Street
Columbia, SC 29203

RE: Victor Benjamin DOB: DOI: 06-15-11

Dear Dr. Lozanne:

I represent the above named client regarding a workers compensation claim that you are providing treatment for. On 02-18-2013 you performed an anterior cervical disectomy and fusion at C4-5 to C5-6 and C6-7. As I am sure you are aware, Mr. Benjamin is also treating with neurologist Dr. George Sandoz of Grand Strand Specialty Spine & Neuro. Enclosed please find a copy of his recent office note dated 06-20-2013. At that time he recommended Mr. Benjamin have an updated MRI of his cervical spine due to ongoing neck pain. Currently this scan is being denied by the Worker's Compensation carrier. They would like your input on the necessity of the cervical MRI at this time based on the Mr. Benjamin's treatment to date and symptoms.

1.) Are you are to state to a reasonable degree of medical certainty that a Cervical MRI is an appropriate diagnostic study at this time?

I do NOT believe that a Cervical MRI is necessary at this point in time

2.) If so, will you provide the order for the MRI and attach it to this questionnaire?

My opinions are to a degree of medical certainty.

Karl Lozanne 8/20/13
Dr. Karl Lozanne Date

Best Regards,

Jeff Chandler

cc: file
enclosures: as noted

P.O. Drawer 1889 • Myrtle Beach, SC 29578-1889
Office (843) 448-4357 • Fax (843) 448-4005 • jeffcchandler@aol.com • www.jeffchandlerlaw.com

**KARL A. LOZANNE, M.**
**Columbia Neurosurgical Associates, P.A.**
720 Rabon Rd. • Columbia, SC 29203 Phone: (803) 462-0423 Fax: (803) 462-0432
132 Sunset Court • W. Columbia, SC 29169 Phone: (803) 794-3700 Fax: (803) 794-0322

**Date:** 08/20/2013

# Order

**Patients Name:** VICTOR G BENJAMIN **DOB:**

**Phone:** (H)8034283352 **Phone:** (W) 0000000000 **SS#:**

**Diagnosis:** SHOULDER
REFERRAL TO ORTHO

**Consult with Dr.**

**Insurance:** Sedgwick CMSMSCOne Call MedicalCash

**Date/Time for Appointment:** /

Name: KARL A. LOZANNE, MD

Signature: Karl Lozanne, MD

# COLUMBIA NEUROSURGICAL ASSOCIATES, P.A.

www.columbianeurosurgical.com

Spine & Neurological Surgery

Thomas J. Holbrook, Jr., MD
William M. Rambo, Jr., MD
Randall G. Drye, MD
Scott B. Boyd, MD
Brett C. Gunter, MD
Karl A. Lozanne, MD

720 Rabon Road
Columbia, SC 29203
(803) 462-0423 - (F) 462-0432

Pain Medicine
Eva J. Rawl, MD

132 Sunset Court
W. Columbia, SC 29169
(803) 794-3700 - (F) 794-0322


**OFFICE VISIT**

Patient: Victor G. Benjamin
Chart:
DOB:
Date: 11/21/2013
CNAWT:

Victor Benjamin suffered a work-related injury in June of 2011. He had a large piece of metal land on his head and shoulder and presented with significant right upper extremity weakness as well as myelopathy. He had a spinal cord injury and underwent an anterior cervical discectomy and plated fusion at the C4-5, C5-6 and C6-7 levels on 2/18/13. He initially made improvements, although he continued to struggle with right-sided shoulder region discomfort. An MRI of the right shoulder revealed a SLAP tear for which he has been evaluated by orthopaedics. He has continued to struggle with imbalance as well as neck pain and weakness in the right upper extremity. He has been out of work since his injury. He follows up with us for additional evaluation.

Victor has continued to struggle with discomfort in the neck. He recently underwent an epidural steroid injection, which helped improve some of his neck and right-sided trapezius region discomfort. He states that he has intolerance to cold sensation across his neck and arms. He has been struggling with intermittent headaches. He still ambulates with the aid of a cane for balance. He has been awakened multiple times with neck discomfort. He was unable to tolerate Lyrica and Neurontin.

On physical examination, he still has 4+/5 right deltoid, bicep, tricep, and hand intrinsic weakness. All other muscle groups are 5/5. He has decreased sensation to light touch in the right upper extremity. His incision is well healed. He ambulates with a careful gait with the aid of a cane.

IMPRESSION/PLAN: Victor Benjamin continues to struggle with difficulties from his spinal cord injury. All in all, he is better than his preoperative condition, but he is still manifesting symptoms. He has benefitted from an epidural steroid injection, and in terms of managing his neck pain, I feel that he would benefit from takeover of care by a pain management specialist.

I do not feel that he is at maximum medical improvement in regards to his cervical spine and spinal cord injury. I would like to see him back in the office in February of 2014, at one year after his surgical procedure. I do recommend obtaining a Functional Capacity Evaluation around that time, so we can determine any additional work restrictions. I recommend continued out-of-work status.

I have discussed all of the above as well as the treatment plan with the case manager who was in the room with the patient today.

Electronically signed by Karl Lozanne, MD at 11/22/2013 06:32

Karl Lozanne, MD

KL/cr
DOC#: 00007924/JOB#: 08115
CC: Rena Spencer, CCM

# COLUMBIA NEUROSURGICAL ASSOCIATES, P.A.

www.columbianeurosurgical.com

Spine & Neurological Surgery

Thomas J. Holbrook, Jr., MD
William M. Rambo, Jr., MD
Randall G. Drye, MD
Scott B. Boyd, MD
Brett C. Gunter, MD
Karl A. Lozanne, MD

720 Rabon Road
Columbia, SC 29203
(803) 462-0423 - (F) 462-0432

Pain Medicine
Eva J. Rawl, MD, Steven B. Storick, MD

132 Sunset Court
W. Columbia, SC 29169
(803) 794-3700 - (F) 794-0322


**OFFICE VISIT**

Patient: Victor G. Benjamin
Chart:
DOB:
Date: 03/11/2014
CNAWT:

Victor Benjamin is a 51-year-old who underwent a C4-C7 anterior cervical discectomy and plated fusion on 2/18/13 after presenting to me following a work-related injury that resulted in spinal cord contusion and right-sided radiculopathies. He had been injured almost two years prior to his surgical intervention. He was subsequently diagnosed with a right shoulder SLAP tear. He initially had significant improvement in right-sided arm symptoms, but the symptoms returned and he had an increase in discomfort in the neck. Conservative treatments as well as an orthopaedic consultation failed to relieve his discomfort. He has a persistence of myelopathy with imbalance and numbness. He continues to struggle with neck pain.

On my initial evaluation, I noted that he had a spinal cord signal change that was small at the C3-4 level. However, on my evaluation, there was not a significant amount of stenosis at that level. I felt that the contusion was a manifestation of his injury in which he had a heavy piece of metal land on his neck and shoulder. He lost consciousness and has also been treated for a post-concussive syndrome. He had significant foraminal stenosis at the adjacent levels, and that is what we treated surgically in hopes of getting him improvement in his radicular symptoms.

Since our last visit, he has been evaluated by Dr. Poletti of Southeastern Spine. He was actually taken to surgery and underwent a posterior C3-C4 decompression and instrumented fusion after what the patient describes was Dr. Poletti's concern of significant C3-4 central canal stenosis that required urgent treatment.

~~Today, he continues to complain of similar symptoms. He is still recuperating from his surgery from~~ three weeks ago.

IMPRESSION/PLAN: At this stage, the care of his cervical spine has been taken over by Dr. Poletti. Unfortunately, they did not bring his most recent MRI from my review. I discussed with Victor, in the company of his wife, his initial evaluation and the concerns I had discussed with them previously. They had multiple questions as to why the C3-4 level had not been treated, and I answered as detailed in my original evaluation. I made myself readily available to review the imaging studies that they had originally. My hope is that he will continue to improve. They appreciated our discussion and will continue to follow-up with Dr. Poletti. I will release him from my care.

Electronically signed by Karl Lozanne, MD at 03/13/2014 08:13

Karl Lozanne, MD

KL/cr
DOC#: 00011471/JOB#: 11721

# COLUMBIA NEUROSURGICAL ASSOCIATES, P.A.

www.columbianeurosurgical.com

Spine & Neurological Surgery

Thomas J. Holbrook, Jr., MD
William M. Rambo, Jr., MD
Randall G. Drye, MD
Scott B. Boyd, MD
Brett C. Gunter, MD
Karl A. Lozanne, MD

720 Rabon Road
Columbia, SC 29203
(803) 462-0423 - (F) 462-0432

132 Sunset Court
W. Columbia, SC 29169
(803) 794-3700 - (F) 794-0322

Pain Medicine
Eva J. Rawl, MD, Steven B. Storick, MD


**OFFICE VISIT**

Patient: Victor G. Benjamin
Chart:
DOB:
Date: 08/21/2014
CNAWT:

Victor Benjamin returns to the office today at the repetitive request of his attorney. I was given the impression that the patient was not receiving further care after he had been transitioned to care under a different spine surgeon who performed an operation. He and his wife come to me and inform me that they have actually had continued care under the care of Dr. Poletti as recently as within the last couple of weeks. There has been a plan of care that is being driven by Dr. Poletti evaluations.

Victor continues to complain of pain, including headaches, discomfort towards the right shoulder, neck pain, and right arm pain. He has a persistence of generalized imbalance as a manifestation of his spinal cord injury.

As mentioned before, I do not feel there is anything else to offer from a surgical intervention. Once again, as discussed with Victor and his wife, I have deferred all further treatments to his most recent treating physician, Dr. Poletti. They are frustrated because they were also under that impression and understood this both from the previous visit with me and from the deposition. They are frustrated with the fact that they were not expecting and did not wish to have a follow-up appointment here.

I have nothing else to offer. I wish to transition all further management, recommendations, and treatment, including determination of maximum medical improvement, to his treating physician, Dr. Poletti, who took over his care prior to his most recent surgery. It is my opinion that he has appropriately been referred for care with pain management.

I will release him from my care, once again.

Electronically signed by Karl Lozanne, MD at 08/22/2014 09:10

Karl Lozanne, MD

KL/cr
DOC#: 00017809/JOB#: 18206

CC: []

**KARL A. LOZANNE MD**
**Columbia Neurosurgical Associates, P.A.**
720 Rabon Rd. • Columbia, SC 29203 Phone: (803) 462-0423 Fax: (803) 462-0432
132 Sunset Court • W. Columbia, SC 29169 Phone: (803) 794-3700 Fax: (803) 794-0322

08/13/2014

## PHYSICAL THERAPY ORDER

Patient Name: VICTOR G BENJAMIN

Frequency: 1 time(s) a week

Duration:

Diagnosis: Cervical Spondylosis

Specific Orders FCE

Precautions/ Restrictions:

Insurance Authorization: Sedgwick CMS

Appt Date and Time:

*I certify that the above ordered physical therapy medically necessary

Physician: KARL A. LOZANNE MD

Signature: Karl Lozanne, MD

December 14, 2015

Chandler Law Firm
Attn: Jeff Chandler
PO Drawer 1889
Myrtle Beach, SC 29578

RE: Victor Benjamin DOB: DOI: 06-15-2011

Dear Mr. Chandler:

After careful review of all of the relevant diagnostic imaging and testing as well as physical examination of Mr. Benjamin I hold the opinion he has suffered physical brain damage the severity of which renders him incapable of returning to any form of gainful employment. The physical brain damage has left Mr. Benjamin with chronic headaches, Epilepsy, PTSD, and Dementia.

Further, Mr. Benjamin sustained an injury to his spinal cord (myelomalacia) which would be referred to as incomplete quadriparesis or as a form of incomplete quadriplegia. He has and does suffer from a progressive loss of use of his upper extremities and is unable to use his hands normally for fine motor actives. He is unable to ambulate normally due to this condition and walks with an altered gait using a four prong cane for stabilization and balance.

From this condition, again, he is rendered incapable of returning to any form of gainful employment.

Mr. Benjamin will require life long medical management to treat and control his various conditions to include: medications, interventional injections, diagnostic testing, physical rehabilitation, office visits and related care.

My opinions above are stated to a reasonable degree of medical certainty.

Dr. George Sandoz Date 12/16/15

cc: file

2376 Cypress Circle, Suite 200, Conway, SC 29526 Phone: 843-234-8950 Fax: 843-234-8951

(612)

## Encounters and Procedures

Clinical Encounter Summaries

**CONWAY HOSPITAL COMMUNITY SERVICES**
2376 Cypress Circle #200
CONWAY, SC 29526-8747
Phone: (843) 234-8950
Fax: (843) 234-8951

**Encounter Summary - Progress Note**
Date Printed: 02/02/2016

This fax may contain legally privileged health information and is intended for the sole use of the intended recipient. You are hereby notified that the disclosure, or other unlawful use of this health information is prohibited.

If you received this fax in error visit www.athenahealth.com/NotMyFax to notify the sender and confirm that the information will be destroyed. If you do not have internet access, please call 1-888-482-8436 to notify the sender and confirm that the information will be destroyed. [ID:644779-H-116021

| | |
|---|---|
| **Patient** | Benjamin, Victor (53 YR, M) |
| **DOB** | |

Patient Demographics:

| | | | |
|---|---|---|---|
| **Address** | 1841 Holmes<br>Sumter, SC 29153 | **Home Phone** | (803) 428-3352 |
| | | **Work Phone** | |

Encounter Notes:

| | |
|---|---|
| **Encounter Reason/Date** | dizziness, neck pain<br><br>refill of medications<br>01/11/2016 - 09:00AM - CPG Neurology @ Cypress Circle |
| **History of Present Illness** | **Concussion/Head Injury**<br>Reported by patient.<br><br>Mechanism of injury: struck in head by object, type of object:50 lbs<br>Onset/Timing: other:work<br>Context: no prior concussions<br>Symptoms: **loss of consciousness; headache; neck pain; nausea/vomiting; dizziness; blurred vision; balance problems; feeling like in a fog; difficulty concentrating; difficulty remembering; confusion; irritability;** ED<br>Notes: no new seizure controled pain difficult with left side neck pain |
| **Review of Systems** | Patient reports **convulsions, weakness, muscle twitching, cramps, vertigo, dizziness, loss of hearing, tinnitus, imbalance or falling, and difficulty with gait or walking** but reports no speech disorder; **history of seizure no new event.** He reports **muscle aches, muscle weakness, arthralgias/joint pain, back pain, and swelling in the extremities.** He reports **depression and sleep disturbances.** He reports no fever. He reports no dry eyes. He reports no frequent nosebleeds. He reports no sore throat. He reports no chest pain. He reports no cough. He reports no bruising. |
| **Vitals** | 01/11/2016 09:12 am<br>**Pulse:** 84 bpm; **RR:** 14; **Wt:** 176 lbs<br>**BP:** 126/82; **BMI:** 23.9; **Ht:** 6 ft |
| **Results/Interpretations** | None recorded. |
| **Physical Exam** | Patient is a 53-year-old male.<br><br>**Constitutional:** Weight: **thin.** Ambulation: **ambulates w/ cane.**<br><br>**Head:** Size/Trauma: normocephalic.<br><br>**Mental Status:** Orientation oriented to person, place, problem, and time. Mood/Affect: **depressed.** Language: can appropriately name objects. Memory: recent memory intact. Fund of Knowledge: current events.<br><br>**Neck:** Appearance/Palpation/Auscultation: no carotid bruits.<br><br>**Heart:** Rate And Rhythm: RRR. |

**Skin:** Extremity Edema Right none. Extremity Edema Left none.

**Cranial Nerves:** CN II Right: pupil reactive to light and dark. CN II Left: pupil reactive to light and dark. CN V Right: normal sensation. CN V Left: normal sensation. CN VII Right: normal facial expression. CN VII Left: normal facial expression. CN VIII Right: **decreased hearing to finger rub.** CN VIII Left: **decreased hearing to finger rub.** CN IX, X: normal swallowing. CN XI Right: normal sternocleidomastoid. CN XI Left: normal sternocleidomastoid. CN XII: no tremors of the tongue.

**Spine:** Cervical Spine: **tenderness.** Back: **tenderness.**

**Motor Exam:** Right Upper Extremity: normal tone. Left Upper Extremity: normal tone.

**Reflexes:** Reflexes Right: **biceps 3/4, triceps 3/4, brachial radialis 3/4, patellar 3/4,** and **achilles 3/4.** Reflexes Left: **biceps 3/4, triceps 3/4, brachial radialis 3/4, patellar 3/4,** and **achilles 3/4.** Plantar Reflex Right: response downgoing. Plantar Reflex Left: response downgoing. Coordination: normal finger-to-nose. Sensation: **decreased light touch.** Gait/Posture: **wide-based gait.**

**Assessment and Plan**

1. **Late effect of traumatic injury to brain** - doing well continue with difficulty mood control continue with support
   S06.9X0S: Unspecified intracranial injury without loss of consciousness, sequela
   - clonazepam 2 mg tablet - To be submitted on or around 01/12/2016 Take 1 tablet(s) twice a day by oral route. Qty: 60 tablet(s) Refills: 0 Pharmacy: CVS/PHARMACY #7598

2. **Cervical spondylosis** - causing pain syndrome difficulties with ambulation neededing a scooter and causing ED
   M47.812: Spondylosis without myelopathy or radiculopathy, cervical region
   - Cialis 20 mg tablet - Take 1 tablet(s) every day by oral route. Qty: 15 tablet(s) Refills: 5 Pharmacy: CVS/PHARMACY #7598

3. **Lumbar spondylosis** - Causing chronic pain syndrome stressed compliance with mes rx for next 3 months given
   M47.896: Other spondylosis, lumbar region
   - oxycodone-acetaminophen 10 mg-325 mg tablet - Take 1 tablet(s) twice a day by oral route for 30 days. Qty: 60 tablet(s) Refills: 0 Pharmacy: CVS/PHARMACY #7598
   - diclofenac 1.5 % topical drops - To be submitted on or around 01/12/2016 APPLY 40 DROPS TO THE AFFECTED KNEE(S) BY TOPICAL ROUTE 4 TIMES PER DAY Qty: 360 mL Refills: 0 Pharmacy: CVS/PHARMACY #7598

4. **Posttraumatic seizure** - No new event since control with use of Vimpat
   R56.1: Post traumatic seizures
   - Vimpat 100 mg tablet - Take 1 tablet(s) by oral route prn intercourse. Qty: 15 tablet(s) Refills: 5 Pharmacy: CVS/PHARMACY #7598

Discussion

**Patient Instructions**

FOLLOW UP IN 3 MONTHS

**Discussion Notes**

Discussed pain management; diversion misuse or overuse of medication. Aware that noncompliance with therapy will result in discharge and not providing any further treatment with medications.

Return to Office

- to see George Sandoz, MD at CPG Neurology @ Cypress Circle on or around 04/11/2016

Patient Medical History:

| | | |
|---|---|---|
| **Allergies List** | Reviewed Allergies<br>**DEMEROL** | |
| **Medications** | Reviewed Medications | |
| | **amlodipine 5 mg tablet** | 12/25/15 filled |
| | **bupropion HCl 75 mg tablet**<br>Take 1 tablet(s) twice a day by oral route. | 01/11/16 entered |
| | **Cialis 20 mg tablet**<br>Take 1 tablet(s) every day by oral route. | 01/11/16 prescribed |
| | **clonazepam 2 mg tablet**<br>Take 1 tablet(s) twice a day by oral route. | 01/12/16 prescribed |

| | | |
|---|---|---|
| | **diazepam 10 mg tablet**<br>Take 1 tablet(s) 3 times a day by oral route. | 01/11/16 entered |
| | **diclofenac 1.5 % topical drops**<br>APPLY 40 DROPS TO THE AFFECTED KNEE(S) BY TOPICAL ROUTE 4 TIMES PER DAY | 01/12/16 prescribed |
| | **Lexapro 10 mg tablet**<br>Take 1 tablet(s) every day by oral route. | 01/11/16 entered |
| | **oxycodone-acetaminophen 10 mg-325 mg tablet**<br>Take 1 tablet(s) twice a day by oral route for 30 days.<br>**Internal Note:** rx x 2 given | 01/11/16 prescribed |
| | **Vascepa 1 gram capsule**<br>Take 2 capsule(s) twice a day by oral route. | 01/11/16 entered |
| | **Vimpat 100 mg tablet**<br>Take 1 tablet(s) by oral route prn intercourse. | 01/11/16 prescribed |
| **Family History** | Reviewed Family History<br>Father • Heart disease (died age: 76) | |
| **Past Medical History** | Reviewed Past Medical History<br>Anxiety Disorder: Y<br>Arthritis: Y<br>Depression: Y<br>Epilepsy/Seizures: Y<br>Head Trauma/Injury: Y - 2011<br>Hypertension: Y<br>Migraines: Y<br>Muscle, Joint, or Bone Problems: Y<br>Neck Injury: Y | |
| **Vaccine History** | None recorded. | |

Electronically Signed by: GEORGE SANDOZ, MD

Encounter Date: 01/11/2016

2376 Cypress Circle • Suite 200, Conway, SC 29526
DEA#: BS3769821 George Mariano Robert Sandor Lic.#20125 NPI#: 1013975010

Name: Victor Benjamin 1/11/16
Address: Date:
Do Not fill until 2/21/16
Oxycodone/Acetaminophen 10/325
TPO tid
#90

Dispense As Written M.D. Substitution Permitted M.D.
Refill ___ times PRN NR

---

Neurology @ Cypress Circle
2376 Cypress Circle • Suite 200, Conway, SC 29526
DEA#: BS3769821 George Mariano Robert Sandor Lic.#20125 NPI#: 1013975010

Name: Victor Benjamin
Address: Date: 1/11/16
Do Not fill until 3/21/16
Oxycodone/Acetaminophen 10/325
#90

Dispense As Written M.D. Substitution Permitted M.D.
Refill ___ times PRN NR

---

(843) 234-8950 Fax: (843) 234-8951

Conway Physicians Group

CPG Neurology @ Cypress Circle
2376 Cypress Circle • Suite 200, Conway, SC 29526
DEA#: BS3769821 George Mariano Robert Sandor Lic.#20125 NPI#: 1013975010

Name: Benjamin Victor 1/11/16
Address: Date:
ESE lumbar
Dc Solo

Dispense As Written M.D. Substitution Permitted M.D.
Refill ___ times PRN NR

---

(843) 234-8950 Fax: (843) 234-8951

Conway Physicians Group

CPG Neurology @ Cypress Circle
2376 Cypress Circle • Suite 200, Conway, SC 29526
DEA#: BS3769821 George Mariano Robert Sandor Lic.#20125 NPI#: 1013975010

Name: Victor Benjamin
Address: Date: 1/11/16
Scooter
for the bathroom

Dispense As Written M.D. Substitution Permitted M.D.
Refill ___ times PRN NR

---

Lumbar DD
TO: Melissa Fax (616) Lita Benjamin for Victor Benjamin

TBJ

Conway Physicians Group • 2376 Cypress Cl. #200, CONWAY SC 29526-8747

**BENJAMIN, VICTOR (id #185319, dob:**

## Encounter Summary

Last amended by George Sandoz, MD on 02/25/2016 at 11:37am

### Chief Complaint

headaches, anxiety
Follow Up: Cervical spondylosis
Follow Up: Late effect of traumatic injury to brain
serious anxiety and panic attacks and headaches

### Vitals

None recorded.

### Problems

- Migraine
- Cervical spondylosis
- Lumbar spondylosis
- Post traumatic seizure
- Late effect of traumatic injury to brain

### Medications

Medications not reviewed (last reviewed 01/11/2016)

amlodipine 5 mg tablet — 02/18/16 filled

bupropion HCl 75 mg tablet
Take 1 tablet(s) twice a day by oral route — 01/21/16 filled

Cialis 20 mg tablet
Take 1 tablet(s) every day by oral route — 02/25/16 prescribed

clonazepam 2 mg tablet
Take 1 tablet(s) twice a day by oral route — 02/25/16 prescribed

diazepam 10 mg tablet
Take 1 tablet(s) 3 times a day by oral route — 01/11/16 entered

diclofenac 1.5 % topical drops
APPLY 40 DROPS TO THE AFFECTED KNEE(S) BY TOPICAL ROUTE 4 TIMES PER DAY — 02/25/16 prescribed

Lexapro 10 mg tablet
Take 1 tablet(s) every day by oral route — 01/11/16 entered

oxycodone-acetaminophen 10 mg-325 mg tablet
Take 1 tablet(s) twice a day by oral route for 30 days — 02/25/16 prescribed

pravastatin 20 mg tablet — 02/10/16 filled

Vascepa 1 gram capsule
Take 2 capsule(s) twice a day by oral route — 01/11/16 entered

Vimpat 100 mg tablet
Take 1 tablet(s) twice a day by oral route prn intercourse — 02/25/16 prescribed

BENJAMIN, VICTOR (id #185319, dob: 04/19/1962)

## Allergies

Allergies not reviewed (last reviewed 01/11/2016)
DEMEROL

## Past Medical History

Past Medical History not reviewed (last reviewed 01/11/2016)
Anxiety Disorders: Y
Arthritis: Y
Depression: Y
Epilepsy/Seizures: Y
Head Trauma/Injury: Y - 2011
Hypertension: Y
Migraines: Y
Muscle, Joint, or Bone Problems: Y
Neck Injury: Y

## Social History

Social History not reviewed (last reviewed 01/11/2016)
Neurology
Smoking Status: Never smoker
Live alone or with others?: with others
General stress level: High
Exercise level: None
Alcohol Intake: None
Caffeine Intake: None
Accident Related Injury: Y

## Family History

Family History not reviewed (last reviewed 01/11/2016)
Father - Heart disease (died age: 76)

## Surgical History

Surgical History not reviewed (last reviewed 01/11/2016)
Neck Surgery - 2013 - Jan 2014
Right wrist surgery 2011

## QM

Provider: gsandoz
Programs: MU Medicare - Year 5 - 2016, PQRS 2016 (EHR and Registry)
Last updated 02/25/2016

| Measure | Status |
|---|---|
| Colorectal Cancer Screening | Needs Data |
| Documentation of current medications | Needs Data (1/1) |
| Hypertension screening and follow-up | Out of Range |
| BMI Screening and Follow-Up (Date of follow-up must be on or <= 6 mo. before BMI | Satisfied |
| Patients view or download their health info | Satisfied |
| Provide patient information | Satisfied |
| Tobacco screening and cessation intervention | Satisfied |

## ROS

Patient reports bladder symptoms, numbness, confusion, memory loss, convulsions, syncope, weakness, cramps, vertigo, loss of hearing, tinnitus, and imbalance or falling. He reports muscle aches and arthralgias/joint pain. He reports depression. He reports swollen glands. He reports no fever. He reports no dry eyes. He reports no ear pain. He reports no frequent nosebleeds. He reports no sore throat. He reports no chest pain. He reports no cough.

**BENJAMIN, VICTOR (id #185319, dob: )**

## HPI

**Concussion/Head Injury**
Reported by patient.

Mechanism of injury: struck in head by object, type of object.
Context: no prior concussions; amnesic for events prior to injury; amnesic for events after injury lasting
Symptoms: loss of consciousness; pressure in head; neck pain; nausea/vomiting; balance problems; sensitivity to light; sensitivity to noise; feeling like in a fog; don't feel right; difficulty concentrating

**Headache**
Reported by patient.

Location: orbital; bilateral; including neck; occipital; frontal
Quality: similar to previous headaches; throbbing; tightness; pain; piercing/stabbing (lancinating)
Severity: severe
Duration: constant
Onset/Timing: still present
Context: related to trauma
Aggravating factors: loud noise
Alleviating factors: sleep; medication
Associated Symptoms: nausea; vomiting; constipation; diarrhea; rhinorrhea; photophobia; blind spots; tearing/watery eyes; confusion; slurred speech; loss of feeling or sensation

## Physical Exam

Patient is a 53-year-old male.

Constitutional: Weight: well-nourished. Ambulation: ambulates w/ cane.

Head: Size/Trauma: normocephalic.

Mental Status: Orientation: oriented to person. Mood/Affect: anxiety and depressed. Language: repeats phrases. Memory: recent memory impaired. Fund of Knowledge: past history.

Skin: Inspection: no rashes. Extremity Edema Right: none. Extremity Edema Left: none.

Cranial Nerves: CN II Right: pupil reactive to light and dark. CN II Left: pupil reactive to light and dark. CN III, IV, VI: no nystagmus; extraocular muscle strength normal, and normal ocular motility pursuits. CN V Right: normal sensation. CN V Left: normal sensation. CN VII Right: normal facial expression. CN VII Left: normal facial expression. CN VIII Right: decreased hearing to finger rub. CN VIII Left: decreased hearing to finger rub. CN IX, X: normal swallowing. CN XI Right: normal sternocleidomastoid. CN XI Left: normal sternocleidomastoid. CN XII: tongue protrudes midline.

Motor Exam: Right Upper Extremity: normal bulk and tone. Left Upper Extremity: normal bulk and tone. Right Lower Extremity: normal bulk. Left Lower Extremity: normal bulk.

Reflexes: Reflexes Right: biceps 3/4, triceps 3/4, brachial radialis 3/4, patellar 3/4, and achilles 3/4. Reflexes Left: biceps 3/4, triceps 3/4, brachial radialis 3/4, patellar 3/4, and achilles 3/4. Plantar Reflex Right: Babinski present. Plantar Reflex Left: response downgoing. Coordination: unable to perform finger-to-nose. Sensation: normal vibration. Gait/Posture: lurch forward and antalgic gait.

## Assessment / Plan

1. Late effect of traumatic injury to brain - Continue with difficulty mood control, withdrawal from sudden stop lexapro since decreased done better; still issue with feeling overcoming him present with and without meds, from all this injury suffered patient is totally and permanently disabled and will require medication and therapy for life
S06.9X0S: Unspecified intracranial injury without loss of consciousness, sequela
- clonazepam 2 mg tablet - Take 1 tablet(s) twice a day by oral route. Qty: 60 tablet(s) Refills: 5 Pharmacy: CVS/PHARMACY #7598

2. Cervical spondylosis - causing pain syndrome difficulties with ambulation needing a scooter and causing ED; [redacted] a soft collar to control his symptoms
M47.812: Spondylosis without myelopathy or radiculopathy, cervical region
- CERVICAL SPONDYLOSIS: CARE INSTRUCTIONS
- NECK ARTHRITIS: EXERCISES
- Cialis 20 mg tablet - Take 1 tablet(s) every day by oral route. Qty: 15 tablet(s) Refills: 5 Pharmacy: CVS/PHARMACY #7598

**BENJAMIN, VICTOR (id #185319, dob:**

3. Migraine
G43.909: Migraine, unspecified, not intractable, without status migrainosus

4. Lumbar spondylosis - Causing chronic pain syndrome stressed compliance with mes Rx for next 3 months given, needs medication as well for esf lumbar spine to control his pain that interferers with his ADL's and social interaction with wife and family
M47.896: Other spondylosis, lumbar region
- diclofenac 1.5 % topical drops - APPLY 40 DROPS TO THE AFFECTED KNEE(S) BY TOPICAL ROUTE 4 TIMES PER DAY. Qty: 360 mL Refills: 0 Pharmacy: CVS/PHARMACY #7598
- oxycodone-acetaminophen 10 mg-325 mg tablet - Take 1 tablet(s) twice a day by oral route for 30 days. Qty: 60 tablet(s) Refills: 0 Pharmacy: CVS/PHARMACY #7598 Note to Pharmacy: Do not fill until 4-24-17
- oxycodone-acetaminophen 10 mg-325 mg tablet - Take 1 tablet(s) twice a day by oral route for 30 days. Qty: 60 tablet(s) Refills: 0 Pharmacy: CVS/PHARMACY #7598 Note to Pharmacy: Do not fill until 3-25-17
- oxycodone-acetaminophen 10 mg-325 mg tablet - Take 1 tablet(s) twice a day by oral route for 30 days. Qty: 60 tablet(s) Refills: 0 Pharmacy: CVS/PHARMACY #7598

5. Posttraumatic seizure - No new event since control with use of Vimpat
R56.1: Post traumatic seizures
- Vimpat 100 mg tablet - Take 1 tablet(s) twice a day by oral route pm intercourse. Qty: 60 tablet(s) Refills: 5 Pharmacy: CVS/PHARMACY #7598

Discussion

Patient Instructions
FOLLOW UP IN 3 MONTHS

Discussion Notes
Discussed pain management; diversion misuse or overuse of medication. Aware that noncompliance with therapy will result in discharge and not providing any further treatment with medications.

Return to Office
- George Sandoz, MD for Established Patient 15 at CPG Neurology @ Cypress Circle on 04/11/2016 at 08:45 AM
- to see George Sandoz, MD at CPG Neurology @ Cypress Circle on or around 05/25/2016

Amendment Sign-Off
Encounter signed-off by George Sandoz, MD, 02/25/2016.

Encounter performed and documented by George Sandoz, MD
Encounter reviewed & signed by George Sandoz, MD on 02/25/2016 at 11:27am
Amendment closed by George Sandoz, MD on 02/25/2016 at 11:32am
Amendment closed by George Sandoz, MD on 02/25/2016 at 11:37am

(843) 234-6051

Fax (843) 234-6051

CPG Neurology @ Cypress Circle
2376 Cypress Circle - Suite 200, Conway, SC 29526
DEA#: BS3789321 George Mariano Robert Sandoz Lic#20125 NPI#: 1973873910

NAME Victor Bernardino

ADDRESS _____ DATE 2/25/16

Cervical Collar, Soft

Dx M47.812

Lab

Refill _____ times PRN NR

Dispense As Written M.D. Signature required M.D.

February 12, 2016

JEFFREY C. CHANDLER, P.C.
FEIN 20-0523540

VIA FAX & US MAIL (843-234-8951)

Conway Hospital Community Services
Attn: Dr. George Sandoz
2376 Cypress Circle # 200
Conway, SC 29528

Re: Victor Benjamin DOB: DOA: 06-15-2011

Dear Dr. Sandoz:

As you know, I represent Mr. Benjamin regarding his workers compensation claim that you have provided treatment for. I am in receipt of your office notes to date. For your office note dated October 01, 2015 Mr. Benjamin presented to your office with complaints increased neck pain. At that same visit you provided Mr. Benjamin with an order for a motorized scooter to aid him with decreasing his ambulation.

1.) Does Mr. Benjamin require the use of a motorized scooter to aid him with ambulation due to the injuries he sustained in his 06-15-2011 work accident?

Yes

2.) Mr. Benjamin has indicated to our office that an epidural steroid injection was ordered at his October 1, 2015 office visit. I have reviewed your dictation and do not see a reference that this was ordered. Please advise as to the current treatment plan.

Lumbar ESI Pending

3.) A lumbar epidural injection was ordered on January 11, 2016. Is the need for the injection causally related to his work injury which occurred on 06-15-2011?

Yes

Dr. George Sandoz 3/2/16
Date

My opinions are to a degree of medical certainty.

P.O. Drawer 1889 • Myrtle Beach, SC 29578-1889
Office (843) 448-4357 • Fax (843) 448-4005 • jeffchandler@aol.com • www.jeffchandlerlaw.com

Best Regards,

Jeff Chandler

cc: file
enclosures: as noted

## Imaging Results

# X-RAY, CERVICAL SPINE, W/AP AND LATERAL FLEXION AND EXTENSION

(#1227911, 04/11/2016 12:00am)

Sent 04/11/2016 15:42:54, Page - 1

CONWAY MEDICAL CENTER
PO BOX 829
300 SINGLETON RIDGE ROAD
CONWAY, SC 29526-0829
(843) 347-8132

Name: BENJAMIN,VICTOR
Phys: Sandoz,George MD
DOB: Age: Sex: M
Acct: Loc: RAD
Exam Date: 04/11/2016 Status: REG CLI
Radiology No: 00310143
Unit No: M000541357
Patient Phone: (843)428-3352
CPT4 Code:

ADMITTING DX: CERVICAL SPONDYLOSIS

| EXAM# | TYPE/EXAM | RESULT |
|---|---|---|
| 001424403 | RAD/COMPLETE C/SPINE W/ FLEX/EX | |

Indication: 53-year-old male car accident 2011, previous surgery, left-sided neck pain worsening over last few months.

Exam: Cervical Spine With Flexion-Extension

Comparison: None.

Findings: AP, AP odontoid, lateral and neutral, flexion and extension views were performed. The prevertebral soft tissues are normal. There is posterior fusion with interpedicular screws and stabilizing rods across the C3-4 disc. ACDF from C4 to C7. Vertebral bodies are aligned and of normal height. There is a subtle retrolisthesis of C3 on C4. This is stable on flexion-extension.

*Impression: Postoperative changes. C3-4 degenerative change. No instability.*

*Electronically Signed By: Russell Derrick*

** REPORT SIGNED IN OTHER VENDOR SYSTEM 04/11/2016 **
Reported By: RUSSELL L. DERRICK MD

CC: George Sandoz MD

Technologist: AMY BAKER, R.T.(R)
Transcribed Date/Time: 04/11/2016 (1525)
Transcriptionist: RALLEN
Printed Date/Time: 04/11/2016 (1525)

# Encounters and Procedures

Clinical Encounter Summaries

**CONWAY HOSPITAL COMMUNITY SERVICES**
Admin/CBO
300 Singleton Ridge Rd
CONWAY, SC 29526-1234
Phone: (843) 341-7111
Fax:

**Encounter Summary - Progress Note**
From Provider: GEORGE SANDOZ, MD
Date Printed: 06/22/2016

To Provider:

| | |
|---|---|
| Patient | BENJAMIN, VICTOR (54 YR, M) |
| DOB | |

Patient Demographics:

| | | | |
|---|---|---|---|
| Address | 1841 HOLMAN RD<br>SUMTER, SC 29153 | Home Phone | (803) 428-3352 |
| | | Work Phone | (803) 484-1560 |

Encounter Notes:

| | |
|---|---|
| Encounter Reason/Date | None recorded.<br>04/11/2016 - 08:45AM - CPG Neurology @ Cypress Circle |
| History of Present Illness | **Concussion/Head Injury**<br>Reported by patient.<br><br>Mechanism of Injury: struck in head by object, type of object:<br>Context: no prior concussions; amnesic for events prior to injury; amnesic for events after injury lasting<br>Symptoms: loss of consciousness; pressure in head; neck pain; nausea/vomiting; balance problems; sensitivity to light; sensitivity to noise; feeling like in a fog; don't feel right; difficulty concentrating<br><br>**Headache**<br>Reported by patient.<br><br>Location: orbital; bilateral; including neck; occipital; frontal<br>Quality: similar to previous headaches; throbbing; tightness; pain; piercing/stabbing (lancinating)<br>Severity: severe<br>Duration: constant<br>Onset/Timing: still present<br>Context: related to trauma<br>Aggravating factors: loud noise<br>Alleviating factors: sleep; medication<br>Associated Symptoms: nausea; vomiting; constipation; diarrhea; rhinorrhea; photophobia; blind spots; tearing/watery eyes; confusion; slurred speech; loss of feeling or sensation |
| Review of Systems | Patient reports bladder symptoms, numbness, confusion, memory loss, convulsions, syncope, weakness, cramps, vertigo, loss of hearing, tinnitus, and imbalance or falling. He reports muscle aches and arthralgias/joint pain. He reports depression. He reports swollen glands. He reports no fever. He reports no dry eyes. He reports no ear pain. He reports no frequent nosebleeds. He reports no sore throat. He reports no chest pain. He reports no cough. |
| Vitals | 04/11/2016 09:30 am |

| | | | | | |
|---|---|---|---|---|---|
| Pulse: | 69 bpm | Wt: | 176 lbs | BP: | 144/87 |
| BMI: | 23.9 | Ht: | 6 ft | | |

| | |
|---|---|
| Results/Interpretations | None recorded. |
| Physical Exam | Patient is a 53-year-old male. |

**Constituti** Weight: well-nourished. Ambulation: ami es w/ cane.

**Head:** Size/Trauma: normocephalic.

**Mental Status:** Orientation oriented to person. Mood/Affect: anxiety and depressed. Language: repeats phrases. Memory: recent memory impaired. Fund of Knowledge: past history.

**Skin:** Inspection: no rashes. Extremity Edema Right none. Extremity Edema Left none.

**Cranial Nerves:** CN II Right: pupil reactive to light and dark. CN II Left: pupil reactive to light and dark. CN III, IV, VI: no nystagmus, extraocular muscle strength normal, and normal ocular motility pursuits. CN V Right: normal sensation. CN V Left: normal sensation. CN VII Right: normal facial expression. CN VII Left: normal facial expression. CN VIII Right: decreased hearing to finger rub. CN VIII Left: decreased hearing to finger rub. CN IX, X: normal swallowing. CN XI Right: normal sternocleidomastoid. CN XI Left: normal sternocleidomastoid. CN XII: tongue protrudes midline.

**Motor Exam:** Right Upper Extremity: normal bulk and tone. Left Upper Extremity: normal bulk and tone. Right Lower Extremity: normal bulk. Left Lower Extremity: normal bulk.

**Reflexes:** Reflexes Right: biceps 3/4, triceps 3/4, brachial radialis 3/4, patellar 3/4, and achilles 3/4. Reflexes Left: biceps 3/4, triceps 3/4, brachial radialis 3/4, patellar 3/4, and achilles 3/4. Plantar Reflex Right: Babinski present. Plantar Reflex Left: response downgoing. Coordination: unable to perform finger-to-nose. Sensation: normal vibration. Gait/Posture: lurch forward and anti algic gait.

**Document Review**

N/A

**Assessment and Plan**

1. **Late effect of traumatic injury to brain** - Continue with difficulty mood control, withdrawal from sudden stop lexapro since decreased done better, still issue with feeling overcoming him present with and without meds, from all this injury suffered patient is totally and permanently disabled and will require medication and therapy for life
   S06.9X0S: Unspecified intracranial injury without loss of consciousness, sequela
   - Valium 10 mg tablet - Take 1 tablet(s) 3 times a day by oral route. Qty: 90 tablet(s) Refills: 5 Pharmacy: CVS/PHARMACY #7598

2. **Lumbar spondylosis** - Causing chronic pain syndrome stressed compliance with mes rx for next 3 months given, needs medication as well for esi lumbar spine to control his pain that interfolers with his ADL's and social interaction with wife and family
   M47.896: Other spondylosis, lumbar region
   - diclofenac 1.5 % topical drops - APPLY 40 DROPS TO THE AFFECTED KNEE(S) BY TOPICAL ROUTE 4 TIMES PER DAY Qty: 360 mL Refills: 0 Pharmacy: CVS/PHARMACY #7598
   - oxycodone-acetaminophen 10 mg-325 mg tablet - Take 1 tablet(s) twice a day by oral route for 30 days. Qty: 60 tablet(s) Refills: 0 Pharmacy: CVS/PHARMACY #7598 Note to Pharmacy: Do not fill until 4-24-17
   - oxycodone-acetaminophen 10 mg-325 mg tablet - Take 1 tablet(s) twice a day by oral route for 30 days. Qty: 60 tablet(s) Refills: 0 Pharmacy: CVS/PHARMACY #7598 Note to Pharmacy: Do not fill until 5-23-16
   - oxycodone-acetaminophen 10 mg-325 mg tablet - Take 1 tablet(s) twice a day by oral route for 30 days. Qty: 60 tablet(s) Refills: 0 Pharmacy: CVS/PHARMACY #7598 Note to Pharmacy: Do not fill until 6-20-16

3. **Cervical spondylosis** - causing pain syndrome difficulties with ambulation needing a scooter and causing ED, will need to get a soft collar to control his symptoms, since lasst feww months symptoms continue to come and go specially on left side persistent as well into right will see findings on xray
   M47.812: Spondylosis without myelopathy or radiculopathy, cervical region
   - Cialis 20 mg tablet - Take 1 tablet(s) every day by oral route. Qty: 15 tablet(s) Refills: 5 Pharmacy: CVS/PHARMACY #7598
   - X-RAY, CERVICAL SPINE, W/AP AND LATERAL FLEXION AND EXTENSION

     Indication: cervical spondylosis with myelopathy

4. **Posttraumatic seizure** - No new event since control with use of Vimpat
   R56.1: Post traumatic seizures
   - Vimpat 100 mg tablet - Take 1 tablet(s) twice a day by oral route prn intercourse. Qty: 60 tablet(s) Refills: 5 Pharmacy: CVS/PHARMACY #7598

5. **Migraine** - Doing well with current therapy
   G43.909: Migraine, unspecified, not intractable, without status migrainosus —

## Discussion

**Patient Instructions**

FOLLOW UP IN 3 MONTHS

**Discussion Notes**

Discussed pain manageme ( 6 2 6 ) 1 misuse or overuse of medication. Aware that

nonc[illegible]ance with therapy will result in discharge [illegible] not providing any further treatment with medications.Verified the controlled substance prescription history of members via SCRIPTS before issuing prescriptions for opioids was 10:01AM on April11, 2016.

**Return to Office**

- George Sandoz, MD for Established Patient-15 at CPG Neurology @ Cypress Circle on 07/11/2016 at 10:45 AM

**Patient Medical History:**

| | | |
|---|---|---|
| **Allergies List** | Reviewed Allergies | |
| | DEMEROL | |
| **Medications** | Reviewed Medications | |
| | **amlodipine 5 mg tablet** | 03/21/16 filled |
| | **bupropion HCl 75 mg tablet**<br>Take 1 tablet(s) twice a day by oral route. | 01/21/16 filled |
| | **Cialis 20 mg tablet**<br>Take 1 tablet(s) every day by oral route. | 04/11/16 prescribed |
| | **clonazepam 2 mg tablet**<br>Take 1 tablet(s) twice a day by oral route. | 02/25/16 prescribed |
| | **diclofenac 1.5 % topical drops**<br>APPLY 40 DROPS TO THE AFFECTED KNEE(S) BY TOPICAL ROUTE 4 TIMES PER DAY | 04/11/16 prescribed |
| | **Lexapro 10 mg tablet**<br>Take 1 tablet(s) every day by oral route. | 01/11/16 entered |
| | **oxycodone-acetaminophen 10 mg-325 mg tablet**<br>Take 1 tablet(s) twice a day by oral route for 30 days. | 04/11/16 prescribed |
| | **pravastatin 20 mg tablet** | 03/08/16 filled |
| | **Valium 10 mg tablet**<br>Take 1 tablet(s) 3 times a day by oral route. | 04/11/16 prescribed |
| | **Vascepa 1 gram capsule**<br>Take 2 capsule(s) twice a day by oral route. | 01/11/16 entered |
| | **Vimpat 100 mg tablet**<br>Take 1 tablet(s) twice a day by oral route prn intercourse. | 04/11/16 prescribed |
| **Family History** | Reviewed Family History | |
| | Father | - Heart disease (died age: 76) |
| **Past Medical History** | Reviewed Past Medical History<br>Epilepsy/Seizures: Y<br>Head Trauma/Injury: Y - 2011<br>Hypertension: Y<br>Migraines: Y<br>Muscle, Joint, or Bone Problems: Y<br>Neck Injury: Y | |
| **Vaccine History** | None recorded. | |

Electronically Signed by: GEORGE SANDOZ, MD



Encounter Date: 04/11/2016

**FLORENCE**
NEUROSURGERY
**& SPINE CENTER**
Andrew H Kiss, MD • William B Nash, MD • James J Brennan, MD
Christopher G Paramore, MD • R Blake King, MD

1204 E. Cheves Street
Florence, SC 29506
phone:(843) 673-0122
fax: (843) 673-0227

**Patient Name:** VICTOR G BENJAMIN
**DOB:**
**Date of Service:** 06/08/2016

## History of Present Illness

The patient is a 54 year old male who returns today for a follow up visit. Patient seen evaluation at the request of Dr. Sandoz regarding possible repeat epidural steroid injections. Patient has history of back pain exacerbated after work injury 2011. He states he had an episode of back pain about 22 years prior to this but it resolved and he did not have any problems until his work injury where he still being hit him and he fell backward. He is having low back pain into the right leg states his pain with activity is a 10 out of 10. He denies any bowel or bladder dysfunction. He does use a cane because he states the leg feels weak on him and he does have numbness down the posterior aspect of the right leg to the calf. Patient has history of cervical surgery with ACDF C4-C7 and is using a soft collar while driving. He also has right carpal tunnel syndrome. Patient has had epidural injections in the past he had one by me in the past and has been through the spine Institute. Patient states that he did get good relief with epidural injections and would like try this again. Patient has tried physical therapy without relief of pain he has been on anti-inflammatories in the past and is now maintained with oxycodone by Dr. Sandoz

## History

**Allergy**
Demerol *ANALGESICS - OPIOID* [Drug allergy]
**Past Medical**
High blood pressure
**Social**
Married, living with spouse with 2 children
Tobacco use: Never smoker
Alcohol use Non Drinker
**Medications**
Simvastatin (20MG Tablet, Taken starting 06/27/2011) Active - Hx Entry.
Hydrocodone-Acetaminophen (5-325MG Tablet, Taken starting 06/27/2011) Active - Hx Entry.
Fish-EPA (1000MG Capsule, Taken starting 06/27/2011) Active - Hx Entry.
**Family**
Hypertension
Myocardial Infarction
**Past Surgical**
Neck Surgery X2 2-2014 & 1-2013

## Review of Systems

**General:** Not Present- Chills, Fever, Night Sweats and Weight Loss.
**HEENT:** Present- Double Vision, Tunnel Vision and Trauma. Not Present- Visual Loss, Hearing Loss, Ear Pain, Nose Bleed and Sore Throat.
**Respiratory:** Present- Shortness of Breath (Sometimes). Not Present- Cough and Hemoptysis.
**Cardiovascular:** Present- Chest Pain (Some) and Pain in lower legs when walking. Not Present- Irregular Heart Beat, Leg Pain and/or Swelling and Swelling of Extremities.
**Gastrointestinal:** Not Present- Abdominal Pain, Black, Tarry Stool, Diarrhea, Incontinence of Stool and Vomiting.
**Male Genitourinary:** Not Present- Blood in Urine, Incontinence and Painful Urination.
**Musculoskeletal:** Present- Joint Pain (Shoulder,Arm,Back,Hip). Not Present- Joint Redness, Joint Swelling and Inflammation.
**Endocrine:** Not Present- Cold Intolerance, Heat Intolerance, Breast Discharge, Irregular/absent menstrual cycle, Possible pregnancy and Recent severe weight gain.
**Hematology:** Not Present- Abnormal Bleeding, Frequent/recurrent infections and Previous bleeding problems (with a surgery).

06/08/2016 09:26 AM
**Pain level:** 10/10
**Temp.:** 98.3 °F **Pulse:** 56 (Regular) **Resp.:** 18 (Unlabored)
**BP:** 144/87 Manual (Sitting, Left Arm, Standard)

## Physical Exam

General: Pleasant gentleman appears stated age she is wearing a soft collar. He is ambulating with a cane

Neck: Supple with no carotid bruits.

Chest: Clear to auscultation.

CV: The heart has a regular rate and rhythm.

NEURO/MUSCULOSKELETAL EXAM

Cognitive: The patient is awake alert and conversant, with fluent speech, normal affect, and fully oriented.

Cranial nerves: Pupils are equal and reactive. Extraocular movements are intact. The face is symmetric. The tongue is midline. Uvula and palate elevate normally. Shoulder shrug is 5/5.

Motor exam: Both upper and lower extremities have normal bulk and normal tone with 5/5 strength throughout, including both grips, biceps, triceps, deltoids, iliopsoas, quadriceps, hamstrings, gastrocnemius, and anterior tibialis motor groups with good range of motion throughout.

Sensory exam: Intact to light touch and pinprick. Patient notes paresthesias right leg no dermatomal loss

Deep tendon reflexes: 2/4

Pathological reflexes: There are no Hoffman signs. There is no clonus.

Coordination: No gross dysmetria.

Gait: No ataxia.

## Assessments & Plans

LUMBAR RADICULOPATHY, CHRONIC (724.4 | M54.16)

CHRONIC BACK PAIN (724.5 | M54.9)

Assessment/Plan Note: Patient seen evaluation. He has chronic back pain into the right leg with numbness. He states his pain as a 10 out of 10. He has had epidural injections in the past and states it did give him good relief he would like to proceed with epidural injection again for pain management. He has felt by Dr. Sandoz and is on oxycodone for pain and has tried anti-inflammatories in the past. He has tried physical therapy without relief. I do think this is reasonable thing the patient did notice improvement. Risks and benefits of epidural injection were discussed patient. He will need transportation home and limited activity for 48 hours post injection.

Cc Dr. Sandoz

*Electronically signed by BARBARA L SARB DO 06/08/2016*

NAME Victor Benjamin DATE 6/8/16

VISIT: Pre-op ☐ 6 wks ☐ 6 mos. ☐ 12 mos. ☐ 18 mos. ☐ 24 mos. ☐

## BACK PAIN QUESTIONNAIRE

N/A ☐

I. For each type of pain below, indicate the severity you felt in the last week:

| | None 0 | Mild 1 | Moderate 2 | Severe 3 |
|---|---|---|---|---|
| Shooting | ☐ | ☐ | ☐ | ☒ |
| Stabbing | ☐ | ☐ | ☐ | ☐ |
| Cramping | ☐ | ☐ | ☐ | ☐ |
| Gnawing | ☐ | ☐ | ☐ | ☒ |
| Aching | ☐ | ☐ | ☐ | ☒ |
| Tender | ☐ | ☐ | ☐ | ☒ |
| Tiring / Exhausting | ☐ | ☐ | ☐ | ☒ |
| Fearful | ☐ | ☐ | ☐ | ☒ |

II. On the diagram below, please indicate with an "X" the severity of your pain in the last week:

No Pain | ——— Worst Possible Pain

III. Which word best describes your pain right now?

No Pain ☐ Mild ☐ Discomforting ☐

Distressing ☐ Horrible ☒ Excruciating ☒

## LEG PAIN QUESTIONNAIRE

N/A ☐

I. For each type of pain below, indicate the severity you felt in the last week:

| | None 0 | Mild 1 | Moderate 2 | Severe 3 |
|---|---|---|---|---|
| Shooting | ☐ | ☐ | ☐ | ☒ |
| Sharp | ☐ | ☐ | ☐ | ☐ |
| Gnawing | ☐ | ☐ | ☒ | ☐ |
| Aching | ☐ | ☐ | ☒ | ☐ |
| Tender | ☐ | ☐ | ☐ | ☐ |
| Tiring / Exhausting | ☐ | ☐ | ☒ | ☐ |
| Fearful | ☐ | ☐ | ☐ | ☐ |

II. On the diagram below, please indicate with an "X" the severity of your pain in the last week:

No Pain | ——— X ——— | Worst Possible Pain

III. Which word best describes your pain right now?

No Pain ☐ Mild ☐ Discomforting ☐

Distressing ☐ Horrible ☐ Excruciating ☐

FLORENCE
NEUROSURGERY
& SPINE CENTER
Andrew H Rhee, MD • William B Nasr, MD • James J Brennan, MD
Christopher G Paramore, MD • R Blake Kline, MD

1204 E. Cheves Street
Florence, SC 29506
phone:(843) 673-0122
fax: (843) 673-0227

**Patient Name:** VICTOR G BENJAMIN
**DOB:**
**Date of Service:** 06/09/2016

## History of Present Illness

The patient is a 54 year old malewho present today for an office procedure. Patient presents for epidural steroid injection he is having back pain into the right leg. He states his pain is a 10 out of 10 with ambulation. He is using a cane. Patient presents for epidural injection for pain management. He denies any weakness or bowel or bladder dysfunction.

Risks and benefits of epidural injection were discussed with patient and informed consent was obtained.

## History

**Allergy**
Demerol *ANALGESICS - OPIOID* [Drug allergy]
**Past Medical**
High blood pressure
**Other Medical History**
LUMBAR RADICULOPATHY, CHRONIC (724.4 | M54.16)
CHRONIC BACK PAIN (724.5 | M54.9)
**Social**
Alcohol use Non Drinker
Tobacco use: Never smoker
Married, living with spouse with 2 children
**Medications**
Simvastatin (20MG Tablet,, Taken starting 06/27/2011) Active.
Hydrocodone-Acetaminophen (5-325MG Tablet,, Taken starting 06/27/2011) Active.
Fish-EPA (1000MG Capsule,, Taken starting 06/27/2011) Active.
**Family**
Hypertension
Myocardial Infarction
**Past Surgical**
Neck Surgery X2 2-2014 & 1-2013

## Review of Systems

**General:** Not Present- Fever.
**Skin:** Not Present- Rash.
**HEENT:** Not Present- Double Vision and Visual Loss.
**Neck:** Not Present- Neck Pain.
**Respiratory:** Not Present- Shortness of Breath.
**Breast:** Not Present- Nipple Discharge.
**Cardiovascular:** Not Present- Chest Pain.
**Gastrointestinal:** Not Present- Bloody Stool.
**Musculoskeletal:** Not Present- Joint Pain.
**Neurological:** Not Present- Incontinence Stool and Incontinence Urine.
**Psychiatric:** Not Present- Anxiety.
**Endocrine:** Not Present- Cold Intolerance, Heat Intolerance, Breast Discharge and Irregular/absent menstrual cycle.
**Hematology:** Not Present- Abnormal Bleeding.

Please see the health history questionnaire for full details of the patient's review of systems, past medical history, and family and social history. The patient is to follow-up with their family physician for any positive review of systems. I have also reviewed all available records and imaging studies.

06/09/2016 01:30 PM
**Pain level:** 10/10
**Temp.:** 97.6 °F **Pulse:** 63 (Regular) **Resp.:** 18 (Unlabored)
**BP:** 159/93 Manual (Sitting, Left Arm, Standard)

## Physical Exam

General: Pleasant gentleman appears stated age mildly positive right SLR test.

Neck: Supple with no carotid bruits.

Chest: Clear to auscultation.

CV: The heart has a regular rate and rhythm.

NEURO/MUSCULOSKELETAL EXAM

Cognitive: The patient is awake alert and conversant, with fluent speech, normal affect, and fully oriented.

Cranial nerves: Pupils are equal and reactive. Extraocular movements are intact. The face is symmetric. The tongue is midline. Uvula and palate elevate normally. Shoulder shrug is 5/5.

Motor exam: Both upper and lower extremities have normal bulk and normal tone with 5/5 strength throughout, including both grips, biceps, triceps, deltoids, iliopsoas, quadriceps, hamstrings, gastrocnemius, and anterior tibialis motor groups with good range of motion throughout.

Sensory exam: Intact to light touch and pinprick.

Deep tendon reflexes: 2/4

Pathological reflexes: There are no Hoffman signs. There is no clonus.

Coordination: No gross dysmetria.

Gait: No ataxia.

## Assessments & Plans

CHRONIC BACK PAIN (724.5 | M54.9)

LUMBAR RADICULOPATHY, CHRONIC (724.4 | M54.16)

**Procedures**
ESI/LUMBAR/CAUDEL (62311)

Assessment/Plan Note: Lumbar Epidural Sterlod Injection (62311)

After risks and benefits were explained to the patient, including bleeding, infection, puncture of spinal fluid space, headache, weakness, numbness or nerve injury, the patient did sign he informed consent for the above procedure. The patient was brought back to the fluoroscopic suite and placed in the prone position on the procedure table. The thoracic, lumbar, and sacral regions were sterilely draped in surgical fashion using Betadine x 3.

A fluoroscopic C-arm was brought into the AP orientation and the L4-L5 interspace was identified. The skin overlying this area was anesthetized using 1cc of 1% Lidocaine preservative free via a 25-gauge needle. A 20-gauge spinal needle was placed in the skin and advanced to the epidural space using loss of resistance technique and the assistance of both AP and lateral fluoroscopic guidance. There was no aspiration of blood or spinal fluid. Once the epidural space was found, 1cc of Omnipaque was injected to confirm needle placement with appropriate flow pattern. Contrast was seen filling the epidural space.

A solution containing 80 mg of Depo-Medrol and 2cc of 1% lidocaine preservative free was created. A 1cc test dose was administered without change in hemodynamic variables. The remainder of the solution was incrementally injected. The needle was removed with the tip intact and a bandage was applied.

The patient was brought to the recovery room and convalesced for approximately 30 minutes time before being discharged to the care of a driver. The patient will be in contact with my office over the next 72 hours regarding progress and will be seen in follow up as directed previously. Patient will be seen in followup in 3 months to assess his progress has an questions concerning return of pain in the interim contact the office for sooner appointment.

*Electronically signed by BARBARA L SARB DO 06/09/2016*

Victory Benjamin

DOB:

REASON AND PURPOSE FOR EVALUATION
Independent Medical Exam

HISTORY: This is a 54-year-old African American gentleman who is here today for an evaluation. He has symptoms consistent with cervical cord dysfunction. He has neck pain associated with right arm pain and numbness as well as lower back pain associated with right leg pain and numbness. He has weakness in the right upper and right lower extremity. He has loss of dexterity in the hand and has impairment of his gait which requires the use of a cane. He has symptoms of ongoing cervical myelopathy. He was injured on the job in June 2011 at which time a metal piece from a machine with which he was working on fell on top of his head and onto his shoulder. The piece of metal weighed over 20 pounds. He apparently lost consciousness and was treated for a laceration to his scalp, had a concussion as well as an injury to his right shoulder and right arm. Apparently according to records, he underwent a right arm tendon repair. After that he had persistent headaches, neck pain and radicular symptoms in the right upper extremity including weakness. He also had symptoms of cervical myelopathy with loss of dexterity in the right upper extremity and impairment of his gait. He was evaluated by Dr. Sandoz, by Dr. Lozanne and Dr. Poletti and was felt to have a cervical cord contusion at the C3-4 level, which showed up on cervical MRI as abnormal signal within the cervical cord. He initially had some stenosis at the C3-4 level as well as foraminal stenosis at multiple levels in the cervical spine. He underwent anterior cervical discectomy and arthrodesis with anterior plating, C4 to C7 with Dr. Karl Lozanne in 2013. He had persistent symptoms of cervical myeloradiculopathy and was later evaluated by Dr. Poletti and felt to have worsening of stenosis at C3-4 and again signal change within the cord consistent with myelomalacia. He underwent a posterior cervical laminectomy and fusion by Dr. Frisch and Dr. Poletti in 2014. He was also having lower back pain and had epidurals for that. Prior to surgery, he had undergone conservative measures. He describes his pain as a 9 to a 10 on a scale of 1 to 10. His last imaging study of his cervical spine was in April 2015. He also had cervical spine x-rays in April 2016. Again his symptoms are that of ongoing headaches, radicular pain in the right upper and right lower extremity associated with significant weakness and loss of dexterity in both hands as well as impairment of his gait. He is currently taking hydrocodone. He describes his pain as constant, aching, throbbing, and shooting along with burning, numbness, and tingling. His lower back problems seem to be worse with sitting. He does seem to get improvement with changing positions.

He has a PAST MEDICAL HISTORY of hypertension, arthritis, seizures, depression and mental disorder.

His PRIOR SURGICAL PROCEDURES have included the two cervical spine surgical procedures as well as surgery on his arm in 2011.

His current MEDICATIONS are listed on the intake form. They include hydrocodone, Clonazepam and several other medications.

SOCIAL HISTORY: He is married. He is currently not working and describes himself as being disabled. He does not drink alcohol. He has never used tobacco products.

REVIEW OF SYSTEMS: By patient encounter form and documented on the chart.

PHYSICAL EXAMINATION: General appearance. He appears healthy. He is not overweight. Height is 6 feet. Weight 182 pounds. He has tenderness in the cervical spine region. He has a well-healed posterior cervical incision as well as an anterior cervical incision consistent with both an anterior and posterior decompression and fusion. He has limited cervical range of motion. He is tender over the right paraspinous muscles. He has painless hip range of motion. He has palpable pedal pulses. Motor testing reveals grade 4 out of 5 strength in all groups tested in the right upper extremity to include deltoid, biceps, triceps and grip. He has 4 out of 5 strength of right quad. His ankle dorsiflexion and plantar flexion is grade 5 out of 5. He has hyperactive reflexes in both lower extremities, which are brisk to testing. He does have a positive Hoffmann's sign in both upper extremities as well as brisk reflexes in the lower extremities and does not have clonus. Straight-leg-raise maneuver is negative.

RADIOGRAPHIC INTERPRETATION: Cervical spine x-rays dated April 2016 are reviewed and showed an anterior interbody fusion from C4-5, C5-6, and C6-7 with an anterior plate. There is no radiographic evidence of a nonunion. He also has posterior cervical fixation at C3-4.

A review of the cervical MRI dated April 2015 by my interpretation shows no obvious ongoing cervical cord compression.

IMPRESSION: Cervical cord contusion with ongoing cervical cord dysfunction and residual symptoms of loss of dexterity in the hands, weakness in the right upper extremity, weakness in the right lower extremity and impairment of gait.

RECOMMENDATION: I have reviewed his most recent imaging studies. I examined the patient and reviewed the records that were made available to me. I reviewed the records from treatment by Dr. Lozanne, Dr. Poletti and Dr. Sandoz. Dr. Poletti assessed him as having significant cervical cord dysfunction and gave him a greater than 50% impairment. To be specific, he gave him a 67% whole body impairment and felt that he was not able to return to gainful employment and his suggestion that was he seek social security disability. He was assessed by Dr. Sandoz as having a greater than 50% whole person impairment. Dr.

Sandoz also felt that he was not able to return to gainful employment. I would have to say that assessing this gentleman and reviewing the records and from my examination of him, I would have to agree with Dr. Poletti and Dr. Sandoz as far as his inability to return to gainful employment and with their diagnosis of incomplete quadriplegia. I would also agree with the impairment ratings that have been given by Dr. Poletti and Dr. Sandoz. In this case, I really do not think that a Functional Capacity Evaluation would be of much benefit because it is obvious that he has significant dysfunction and again I would be very surprised if he were capable of returning to any type of gainful employment.



William L. Mills, M.D. /AL
130181728

Chart Copy

# PSYCHOLOGICAL AND TRAINING SERVICES, P.A.

920 St. Andrews Rd., Columbia, SC 29210 bobnorabrabham@att.net PH: 803-731-0588 Fax: 803-731-0589

**ROBERT E. BRABHAM, PH.D**
LICENSED PSYCHOLOGIST
MASTER'S IN REHABILITATION COUNSELING
CERTIFIED LIFE CARE PLANNER

ROB BRABHAM JR., MRC NORA HEAPE, RN, BA BETH BURNETT, BA, ED


## PSYCHOLOGICAL and VOCATIONAL EVALUATION

Name: Victor J. Benjamin ID Number:

Date of Birth: Age at Evaluation:

Date of Evaluation: 07-30-15 (he did not know) Date of Report: 08-01-15

**Referral and Background Information:** Mr. Benjamin is a 53-year-old former Machine Operator (Cupper Operator) for Rexam Beverages, a beverage can manufacturing company. Mr. Benjamin had been employed there for over 30 years, albeit through several company names. He was referred for an independent psychological and vocational evaluation to determine vocational implications, and earnings issues related to limitations resulting from on-the-job injuries, including a (physical) traumatic brain injury (TBI), he sustained on 06-15-11. This evaluation took place at my office. Ms. Letia Benjamin, Mr. Benjamin's wife of 32 years, was also present during the evaluation, and was able to provide additional information.

Mr. Benjamin sustained on-the-job injuries when a machine malfunctioned. Due to his brain injury, Mr. Benjamin does not recall the actual events of his accident. However, records indicate that a part "flew" across the room and struck him in the head. Mr. Benjamin apparently lost consciousness for approximately 8-10 minutes. His right arm was nearly severed, and he sustained a gash in his right shoulder.

He was transported by EMS to McLeod Regional Medical Center, where he was diagnosed with, "*...left parietal skull fracture ...closed head injury with concussion...right forearm injury...possible tendon and nerve injury....*" Medical records also indicated that he had developed seizures after his TBI, but apparently they have since resolved. He has been unable to return to any gainful employment as a result of the on-the-job injuries he sustained on 6-15-11.

As noted previously, he and his wife have been married for 32 years. They have one son, age 23. He is employed, but he lives at home with his parents. As will be noted later, he deliberately returned home in order to assist in Mr. Benjamin's care, in order that his mother might not have to give up her job in banking to provide the care that Mr. Benjamin has required since his on-the-job injuries.

Mr. Benjamin arrived promptly for this evaluation. His wife drove him to the appointment. He does drive about 3-4 times a week, locally only, but with considerable pain in his neck and back when seated in a relatively fixed position, as driving requires. He also has limited range of motion in his neck, which makes such driving tasks as changing lanes or checking mirrors more difficult. He also has cognitive errors with driving, including ease of confusion, missing turns, and finding himself in lanes which require turning when he did not plan to do so. All of these examples are highly consistent with the consequences of a TBI.

His general appearance, hygiene and personal grooming were good. He is 6' in height. He indicated that he lost 30 pounds within the first 6-8 months after his on-the-job injuries, due to depression, in his opinion. He wears glasses. He experiences blurred vision, photosensitivity, and sees "floaters", all symptoms commonly seen following a TBI. He has ringing in his ears, and sensitivity to noise, also symptoms of a TBI.

He has significant mobility limitations, and is prescribed a cane. He actually falls a couple of times a year, and has numerous other "close calls." Balance issues are another symptom associated with a TBI. He wriggled and changed positions throughout the evaluation, citing neck and back pain.

At the time of this evaluation, he was receiving $704 per week in Worker's Compensation benefits, his only income. He has problems with the timely arrival of checks, and indicated that he has gone over a month without receiving a check at times. As a result, he and his wife are experiencing financial hardship at this time. He indicated that they have depleted their modest savings. They are trying to reduce their electricity bill. He also had to sell a "classic" Chevrolet he had been restoring, and they are having yard sales to make extra money. However, they are still "barely" able to pay their mortgage. Their son was in college, but he postponed his education to return home to help with his father's care.

**Sources of Information:**

Medical Records from:

- William Naso, MD
- George Sandoz, MD
- Leonard Goldschmidt, Psy.D, J.D.
- Roger Deal, MD
- Steven Poletti, MD
- Karl Lozanne, MD
- Richard Holgate, MD
- Matthew Welsch, MD
- Margaret Lee, MD
- Lawrence Bergmann, Ph.D.
- Jeffrey Shramek, MD
- Eugene Giddens, MD
- Timothy Close, MD
- Richard Frisch, MD

Vocational Testing and Evaluation Results:

- Wechsler Adult Intelligence Scale – Fourth Edition
- Wide Range Achievement Test – Revision 4
- Diagnostic Screening for Anxiety
- Clinical Interview and Behavioral Observations
- Mental Status Examination

**Activities of Daily Living:** He lives in a single-family house with his wife and their adult son. There are 4-5 steps at the entrance to the home, and he has fallen trying to enter and/or exit the home. He indicated that "if" a wheelchair is in his future, there is no access to his home at this time.

He has difficulty sleeping and his hours have gotten "messed up." On most days, he gets up late, between noon and 3:00 PM. He indicated that he "just doesn't feel like getting out of bed", due to severe headaches, orthopedic pain, and pervasive depression. His pain builds through the day and worsens.

He has problems getting on and off of the toilet at times, and has fallen in the bathtub. He only showers with family nearby now. He also has difficulty reaching overhead and bending and therefore, they have modified placement of items in their home. He cannot use his hands for fine motor activities such as buttoning a shirt.

Mr. Benjamin is unable to perform his usual chores around the home. He cannot cut the grass or work in the yard, due to orthopedic limitations as well as intolerance of temperature extremes, yet another symptom commonly seen following a TBI. His wife cooks meals, and leaves them for Mr. Benjamin to reheat in the microwave.

He also has marked limitations with his right hand, which was nearly severed in the on-the-job injuries, and has continuing problems gripping and grasping. He drops and breaks items at times, so he usually uses only paper or plastic plates. He is unable to open containers. He estimated that he can only carry about 4 pounds with his right hand, as measured by a half-gallon of milk.

He occasionally shops alone, but typically only at a local pharmacy. He indicated that he holds on to a cart for support, and would "never" use the electric cart. He added, "I'm paranoid enough without the cart." He requires items be packaged for ease of carrying. Despite efforts to do so, he is not able to sustain much physical activity, due to pain.

In a typical 24-hour day he indicates he must spend about 20 hours of the day reclining/resting in bed or in an oversized chair as a result of his physical limitations and pain. He indicated that he is "a prisoner in my own home." He essentially "lies around worrying" most of the day. He noted that his father and uncle died last year, which adds to his depression. The inability to remain in an upright position for a full 8-hour day even with sit/stand options clearly prevents his ability to sustain gainful employment at this time.

In a 5-day work week he indicated that he would be unable to remain at any job for a full 8-hour workday due to pain problems associated with medical conditions that resulted from his on-the-job injuries and his (physical) traumatic brain injury. This would of course greatly exceed the number of days available for personal/sick leave in an average job in South Carolina, about 1-day per month.

He returns to bed at about 10 PM and takes prescription medication for pain and for sleep. He indicated that he only gets about 4-5 hours of non-restorative sleep, usually interrupted by nightmares related to PTSD. He indicated, and his wife confirmed, that he "jerks and jumps" in his sleep several times a week, apparently associated with nightmares he continues to experience, part of the sequence of events related to his PTSD diagnosis, as assigned by Drs. Bergmann and Deal. Once awake, he continues to worry about his finances as well as his future health prognosis. He noted no prior history of sleep problems.

As a direct result of his on-the-job injuries, he is now able to participate in far fewer social or leisure activities than was the case prior to his injuries. As noted previously, he mostly stays home now. He avoids large crowds, and even avoids family activities. He has had a major change in personality following his on-the-job injuries, another symptom associated with a TBI. He admits that he has inadequate patience and is easily irritated, despite efforts to the contrary. He indicated that his relationships with friends, family and others have also changed as a result of his medical conditions.

He noted he could no longer swim in their backyard pool, ride a dirt bike, travel to visit family in NY and NJ, work in the yard, bowl, enjoy mountain vacations, walking for long distances, or going to movies, all activities he enjoyed prior to his on-the-job injuries. He also indicated that he cannot work on his cars, a major source of disappointment for him. He added that his father was a mechanic, and that he inherited all of his tools when his father passed away, but he cannot use them. His inability to use the mechanic tools is a combination of orthopedic as well as cognitive.

He noted he has difficulty concentrating and sustaining attention to complete nearly any tasks, yet another symptom associated with a TBI. His sexual activity has also changed as a result of his medical conditions, which adds to the depression he is experiencing. He has had marital conflicts, related to his on-the-job injuries. The overall quality of his life has clearly been greatly diminished by his injuries.

**Educational Background:** He graduated from Bishopville High School in 1980. He never needed to repeat any grades, and made average grades. (As will be noted, this contrasts markedly with his current quite-limited academic skills, at only low elementary grade levels, yet another indication of his TBI.) He participated in sports and clubs, and took Auto Mechanic classes, evidence of his good health at that time. After graduation, he took Welding classes at a public vocational school. He was certified as a Forklift Operator. He has received no further formal training and has no military experience.

**Work History:** Mr. Benjamin has a quite stable work history. At the time of his on-the-job injuries, he was working as a Machine Operator for Rexam Beverages, for whom he had worked for over 30 years, albeit under several company names. He earned $22 per hour, plus overtime and fringe benefits, totally approximately $77,000 annually.

Work as a Machine Operator is defined by The Dictionary of Occupational Titles as Semi-skilled and Medium in physical demands. In his job duties, he was required to lift, bend, stoop, and reach on a regular basis as part of his essential job duties. He indicated that he typically worked 12 hour shifts, 4 days "on" and 4 days "off", standing throughout a shift. As evidence of his good health prior to his injuries, he indicated, and his wife confirmed, that he would often work 10-12 days in a row, as needed.

He insisted that in his employment he had no personnel or performance problems. He enjoyed his co-workers, his colleagues and got along well with his supervisors. He indicated that he even won attendance awards. He has never held an "office job" or a Sedentary position, and has no such readily transferrable skills.

Mr. Benjamin indicated that his only prior injury had been an ankle injury in 2006. It was not work-related, but he was out of work for about 6-8 weeks during his recovery. That injury had not prevented him from returning to the full range of duties his work required thereafter. As to any other pre-existing conditions, he indicated a history of high blood pressure, and high cholesterol at times, both in good control prior to his on-the-job injuries. Those conditions worsened after his TBI, and he is now prescribed medication for both. Thus, it is reasonable to conclude that it is the on-the-job injury, including a traumatic brain injury, on 6-15-11, which have been the basis for his inability to maintain gainful employment.

**Medical Problems:** The medical aspects of his injury are documented in other reports, and will not be addressed in great detail herein. However, several more recent medical references have vocational significance and are noted accordingly.

On 6-15-11, Dr. William Naso, McLeod Regional Medical Center, noted, "...*head injury*...struck in the head with some sort of industrial belt...lacerations to scalp, right forearm, left shoulder...*anesthetic to events of the accident...headache...dizziness*... unable to straighten fingers...CT scan shows bone that is projected toward soft tissue...left parietal skull fracture...*closed head injury with concussion*...right forearm injury...possible tendon and nerve injury..."

On 6-16-11, Dr. Matthew Welsch, McLeod Health, performed surgery noted as, "...right forearm laceration...irrigation and debridement of skin and subcutaneous tissue...repair of extensor digitorum communis tendons...index, middle, ring, and small finger..."

On 6-24-11, Dr. Naso noted, "...*significant headaches*...lightheadedness...dizziness...neck discomfort...radiating into right arm...*postconcussive syndrome*...neck pain with cervical myofascitis...Skelaxin...loss of normal lordosis...degenerative disc disease throughout cervical spine...anterior osteophyte at C3-4..."

From 6-27-11 through 10-4-11, Mr. Benjamin attended 22 sessions of occupational therapy.

On 7-20-11, Dr. Welsch noted, "...continue therapy...wean the splint...*no use of right upper extremity*..."

On 8-3-11, Dr. Naso noted, "*...headaches...short term memory loss...post-concussive syndrome*...continue conservative management..."

On 8-17-11, Dr. Welsch noted, "...avoid lifting greater than 2 pounds and any repetitive use of right hand..."

On 9-16-11, Dr. George Sandoz, Grand Strand Specialty Assoc. Neurology, indicated, "*...head injury*...neck pain...*dizziness...aggravating factors include exertion, lying down, sound, touch...confusion...incoordination...irritability...loss of consciousness...memory difficulty...personality change...restlessness...speech difficulty...stiff neck...unusual behavior...visual disturbance...weakness...neck pain worsened...difficulty sleeping... disequilibrium...muscle spasm...persistent dizziness...imbalance...spinning...hearing loss...paresthesias...tinnitus...intracranial injury*...Lamictal...Meclizine...injury causing damage on inner ear...Nucynta..."

On 10-10-11, Dr. Margaret Lee, Florence MRI & Imaging, noted, "...Cervical Spine MRI...intracranial injury...right side neck pain...multilevel cervical spondylosis...foraminal stenosis on the right at C3-4, C4-5, C5-6...moderate to severe osseous foraminal stenosis of the left C6-7...lobular inflammatory mucosal thickening in left maxillary sinus..."

On 10-18-11, Leonard Goldschmidt, Psy.D, J.D., noted, "...multiple complaints of *sensorimotor, cognitive, emotional difficulties...secondary to work-related injury...lost consciousness for roughly 8 minutes...nausea with headaches or with motion sickness...chronic headaches on a near daily basis...several times per day...lasting from several minutes to half the day...phonophobia...problems with balance, coordination, dropping things...decreased hearing in ears bilaterally...short-term memory problems...prospective memory issues...difficulty following conversations...increased stress and tension...easily and increasingly more agitated...erectile dysfunction...middle and initial insomnia...out of work on medical disability...Dementia Due to Closed Head Brain Injury, with Behavioral Disturbance...Closed Head Brain Injury...*"

On 10-26-11, Dr. Sandoz noted, "*...neck pain daily...cervical compression...difficulty sleeping...muscle spasm...numbness...tenderness...headache...paralysis...stiff neck... difficulty with ambulation...needs assistance with ADLs...off work...*"

On 10-27-11, Dr. Sandoz noted, "...EMG and NCV...moderate carpal tunnel syndrome of right upper extremity...ulnar neuropathy at elbow of right upper extremity..."

On 1-4-12, Dr. Sandoz noted, "...neck pain worsened...daily...radiation to right upper arm...right forearm...right intrascapular...*not responding to current treatment*...difficulty with ambulation...needs assistance with ADLs...epidural steroid injection..."

On 12-7-11, Dr. Goldschmidt noted, "*...Posttraumatic Stress Disorder, Chronic...*"

On 1-19-12, Dr. Welsch noted, "...neck pain...*carpal tunnel syndrome...nearly constant... numbness and tingling into fingertips...*"

On 2-2-12, Dr. Sandoz noted, "...*dizziness...loss of consciousness...worsening... imbalance...severe spinning...jerking movements...vertigo...*" On 2-6-12, Dr. Sandoz noted, "...*loss of consciousness...crumbled to ground...due to head trauma*...erectile dysfunction...Vicodin...Klonipin...Cialis..."

On 2-21-12, Dr. Sandoz indicated, "...not responding to current treatment...Keppra..."

On 4-25-12, Dr. Sandoz noted, "...*seizure...altered level of consciousness...staring...daily headache...aggravated by bright lights and noise...aching and burning neck pain... Locosamide...injury causing epilepsy...migraine*...Vimpat...epidural steroid injection... Botox is indicated..."

On 6-6-12, Dr. Lawrence Bergmann, Post Trauma Resources, noted, "...*continues to experience irritability and anger...cognitive symptoms...sleep difficulties... nightmares... depressed mood...headaches...lack of balance...ringing in ears...*"

On 6-7-12, Dr. Sandoz indicated, "...*lack of sleep...automatic behaviors... unresponsiveness...occipital headaches aggravated by bright lights, head position, noise*...Ultracet...Vimpat...*issues with concentration and performing complex tasks*...Keppra..."

On 6-20-12, Dr. Sandoz noted, "...*clumsiness...headache...irritability...memory difficulty...restlessness...seizure...stiff neck...vomiting...dizziness*...Ultracet...Vimpat...*late effect of intracranial injury...*"

On 7-19-12, Dr. Bergmann noted, "...no improvement in sleep or mood...frustration with life...depressed mood withdrawal...angry...hypervigilance...exaggerated startle response ...anxiety...multiple fears..."

On 8-9-12, Dr. Roger Deal, Post Trauma Resources, noted, "...pervasive anxiety...sense of impending death...feels he may not wake up when he tries to go to sleep... hypervigilance...remains very symptomatic with nightmares...dysphoria..."

From 9-18-12, through 5-8-13, Mr. Benjamin attended physical therapy at Dynamic Physical Therapy of Florence. Records indicated, "...right forearm...underwent surgery but never regained full function back...severe pain in left lower extremity...*balance problems which have caused falls...unable to work*...nightmares...unable to perform light housework...can sit less than an hour...can stand 5-10 minutes...can walk less than 5 minutes..."

On 9-26-12, Dr. Sandoz noted, "...neck pain worsened after physical therapy...*still far from going back to work to gainful employment...*"

On 10-15-12, Dr. Jeffrey Shramek, Florence MRI & Imaging, noted, "...MRI Cervical Spine...cord compressive effects at C3-4 and C5-6...bilateral C4-C6 foraminal stenosis ...severe left C7 bony neural foraminal stenosis...discogenic edema of endplates at C3-4 through C6-7...myelomalacia of cervical cord at C3-4..."

On 11-5-12, Dr. Steven Poletti noted, "...posterior stenosis with cervical myelomalacia... secondary to cord contusion at C3-4 level...persistent symptoms into arms and legs... spasticity...upgoing toes...hyperflexia...necessitates posterior cervical decompression..."

On 11-21-12, Dr. Eugene Giddens, Grand Strand Specialty Associates, indicated, "...neck pain...numbness...weakness...tingling...has been through a gamut of conservative measures...cervical myelopathy with signal changes in cord...significant stenosis at multiple levels...should have decompression and fusion..."

On 1-22-13, Dr. Bergmann noted, "...continued physical limitations...*depressed mood...irritability...withdrawal...anger...complaints about sleep...*"

On 2-5-13, Dr. Sandoz indicated, "*...neck pain incapacitating...worsened...headache daily...blinding...squeezing...*cervical disc displacement...*post-trauma headache...late effect of intracranial injury...*Vimpat for *seizure...*Restoril..."

On 2-18-13, Dr. Karl Lozanne, Columbia Neurosurgical Associates, performed surgery noted as, "...C4-5, C5-6, C6-7 anterior cervical discectomy fusion and osteophytectomy..."

On 3-11-13, Dr. Bergmann noted, "...very bad dreams...sense of whirling characteristic of seizures..."

On 5-16-13, Dr. Lozanne noted, "...recurrence of right-sided arm discomfort... headaches... needs continued physical therapy...myelopathy...prescribed 4-point cane...*remain out of work...*"

On 8-2-13, Dr. Timothy Close, Imagecare, noted, "...MRI right shoulder...mild distal supraspinatus tendinopathy...intra-articular tendinopathy of long head biceps tendon... Type 2 SLAP tear posterior of biceps labral complex..."

On 9-10-13, Dr. Sandoz indicated, "...cervical disc disease...Lorcet... Vimpat...Vilbryd... Lidoderm patch...Klonopin...Restoril..."

On 10-14-13, Dr. Welsch noted, "...right shoulder injury...catching sensation in the neck with rotation...difficulty with rotation to the right side...pain with overhead activities... most symptoms may be coming from cervical spine..."

On 11-21-13, Dr. Lozanne noted, "*...intolerance to cold sensation across neck and arms...headaches...ambulates with cane...continue out of work...*not at MMI..."

On 1-14-14, Dr. Sandoz indicated, "*...irritability...memory difficulty...seizure...mood disorder...significant disruption due to anger/control issues...worsening clinically...*"

On 1-20-14, Dr. Richard Holgate, DiscRad, noted, "...multilevel spondylosis with probable root compression at levels showing severe or moderately severe foraminal stenosis..."

On 1-21-14, Dr. Poletti noted, "...edema within spinal canal...progressive stenosis at C3-4 level...spastic reflexes...hand myelopathy...*on off duty status...most likely not to improve with surgery but the surgery could prevent him from worsening...*"

On 2-5-14, Dr. Deal noted, "...*depressive symptoms* related to many losses...chronic pain...feeling of being unproductive for this long...Klonopin..."

On 2-13-14, Dr. Richard Frisch and Dr. Poletti performed surgery, noted as, "...C3 laminectomy...C3-4 posterior spinal fusion...C3-4 nonsegmental instrumentation...local autograft...application cranial tongs..."

On 4-3-14, Dr. Poletti noted, "...*issues with balance are more than likely a permanent situation*...continues to ambulate with cane...has had very little improvement...*totally and permanently disabled...signs of spasticity...inability to use hands for repetitive fine motor activities...meets the obvious criteria for pursuing permanent disability, Social Security disability....there is no amount of vocational retraining or therapy that can change that...unfortunately neurologically he has 'got what he's got'*...rationale behind surgery was to prevent him from worsening...which I believe was happening..."

On 5-15-14, Dr. Holgate noted, "...right leg pain progressively worse...L4-5 moderate facet arthopathy...bilateral root compression...diffuse shallow protrusion...moderately severe bilateral recess stenosis..."

On 6-18-14, Dr. Welsch noted, "...pains in different areas of his body including right foot...at MMI from shoulder standpoint..."

On 7-15-14, Dr. Sandoz indicated, "...*clumsiness...confusion...gait disturbance...hearing loss...incoordination...irritability...loss of consciousness...lucid intervals...memory difficulty...personality changes...restlessness...seizures...speech difficulty...stiff neck... unusual behavior...weakness...epilepsy...PTSD*...Hydrocodone-Acetaminophen...Lidoderm patch...Lorcet...Vimpat..."

On 2-5-15, Dr. Bergmann completed a questionnaire which noted, "...*unable to return to work...will need medication and medical management indefinitely...will need psychotherapy for at least the next two years and possibly more...*"

On 2-13-15, Dr. Sandoz noted, "...neck pain worsened...radiation to right (side of) face...right upper arm...right elbow...right forearm...difficulty sleeping...muscle atrophy...muscle spasms...tenderness...Lidoderm patch...Hydrocodone-Acetaminophen... Valium...Clonazepam...disc disorder orsening...Butrans patch..."

On 4-14-15, Dr. Sandoz noted, "...neck pain...problem has not changed...constant... dysphagia...severely reduced ROM in cervical spine...quadriparesis...using a cane..."

On 5-27-15, Dr. Poletti noted, "...had severe spinal stenosis at C3-4 level after an accident...obvious spinal cord compression and bruising of the spinal cord...progressive loss of use of upper extremities...altered gait and imbalance...*serious or catastrophic neurologic injury*...signs and symptoms of upper and lower extremity weakness...

incomplete quadriparesis...*disabling problem that will prevent him from walking normally or using his hands normally for fine motor activities...obviously permanently disabled from returning to any type of employment...meets necessary criteria for pursuing Social Security disability...impairment is 67% to the whole person*...will need pain management care..."

On 6-19-15, Dr. Sandoz noted, "...cervical disc injury that left him with myelomalacia... *traumatic brain injury with late effect of this injury associated with headaches, seizure, PTSD, and lumbar pain*...54% impairment of the whole body..."

At the time of this evaluation, Mr. Benjamin is still prescribed Vimpat, Clonazepam, Hydrocodone-Acetaminophen, Percocet, Diovan, and Valium for his medical conditions resulting from his on-the-job injuries.

References to incapacitating pain in records exist over an extended period of time. He indicated treatment has included prescription medications, physical therapy, injections, and a TENS-unit. When asked to describe his pain, he indicated that since his on-the-job injuries he experiences pain at a level 8-9 on a 10-point scale, 7-days per week. He is never pain free. He noted that nearly any movement exacerbates the pain. His pain is best relieved by prescription medication, and by resting/relaxing.

**Evidence and Symptoms Associated With An Traumatic Physical Brain Injury/Damage**: Medical records cited previously in this report clearly confirm the presence of a (physical) traumatic brain injury. In that regard, the following information is provided.

There are many symptoms and complications associated with a Traumatic Brain Injury/Damage. These may include headache, confusion, dizziness, blurred vision, ringing in the ears, ease of fatigue, change in sleep patterns, behavioral or mood changes, memory problems, trouble with concentration and attention, onset of seizures, and numbness or loss of physical coordination, including episodes of balance difficulties/falls. Mr. Benjamin has experienced all of these symptoms.

Cognitive problems may include difficulty with memory, learning, reasoning, problem solving, judgment, attention and concentration, multitasking, organization and initiation (beginning or completing tasks). Emotional changes may include depression, anxiety, mood swings, irritability, and lack of empathy or motivation. Sensory problems may include tinnitus, impaired eye-hand coordination, blurry vision, balance problems, persistent tingling, itching or pain. Mr. Benjamin has experienced all of these symptoms as well.

There are multiple medical references over an extended period of time confirming many of the above-referenced symptoms. Utilizing the AMA Guides to the Evaluation of Permanent Impairment-5th Edition, specifically Chapter 13 (The Central and Peripheral Nervous System), Mr. Benjamin is assessed as continuing to having impairments based on the Clinical Dementia Rating Scale (CDR). He is quite compromised in his attention/concentration, speed of mental processing and multitasking. He avoids most social and recreational activities that previously afforded him pleasure.

He still has marked physical limitations and restrictions that clearly prevent him from performing the full range of job duties that his past employment setting required.

Based on the CDR ratings, Mr. Benjamin is assessed as still having a "Class 2 Impairment", a level of impairment which requires "direction of some activities", resulting in a 15%-29% impairment of the whole person. Using the midpoint in this range, this equates to about a 22% impairment rating.

Specifically, this is based on his memory loss; moderate difficulty in handling some activities; as to community affairs he "appears normal to casual inspection", but has limited his activities; as to home and hobbies, he has abandoned most of his leisure and hobby activities he enjoyed prior to his injuries.

**Mental Status Evaluation:** He was well oriented to all spheres, and neither demonstrated nor reported any hallucinations or delusional thought processes. He noted no prior mental health history.

He described, and medical records confirm, clinically significant symptoms of the continued presence of a level of depression. His depressive symptoms include a considerable loss of interest or pleasure which is nearly always present. This includes social withdrawal even from family activities; significant reduction in previous levels of sexual interest or desire; decreased energy, tiredness and fatigue out of proportion to actual activity; impaired ability to concentrate, or make decisions; and easily distracted with memory difficulties.

These symptoms have clearly resulted in significant distress/ impairment in social, occupational, and other important areas of functioning. These symptoms are not better described by any other general medical condition and there is no evidence of any substance abuse which would cause these same symptoms. He admits to suicidal thoughts, and has called his wife to express those thoughts on several occasions. Mr. Benjamin is receiving mental health services from Post Trauma Resources on a weekly basis, and I recommend that those services continue to be made available to him.

It is worthy to note that considerable recent research evidence, as published in various pain management journals, indicates that the vast majority of individuals who experience pain for more than a year can be expected to develop significant clinical depression. Mr. Benjamin continues to experience pain, now four years following his on-the-job injuries.

In assessing Mr. Benjamin's symptoms of pain, there are medically determinable impairments that could reasonably be expected to produce his pain. Records also confirm the intensity, persistence, and/or functionally limiting effects of the pain and/or other symptoms. Based on determinable medical evidence, both aspects are well established, and support a diagnosis of a pain disorder.

He also described considerable anxiety that he is continuing to experience as a direct result of the on-the-job injuries received in June 2011. This includes awareness, with credible specificity, of his extreme concerns/anxiety as to his future medical prognosis.

His anxiety is worsened by the realization that in spite of full and careful compliance with all recommended medical treatments and allied services, the hoped-for significant improvement simply has not occurred.

None of his prior work can reasonably be expected to remain even a possibility, due to what have been designated as "permanent" limitations and restrictions. In the absence of other readily transferrable skills, this must reasonably be expected to result in long-term earning losses, and a loss of earnings capacity.

He does not use illegal drugs, does not consume alcohol, and does not use tobacco products. He has routine drug screens prior to medical treatment, which he always passes without incident.

**Psychological Test Results:** He appeared to cooperate and to give optimal effort during this evaluation. Thus these results are believed to be valid indicators of his current levels of functioning.

On the Wechsler Adult Intelligence Test – Fourth Edition, he obtained a Full Scale IQ score of only 64. He is, therefore, functioning within a level of intellectual deficits. However, this is clearly not consistent with his educational and work background. It is, however, quite consistent with a history of a traumatic brain injury.

On the Wide Range Achievement Test – Revision 4, his Reading Standard Score is only a 4.6 grade level score, his Arithmetic Standard Score is only a 1.1 grade level score, and his Spelling Standard Score is only a 2.3 grade level score. Again, these scores would not be consistent with his educational background, but are quite consistent with a history of a TBI. Regardless of cause, however, his academic skills are not sufficient for use in work settings in which such skills would be essential.

**Diagnoses:** As noted earlier, evidence cited supports a finding that he sustained a (physical) traumatic brain injury at work, as confirmed by numerous records cited earlier. After observing him during this evaluation, and from careful review of records of past behavior and levels of functioning, he is clearly manifesting signs and symptoms consistent with the requirements to establish and/or maintain several other diagnoses as well. Specifically, he is continuing to experience migraine headaches/pain. Additionally, his orthopedic pain has not improved, and medical records confirm that he will most likely not improve any further. He is also anxious about his future, especially since he realizes that his past work is no longer an option for him, an anxiety-provoking thought for someone at the age of 53. Finally, his multiple losses, personal, financial, social and leisure, all have led to a level of depression.

Therefore the following diagnoses apply, in keeping with all diagnostic requirements for each:

*294.1 Cognitive Disorder, Secondary to Traumatic Brain Injury*
*307.89 Pain Disorder*
*311 Depressive Disorder NOS*
*300.02 Generalized Anxiety Disorder*
*309.81 Posttraumatic Stress Disorder*

These medical/mental conditions are in addition to her other physical medical problems that are well documented in her files.

**Vocational Opinion and Rationale:** Several factors must be considered in reaching a vocational opinion. They include his age of 53, still defined as "approaching advanced age", a negative factor; his high school graduate educational background is positive, but is offset by his lower than expected academic scores; his stable work history would be positive but is offset by his inability to perform any work on a sustained basis; due consideration must also be afforded to the pain that he experiences on a daily basis which requires that he spend 20 hours per day "resting or reclining"; and his depression and anxiety also interfere with his ability to maintain sufficient attention and concentration, which becomes a negative factor.

Taking all of these factors into consideration, it is my opinion, to a high degree of professional certainty, based on more than fifty years of vocational rehabilitation and psychology experience, that he must be expected to permanently remain, unable to engage in full-time gainful, competitive employment as a result of his medical conditions resulting from his on-the-job injuries in June 2011.

The rationale for my opinion is essentially based on the following observations:

**Credibility:** He appeared credible in his description of his limitations and remaining functional capacities. As a result of his cognitive and orthopedic limitations, he cannot complete significant tasks or activities on a regular, sustained basis.

It is noted that the information provided during this interview was highly consistent with information reported in other reports. This provided additional confirmation that the responses and description of events and circumstances were candid, were not feigned or exaggerated, and do not appear to represent any symptom magnification.

It is not reasonable to suggest that someone with a remarkably stable work history, over thirty years with one employer, who was a major source income for his family, would suddenly feign or fake an inability to work, and by doing so, subject his family to the financial hardship they are currently experiencing.

**Medications:** He is prescribed numerous medications, and is carefully compliant with dosages and times as prescribed, and has been so since his injuries. However, he experiences the usual and predicted side-effects of medication, including feelings of fatigue and an inability to function at optimal levels while taking his medications.

**Pain Factors and Attendance Implications:** Even with pain medication he continues to experience significant pain at such levels as to interfere with his ability to sustain physical activity. His cognitive deficits would also cause difficulty in his ability to pay attention to job tasks and job duties for hours each week, on average. The inability to maintain concentration and persistence interferes with the ability to meet production expectation for even unskilled jobs.

**Limitations on Sitting and Standing:** His limitations on sitting and standing are such that vocationally even any sedentary work, which might otherwise have been suggested, is precluded. Vocationally, any work requires some combination of sitting, standing and/or walking for a full 8-hour workday, without the need to rest for prolonged periods of time, something he is unable to do in his present condition.

**Limitations on Use of Right Upper Extremity:** Persons who have severely limited use of even one arm experience a significant reduction in the occupational base which otherwise have been considered. The inability to use both upper extremities results in functional capacity somewhere between sedentary and light work. Such individuals are unable to perform the usual full range of even sedentary work because the vast majority of even unskilled sedentary jobs require the good use of both hands. This is a finding noted in Social Security Ruling (SSR 83-12) and is often cited. Additionally, gainful employment by definition requires that one be able to use the upper extremities for a full 8-hour workday, without the need to rest for prolonged periods of time, something he is unable to do in his present condition.

**Social Security Considerations:** Based on the evidence in his files, and following the guidelines as noted in the Psychiatric Review Technique, SSA Form 2506-BK, he clearly meets the requirements of at least a 12.04 Affective Disorder.

*As to the Affective Disorder, his depressive syndrome is characterized by* (1) loss of interest in almost all activities, as noted by his withdrawal from social and recreational activities; (2) sleep disturbance, as evidenced by prescription medication for sleep; (3) decreased energy, as evidenced by the need to "rest" for the major portion of typical days; (4) and difficulty concentrating.

*He also clearly meets the "B" Criteria of the Listings* as evidenced by his current "Marked" restriction in activities of daily living; his "Marked" difficulties in maintaining social functioning as evidenced by his withdrawal from nearly all such activities; and his "Marked" difficulties in maintaining concentration and persistence to even simple chores.

The combination of his multiple physical and psychiatric conditions clearly results in an inability to sustain gainful employment.

Medical records by his treating physician, Dr. Steven Poletti, indicate that Mr. Benjamin sustained a "*...serious or catastrophic neurologic injury...incomplete quadriparesis ...a disabling problem that will prevent him from walking normally or using his hands normally for fine motor activities...*" Dr. Poletti noted that Mr. Benjamin is "*obviously permanently disabled from returning to any type of employment...and meets necessary criteria for pursuing Social Security disability...*"

References confirm that he is permanently disabled as a result of his (physical) traumatic brain injury; he is 53 years of age, defined as approaching advanced age; and his previous work as a Machine Operator is so specific that it provides no transferrable skills. As a result of this combination of factors, he will likely meet Social Security requirements for approval of disability benefits.

**Summary and Conclusions:** Based on all the evidence as described above, consistent with observations during this evaluation and various reports in his file, he would be unable to effectively perform the essential duties in any gainful work activity. It is also clear that the unfortunate combination of factors and characteristics he now faces are directly related to the injuries he sustained while working.

As noted in multiple records, Mr. Benjamin is unable to maintain any position for more than a brief period of time, less than thirty minutes, and has to frequently change positions. He also is unable to perform any physically strenuous activity. Further, Mr. Benjamin is also unable to handle any type of work that would require close attention to detail, attention, concentration, persistence or pace. As a result, he would clearly be incapable of performing any type of work that would exist in significant numbers in the regional or local economy. Directly as a result of his on-the-job injuries the only services he could perform are so limited in quality, dependability, or quantity that no reasonably stable market for them exists.

No employer could reasonably be expected to tolerate and accommodate his need for extended breaks, need to lie down throughout the day, and general lack of productivity. Clearly, his limitations seriously erode the occupational base.

The opinions noted in this report are offered within a reasonable degree of professional certainty, based on more than 50 years of vocational rehabilitation and psychology experience. Thank you for the opportunity to work with you in this matter. If you have any questions, or if I could address additional issues, please do not hesitate to contact me.

Robert E. Brabham

Robert E. Brabham, Ph.D.
Licensed Psychologist (SC #77)
Master's in Rehabilitation Counseling
Brain Injury Specialist, Former Director of the Brain Injury Alliance of South Carolina
Former Director, Brain Injury Division, SC Department of Disabilities and Special Needs

# History Physical

MCLEOD REGIONAL MEDICAL CENTER
555 East Cheves Street
Florence, SC 29501-0551

NAME: BENJAMIN, VICTOR
TSCUTS1501
MED. REC. NO.:
DR. DICTATING: Naso William B MD
PATIENT NO.:
ADMIT DATE: 06/15/2011

NAME: Benjamin, Victor
MED. REC. NO.:
DR. DICTATING: William B Naso, MD
DOB:
PATIENT NO.:
ADMIT DATE: 06/15/2011

CHIEF COMPLAINT: Head injury.

HISTORY: The patient is a 49 -year-old black male who had an accident in which he was struck in the head with some sort of industrial belt and sustained lacerations to the scalp, right forearm and left shoulder. He was taken to the Emergency Room. He was evaluated by Dr. Lewis. A CT scan was performed and I was called to see the patient in Neurosurgical consultation. The patient is anesthetic to the events of the accident. He also has weakness in his right ulnar hand.

He denies any chronic medical problems other than hypertension and hypercholesterolemia although he is on no antihypertensive medications. He says that he controls his blood pressure with dietary supplements.

He does say that he is allergic to Demerol.
He denies tobacco or alcohol use or abuse.

REVIEW OF SYSTEMS: Otherwise as above. He denies chest pain or shortness of breath. He denies seizure activity.

ON PHYSICAL EXAMINATION: His blood pressure is 136/83. His heart rate is 72. Respirations 19. 100% saturation on room air. Temperature is 98.9.
General: This is a well developed, well nourished, fit appearing 49 -year-old black male. He is awake, alert, conversant, fluent speech. Normal affect. He has a headache. He complains of some dizziness. He is anesthetic to the events of his accident. His pupils are equal and reactive. His extraocular movements are intact. He has no nystagmus. His face is symmetric. His tongue is midline. Both upper and lower extremities have normal bulk and tone with 5/5 strength in the left grip, both biceps, triceps, deltoids, iliopsoas, quadriceps, hamstrings, gastroc, and anterior tibiales motor groups. His right hand, his fourth and fifth digits are flexed toward the wrist. The first through third digits work normally. He is unable to straighten his fingers. He has a sutured laceration of the right volar and radial forearm. He had sutured laceration of the left parietal scalp and a sutured laceration of the left posterior shoulder region.

CT scan of the brain is available for review. There is a comminuted fracture in the left parietal convexity with minimal depressed bone with also some bone that is projected toward the soft tissue.

I reviewed all of his laboratory values as well. His hemoglobin is 13.1.

PRIVILEGED AND CONFIDENTIAL: This facsimile contains privileged and confidential information. If you are not the intended recipient, or the person responsible to deliver it to the intended recipient, you are hereby advised that any dissemination, distribution, or copying of this facsimile is strictly prohibited. If you have received this transmission in error, please notify us immediately by telephone.

IF PATIENT INFORMATION HAS BEEN DISCLOSED TO YOU, IT CAME FROM RECORDS WHOSE CONFIDENTIALITY IS PROTECTED BY STATE AND FEDERAL LAW. ANY FURTHER DISCLOSURE OF THIS PATIENT INFORMATION WITHOUT PRIOR CONSENT OF THE PERSON TO WHOM IT PERTAINS MAY BE PROHIBITED.

BEST IMAGE POSSIBLE



# History Physical

MCLEOD REGIONAL MEDICAL CENTER
555 East Cheves Street
Florence, SC 29501-0551

NAME: BENJAMIN, VICTOR
TSCUTS1501
MED. REC. NO.:
DR. DICTATING: Naso. William B MD
PATIENT NO.:
ADMIT DATE: 06/15/2011

ASSESSMENT:

1. Left parietal skull fracture as described.
2. Closed head injury with concussion.
3. Right forearm injury, possible tendon and nerve injury.

COMMENT: We are going to admit the patient to the Intensive Care Unit for close observation. We will maintain him on intravenous antibiotics. At this point I would recommend observation. We will obtain orthopedic consultation for his forearm injury. I discussed his diagnosis and our treatment plan at length with the patient.

Date/Time:_____(AM/PM) Date/Time:_____(AM/PM)

William B Naso, MD

amc
DD : 06/15/2011 8:22 A
DT : 06/15/2011 9:50 A
Job #: 000008281
cc: William B Naso, MD

Signed by NASO MD, WILLIAM B on 21-Jun-2011 07:43:26 -04:00

PRIVILEGED AND CONFIDENTIAL: This facsimile contains privileged and confidential information. If you are not the intended recipient, or the person responsible to deliver it to the intended recipient, you are hereby advised that any dissemination, distribution, or copying of this facsimile is strictly prohibited. If you have received this transmission in error, please notify us immediately by telephone.

IF PATIENT INFORMATION HAS BEEN DISCLOSED TO YOU, IT CAME FROM RECORDS WHOSE CONFIDENTIALITY IS PROTECTED BY STATE AND FEDERAL LAW. ANY FURTHER DISCLOSURE OF THIS PATIENT INFORMATION WITHOUT PRIOR CONSENT OF THE PERSON TO WHOM IT PERTAINS MAY BE PROHIBITED.

RADIOLOGY REPORT
McLEOD REGIONAL MEDICAL CENTER
555 E. CHEVES STREET FLORENCE, SC 29506-2617
PHONE (843) 777-2087

PATIENT NAME: BENJAMIN, VICTOR DISCHARGE DATE:
PT ACCOUNT#: MR/RAD#: 324683
ACCESSION#: CID#: 472820

DOB: AGE: 49Y SEX: M RACE: B
PHONE: 803-428-3352 PT CLASS: I FIN CLASS: U
ADDRESS: 1841 HOLMAN RD PT TYPE: G PT NS/ROOM: ERMN-EM0401
SUMTER, SC, 29153
ORDER DR: THOMAS G. LEWIS JR. M.D.
ATTEND DR: WILLIAM B NASO M.D.
COPY TO:
DIAGNOSIS: HEAD INJURY
ORDER DR: THOMAS G. LEWIS JR. M.D.
ATTEND DR: WILLIAM B NASO M.D.
TRANSCRIBED D/T: Jun 15 2011 7:59AM
PROCEDURE: CT HEAD WO U / ORD #: 90001 Accession#: CPT: 70450
ORDERED FOR: Jun 15 2011 2:14AM COMPLETED: Jun 15 2011 2:38AM
INDICATIONS/COMMENTS: TRAUMA

Head CT

History trauma a large head laceration.

RESULT: Sinuses and mastoids are clear. There is a comminuted fracture left frontal parietal region . There is minimal depression of one of 2 mm. There is superior displacement of outer table fragment. The ventricles are normal in size. No shift or mass effect.. No hemorrhage.

CONCLUSION: Comminuted minimally depressed left frontal parietal fracture. No intracranial hemorrhage.

READING DR: CHENEY M MEIERE JR M.D.
READING DATE: Jun 15 2011 7:59AM

Printed: June 15, 2011 (8:04AM) Page 1

FLORENCE RADIOLOGICAL ASSOCIATES

PRIVILEGED AND CONFIDENTIAL: This facsimile contains privileged and confidential information. If you are not the intended recipient, or the person responsible to deliver it to the intended recipient, you are hereby advised that any dissemination, distribution, or copying of this facsimile is strictly prohibited. If you have received this transmission in error, please notify us immediately by telephone.

IF PATIENT INFORMATION HAS BEEN DISCLOSED TO YOU, IT CAME FROM RECORDS WHOSE CONFIDENTIALITY IS PROTECTED BY STATE AND FEDERAL LAW. ANY FURTHER DISCLOSURE OF THIS PATIENT INFORMATION WITHOUT PRIOR CONSENT OF THE PERSON TO WHOM IT PERTAINS MAY BE PROHIBITED.

BEST IMAGE POSSIBLE



RADIOLOGY REPORT
McLEOD REGIONAL MEDICAL CENTER
555 E. CHEVES STREET FLORENCE, SC 29506-2617
PHONE (843) 777-2087

PATIENT NAME: BENJAMIN, VICTOR DISCHARGE DATE:
PT ACCOUNT#: MR/RAD#: 324683
ACCESSION#: CID#: 472820

***Final Result***
ELECTRONICALLY SIGNED BY:
CHENEY M MEIERE JR, M.D.
On: Jun 15 2011 8:00AM



FLORENCE RADIOLOGICAL ASSOCIATES

PRIVILEGED AND CONFIDENTIAL: This facsimile contains privileged and confidential information. If you are not the intended recipient, or the person responsible to deliver it to the intended recipient, you are hereby advised that any dissemination, distribution, or copying of this facsimile is strictly prohibited. If you have received this transmission in error, please notify us immediately by telephone.

IF PATIENT INFORMATION HAS BEEN DISCLOSED TO YOU, IT CAME FROM RECORDS WHOSE CONFIDENTIALITY IS PROTECTED BY STATE AND FEDERAL LAW. ANY FURTHER DISCLOSURE OF THIS PATIENT INFORMATION WITHOUT PRIOR CONSENT OF THE PERSON TO WHOM IT PERTAINS MAY BE PROHIBITED.



W.S. (Bill) Edwards, Jr., M.D. * Rakesh P. Chokshi, M.D.
Patrick K. Denton, M.D. * Anthony W. Alexander, M.D. * Barry L. Clark, D.O.
Nigel A.R. Wall, M.D. * Robert E. Elvington, Jr. M.D. *
Matthew D. Welsch, M.D.* Jason B. O'Dell, M.D.* Dewey N. Ervin, M.D. *

901 E. CHEVES ST., SUITE 100 - FLORENCE, SC 29506-2769
1580 FREEDOM BLVD., SUITE 100 - FLORENCE, SC 29505
(843) 662-5233 - FAX (843) 678-9003 - WWW.PDOA.COM

## Follow-up Examination

PATIENT ID:

PATIENT: Victor Benjamin
DOB:
Employer: Rexam Inc

Date of Service: 09/23/11
Age:
Occupation: Maintenance

Referring Physician: MRMC ER, , ;
Other Physicians: Daniels, G; Roosevelt,

Date of Injury/onset:

| Date: | Type: |
|---|---|
| 06/15/2011 | Injury |

Chief Complaint: Right hand extensor tendon repairs

History of Present Illness: Victor returns now 14 weeks out from his surgery. He has been doing range of motion exercises and strengthening exercises with occupational therapy. He is using the right arm for activities, but has noticed some lateral elbow pain. This has been going on he thinks since his injury. He notices it more now with progressive activities. He also notes some tightness at the laceration and repair site.

Allergies: Darvocet N-100
Current Meds: Bystolic (Note: BP med), Omega 9

PHYSICAL EXAM:
Vitals: HEIGHT: 6'0" WEIGHT: 185 lbs 0 oz BMI: 25.1
Appearance: No acute distress
Psychiatric: Mood and affect were appropriate.
Neuro: Alert and oriented x 3.

FOCUSED EXAM:
Right hand-full extension all digits with 5/5 resistance, wrist flexion 75 °, active wrist extension 45°, passively 60°. Mild scarring at laceration site with some skin puckering. Composite grip to palmar flexion crease.

Right elbow-extension 0°, flexion 140°, mild tenderness over lateral epicondyle, positive wrist extension test, positive middle finger extension test, no pain over radial tunnel, no pain over medial elbow.

X-ray: 2 views right elbow on 9/23/11-moderate ulnotrochlear arthrosis

**ASSESSMENT:**
**Diagnosis:** #1. Status post right hand extensor tendon repair, zone VII. #2. Right lateral tennis elbow

**PLAN:**
**PRESCRIPTION:** No data for Prescription

He has some scarring at the repair site, but good excursion of the extensor tendons as well as good strength. We will continue soft tissue mobilization and strengthening exercises. If scar becomes an issue over the next several months, he may require tenolysis of the tendons.

We also discussed the nature of tennis elbow. This is likely associated with his injury and now progressive activities as his extensor tendons have healed. This is a tendinosis of the wrist extensor tendons which originate on the lateral epicondyle of the distal humerus. Pain is often associated with wrist extension activities especially when the elbow is straightened. Treatment follows an extended period of therapy, initially aimed at pain management with progression into gentle strengthening and then endurance activities for these muscles. This type of treatment can be prolonged and is expected that symptoms will wax and wain throughout the therapy course. Splints are often helpful, especially a wrist cock-up splint and a counterforce brace to be worn over the proximal forearm. Although corticosteroid injections can be used to treat pain, they usually do not address the underlying issue and are thus judiciously used. Only after an extended period of nonoperative management is surgical excision of the diseased tissue considered. Understanding was acknowledged including the risks with surgery which include bleeding, infection, damage to surrounding structures, recurrence, pain, stiffness and possible need for future surgeries. All questions were answered.

At this point, he will begin a therapy program directed at improving the symptoms associated with tennis elbow. I will see him back in approximately 8 weeks for repeat clinical evaluation.

Matthew D. Welsch, MD
This document was electronically signed on 09/23/11

W.B. (Bill) Edwards, Jr., M.D. * Rakesh P. Chokshi, M.D.
Patrick K. Denion, M.D. * Anthony W. Alexander, M.D. * Barry L. Clark, D.O.
Nigel A.R. Watt, M.D. * Robert E. Elvington, Jr. M.D. *
Matthew D. Welsch, M.D. * Jason B. O'Dell, M.D. * Dewey N. Ervin, M.D. *

901 E. CHEVES ST., SUITE 100 - FLORENCE, SC 29505-2769
1560 FREEDOM BLVD., SUITE 100 - FLORENCE, SC 29505
(843) 662-5233 - FAX (843) 678-9003 - WWW.PDOA.COM

## Follow-up Examination

**PATIENT ID:** 178641

**PATIENT:** Victor Benjamin
**DOB:**
**Employer:** Rexam Inc

**Date of Service:** 8/11
**Age:**
**Occupation:**

**Referring Physician:** MFMC ER, , ;
**Other Physicians:** Daniels, Roosevelt, G;

**Date of Injury/onset:**

| Date: | Type: |
|---|---|
| 06/15/2011 | Injury |

**Chief Complaint:** Status post right hand extensor tendon repair and right lateral tennis elbow

**History of Present Illness:** Victor returns for followup. He states that he has had a recent EMG study, ordered by another physician, showing some type of nerve injury. He thought that I will be evaluating him for this today.

From an extensor tendon repair standpoint, he is doing well. He continues range of motion and strengthening exercises. The pain in his lateral elbow has resolved.

**Allergies:** Percocet N-100
**Current Meds:** Byetolic ( Note: BP med), Omega 9

**PHYSICAL EXAM:**
**Vitals:** HEIGHT: 6'0" WEIGHT: 185 lbs 0 oz BMI: 25.1
**Appearance:** No acute distress
**Psychiatric:** Mood and affect were appropriate.
**Neuro:** Alert and oriented x 3.

**FOCUSED EXAM:**
Right hand-full extension all digits with normal hyperextension of MP joint. Full composite grip. Brisk cap refill all digits less than 2 seconds. Sensate to light touch all digits.

Right wrist-extension 45°, flexion 30°, pronation 75°, supination 75°.

**X-ray:** None taken today

Report Date: December 06, 2011 Patient: Benjamin, Victor G DOS: 11/28/11

**ASSESSMENT:**
Diagnosis: -Status post right extensor tendon repairs

**PLAN:**
**PRESCRIPTION:** No data for Prescription

I have not received information regarding any peripheral nerve issue, and will contact worker's compensation to discuss any further treatment required.

In regards to his extensor tendon repairs, he has healed appropriately and is now 5 months out.

I will see him back after communication with worker's compensation.

Matthew D. Welsch, MD
This document was electronically signed on 11/28/11



W.R. (Bill) Edwards, Jr., M.D. * Rakesh P. Chokshi, M.D.
Patrick K. Denton, M.D. * Anthony W. Alexander, M.D. * Gary L. Clark, D.O.
Nigel A.R. Watt, M.D. * Robert E. Livingston, Jr. M.D. *
Matthew D. Walsch, M.D. * Jason B. O'Dell, M.D. * Dewey N. Ervin, M.D. *

901 E. CHEVES ST., SUITE 100 - FLORENCE, SC 29506-2769
1580 FREEDOM BLVD., SUITE 100 - FLORENCE, SC 29505
(843) 662-5233 - FAX (843) 678-9003 - WWW.PDOA.COM

## Follow-up Examination

PATIENT ID:

PATIENT: Victor Benjamin
DOB:
Employer: Rexam Inc

Date of Service: 01/18/12
Age:
Occupation: Maintenance

Referring Physician: MRMC ER, , ;
Other Physicians: Daniels, G; Roosevelt,

Date of Injury/onset:

| Date: | Type: |
|---|---|
| 08/15/2011 | Injury |

Chief Complaint: Right extensor tendon repairs (8-16-11)

History of Present Illness: Victor returns now 7 months out from his surgery. He has been doing well from an extension standpoint of his fingers and wrist. He is happy with these results.

He is more concerned about his neck pain. He has been seeing a neck specialist in Myrtle Beach, and is undergoing cervical spine injections. His last one was a couple days ago, and he feels like they're providing some improvement. He also had an EMG which he states showed he had carpal tunnel syndrome. This is not available for review today. He complains of numbness and tingling down the arm and into the fingertips. It involves all the fingertips. It is nearly constant. It is worse at night.

He also complains of medial scapular pain; he states occasionally he feels like there is a knot in the area.

Allergies: Darvocet N-100
Current Meds: Systolic () (Dosage: Note: BP med), Omega 9 () (Dosage: )

PHYSICAL EXAM:
Vitals: HEIGHT: 6'0" WEIGHT: 185 lbs 0 oz BMI: 25.1
Appearance: No acute distress
Psychiatric: Mood and affect were appropriate.
Neuro: Alert and oriented x 3.

FOCUSED EXAM:

Right wrist-positive Tinel's over median nerve, positive Phalen's, negative direct compression median nerve, 5/5 strength APB, no thenar atrophy.

Active wrist extension 45°, flexion 75°, full composite grip. Good extension strength with normal MP hyperextension all fingers except small finger which extends to zero.

Right shoulder-full range of motion, no palpable knot. Tender along paraspinal muscles.

X-ray: None taken today.

**ASSESSMENT:**
Diagnosis: -Status post right forearm extensor tendon repair, right hand numbness and tingling

**PLAN:**
PRESCRIPTION: No data for Prescription

He does seem to have evidence of carpal tunnel, but it has been treated and appears to be getting better for cervical radiculopathy by a spine specialist in Myrtle Beach.

From my standpoint, we will continue observation of the carpal tunnel syndrome. We discussed options. I think that if this treatment is improving his symptoms from a neck standpoint, his EMG study may be just an incidental finding. If he does not get better with his cervical spine treatment, I will be more than happy to reevaluate him.

I think in terms of his paraspinal muscular pain, he would benefit from some occupational therapy.

I will plan on seeing him back on an as needed basis.

Matthew D. Walsch, MD
This document was electronically signed on 01/18/12

[redacted]

Pee Dee Orthopaedic Associates, PA

Anthony W. Alexander, M.D., Rakesh P. Chokshi, M.D., Barry L. Clark, D.O., Patrick K. Denton, M.D., W.S. (Bill) Edwards, Jr., M.D., Robert E. Elvington, Jr., M.D., Dewey H. Ervin, M.D., Jason B. O'Dell, M.D., Chadley H. Runyan, M.D., Nigel A.R. Watt, M.D., Matthew D. Welsh, M.D.

901 E. CHEVES ST., SUITE 100 - FLORENCE, SC 29506-2769
(843)-662-5233 - FAX (843)-678-9201 - WWW.PDOA.COM

## Initial Examination

PATIENT ID:

PATIENT: Victor Benjamin
DOB:
Employer: Rexam Inc

Date of Service: 10/14/2013
Age:
Occupation: Maintanence

Referring Physician: Peter Hyman, M.D.
Other Physicians:

Roosevelt Daniel, M.D.

.MRMC ER.

Date of Injury/onset:

| Date | Type |
|---|---|
| 12/31/2008 | Injury |
| 08/15/2011 | Injury |

Chief Complaint: Right shoulder injury.

HPI:

Victor Benjamin is a 51 year old, left hand dominant male who works in maintenance who presents with right shoulder and neck pain after an injury he sustained at work on 6/15/11. He had an injury at work where he fell and injured the right side of his body, and also lost consciousness. He does not recall the entire mechanism injury to the right shoulder. I saw him in the past for extensor tendon injuries, and he is healed up in regards to that.

His complaint today is neck pain as well as shoulder pain. Most of his symptoms appear to be along the parascapular muscles of his neck, extending up into the cervical region and trapezium. This occurs on both sides. He also reports a catching sensation in the neck with rotation. He has difficulty with rotation to the right side. He says occasionally the pain will run down from his neck to his shoulder, but the source of his pain is not elicited by right shoulder motion.

His pain is about a 9/10 and constant. It is worse at night. It has been disrupting his sleep significantly more recently.

He has underwent cervical spine fusion on 02/18/13, and does relate a lot of his symptoms to around the time of that surgery.

Allergies: Darvocet N-100; doxepin; unspecified; trazodone; unspecified
Current Meds: Bystolic () (Note: BP med), Omega 9 ()
Past Med Hx: Hypertension
Surgical History: .None reported
Family History: Arthritis; Hypertension; Parents: Father-Living; Parents: Mother-Living

**Social History:** Alcohol use: None; Employment: Full Time; Marital Status: Married; Tobacco: Never Smoked

**REVIEW OF SYSTEMS:**
General, neuro, psychiatric, respiratory, cardiovascular, GI, GU, blood and lymph, EENT, musculoskeletal, skin and endocrine systems are normal except what is noted: .No abnormal findings known

**PHYSICAL EXAM:**
**Vitals:** HEIGHT / LENGTH: 6" 0' WEIGHT: 185 lbs 0 oz BMI: 25.1 TEMPERATURE: 97.6
**Appearance:** Normocephalic, atraumatic, No apparent distress. Well-nourished, well-developed.
**Psychiatric:** Mood and affect were appropriate.
**Neuro:** Alert and oriented x 3.

**FOCUSED EXAM:**
Right shoulder-abduction 135, forward flexion 135, external rotation 75, internal rotation T8, pain-free range of motion. Negative O'Brien's. Negative speed's. Nontender about shoulder girdle. Nontender a.c. joint. Moderate tenderness along medial parascapular muscles, no muscle atrophy. Skin intact. 5/5 strength supraspinatous.

**X-ray:** MRI scan of his right shoulder was reviewed from 8/2/13-type II SLAP tear, long head of biceps tendinopathy, subdeltoid bursal effusion.

**ASSESSMENT:**
**Diagnosis:** Right shoulder and neck pain

**PLAN:**
**PRESCRIPTION:** No data for Prescription

I had a long discussion regarding Mr. Benjamin symptoms, along with his case manager present. Most of his pain is associated with neck motion activities, and Mr. Benjamin feels like a lot of his pain continues to come from his neck. He has pain-free shoulder range of motion, but has developed some pain with overhead activities, again relating back to his parascapular muscles. He has no pain consistent with a SLAP tear, although MRI scan finding does show this. I do not feel like treating his SLAP tear will result in resolution of the pain symptoms he has right now. It seems like most of his symptoms may be coming from his cervical spine.

At this point, I recommended observation of his shoulder. I would not restrict his activities from a shoulder standpoint.

It is difficult to assess a specific PPI rating regarding his SLAP tear, as most of his symptoms again seem to be coming from his cervical spine.

I will see him back on an as-needed basis.

Matthew D. Weisch, MD
This document was electronically signed on 10/14/2013

# COLUMBIA NEUROSURGICAL ASSOCIATES, P.A.

www.columbianeurosurgical.com

Spine & Neurological Surgery

Thomas J. Holbrook, Jr., MD
William M. Rambo, Jr., MD
Randall G. Drye, MD
Scott B. Boyd, MD
Brett C. Gunter, MD
Karl A. Lozanne, MD

720 Rabon Road
Columbia, SC 29203
(803) 462-0423 - (F) 462-0432

Pain Medicine
Eva J. Rawl, MD

132 Sunset Court
W. Columbia, SC 29169
(803) 794-3700 - (F) 794-0322


**OFFICE CONSULTATION**

Patient: Victor G. Benjamin
Chart:
DOB:
Date: 1/22/13

CHIEF COMPLAINT: Neck pain, right-sided arm pain, bilateral arm numbness and tingling, imbalance.

HISTORY OF PRESENT ILLNESS: Victor Benjamin is a 50-year-old male who works for Rexam, a can manufacturing company. On 6/15/11, he suffered a work-related injury in which a metal piece from the machine he was working on fell on top of his head and onto his shoulder. Per report, the metal piece weighed over 20 pounds. He lost consciousness and was treated for a laceration to his scalp, his concussion, as well as his shoulder and right arm injury. He underwent right arm tendon repair.

He has continued to struggle with headaches, neck pain, right-sided interscapular and shoulder pain that radiates down into his right arm. He has developed difficulties with his balance and has had numbness and tingling worse on the right than the left. He has developed weakness in the right upper extremity. He denies any urinary or bowel symptoms. He has been managed with oral analgesics, physical therapy and more recently epidural steroid injections. The epidural steroid injections initially were effective at relieving his right-sided arm discomfort but the pain has returned. He underwent an MRI of the cervical spine which revealed significant cervical stenosis with disc/osteophyte complexes as well as what appeared to be spinal cord signal change. He was seen by another surgeon who recommended to undergo a surgical intervention. He presents to me for consultation and further discussion of treatment options.

HISTORIES: Please see patient history form for medications/allergies, past medical history, social history, family history, and review of systems which are well documented in the intake sheet dated 1/21/13 and have been reviewed and signed. The information contained is noncontributory except for that in the HPI. He lists no other past medical history. He had a right arm tendon repair in June 2011 at McLeod Hospital in Florence.

He has been out of work since his work-related injury. He is married with two children. He denies any tobacco use.

PHYSICAL EXAMINATION: Awake, alert, and oriented with normal and appropriate speech. Cranial nerves: VFF on confrontation. EOMI. Facial sensation and movements are symmetric. Hearing is normal. Palate elevates symmetrically and tongue protrudes in the midline. Motor: 4+/5 in the right deltoid, bicep, tricep, hand intrinsics. All other muscle groups are 5.5. Sensory: Decreased to light touch in left-sided C7 and C8 distributions. He is globally hyperreflexive with positive Hoffmann's sign bilaterally and two beats of clonus bilaterally. Reflexes: 4+ at the patellas, 3+ at the Achilles, with 3+ bilateral bicep and tricep reflexes. No Babinski or Hoffmann's sign present. Gait is normal. Finger-to-nose testing is normal.

DIAGNOSTIC STUDIES: EMG/nerve conduction study performed 11/3/11 at that time revealed a moderate degree of carpal tunnel syndrome in the right upper extremity as well as an ulnar neuropathy in the right upper extremity.

IMAGING STUDIES: MRI of the cervical spine performed 11/15/12 is available for my direct review. It comes on CD from Florence MRI and reveals what appears to be a small degree of spinal cord signal change at the C3-4 level. He has a generally narrow canal. At C3-4 I see a mild disc bulge with osteophytes and a mild degree of central canal stenosis. However, at C4-5, C5-6 and C6-7 he has disc/osteophyte complexes with a moderate degree of right-sided lateral recess and foraminal stenosis at 4-5 and 5-6 and a severe amount of lateral recess and foraminal stenosis on the left side at C6-7.

IMPRESSION/PLAN: Mr. Victor Benjamin suffered a work-related injury in June of 2011 and has presented to me with cervical myelopathy as well as signs and symptoms of cervical radiculopathy in both the right and left thumb. Imaging studies reveal multi-level degenerative disease with disc/osteophyte complexes at C4-5, C5-6 and C6-7 consistent with his signs and symptoms.

Considering his condition, I have recommended surgical intervention in the form of an anterior cervical discectomy and plated fusion at C4-5, C5-6 and C6-7. It is my opinion that the C3-4 level does not require any surgical intervention at this time because I am not seeing any significant neural compression despite the fact that it does appear that there is some spinal cord signal change at this level. I suspect that this is from his initial injury and contusion. Nonetheless, he is still manifesting radiculopathy and cervical myelopathy.

The surgical procedure offered was described in detail with the aid of models and diagrams. We discussed the potential benefits, treatment alternatives, and risks which include, but are not limited to: worsening of current status, the possible need for further procedures, the risk of infection, headaches, CSF leak, possible spinal nerve injury resulting in paralysis, infection, neck hematoma, hoarseness of voice, injury to major vessels causing hemorrhage, stroke, loss of language function, coma, and even death. No assurance was given whether symptoms would improve following the procedure. The patient voiced understanding of these risks and decided to proceed with the proposed procedure.

Mr. Benjamin does wish to proceed with surgery. I have discussed this in the company of the case manager, Ms. Rena Spencer. We will schedule this procedure at his convenience. He does understand that the surgical procedure itself is aimed at relieving pressure on the central canal as well as the nerve roots but not one that is going to result in complete recuperation of spinal cord function. There is the possibility he may continue to struggle with discomfort considering his injury. They displayed full understanding of this and wish to proceed. They do understand that he should refrain from any activities with the potential of head and neck injury which could result in worsening spinal cord function. They agree to comply.

Karl Lozanne, MD

Karl A. Lozanne, MD
THIS DOCUMENT HAS BEEN ELECTRONICALLY SIGNED
KAL/MAH CNAWT: 5000

# COLUMBIA NEUROSURGICAL ASSOCIATES, P.A.

www.columbianeurosurgical.com

Spine & Neurological Surgery

Thomas J. Holbrook, Jr., MD
William M. Rambo, Jr., MD
Randall G. Drye, MD
Scott R. Boyd, MD
Brett C. Carter, MD
Karl A. Lozanne, MD

720 Rabon Road 132 Sunset Court
Columbia, SC 29203 W. Columbia, SC 29169
(803) 462-0423 - (F) 462-0432

Pain Medicine
Eva J. Rawl, MD

(803) 794-3700 - (F) 794-0322


OFFICE VISIT
Patient: Victor G. Benjamin
Chart:
DOB:
Date: 08/20/2013
CNAWT:

Mr. Benjamin is a 51-year-old who underwent an anterior cervical discectomy and plated fusion at the C4-5, C5-6, and C6-7 levels on 2/18/13 after presenting with a cervical spondylotic myelopathy following a work-related injury that occurred in June of 2011. He had a large piece of metal land on his head and shoulder and presented with significant right upper extremity weakness as well as myelopathy. He has been struggling with headaches. Following his surgery, he initially made improvements, but continued to struggle with right-sided shoulder region discomfort. Follow-up x-rays of the cervical spine showed good placement of the interbody plate and screws with no apparent dislocation. On my evaluation, I was concerned of shoulder pathology. He had never had his shoulder evaluated previously. I recommended an MRI of the right shoulder and he returns following completion of this study.

Victor has continued to struggle with discomfort across his right shoulder region. He has discomfort that originates in the trapezius and right neck and traverses towards the shoulder girdle with some discomfort into the right upper arm. The initial improvement that was made after surgery is no longer present. He feels that his imbalance has persisted. He ambulates with the aid of a cane. He has been struggling with intermittent headaches.

IMAGING: MRI of the right shoulder, 8/2/13 at ImageCare, shows supraspinatus, infraspinatus, as well as intra-articular tendinopathy of the long head of the biceps tendon. There is a Type II SLAP tear. There is a shoulder joint effusion.

Victor Benjamin is a 51-year-old who is still recuperating from his spinal cord injury and has struggled with right-sided neck and shoulder discomfort. The MRI reveals shoulder pathology.

From a cervical spine perspective, I recommend continued out-of-work status. I explained to Victor that the surgical procedure was not intended to repair his spinal cord but rather to provide a decompression in hopes of getting continued improvement. He has been able to transition to the aid of a cane for ambulation, but is still feeling unsteady on his feet. There is some persistent abnormal sensation in the right upper and lower extremity at times, which he describes as coldness. I suspect that this is from the spinal cord abnormality.

Regarding his right shoulder, I feel that he would benefit from evaluation by a shoulder specialist. I suspect that this is contributing to the right trapezius and shoulder region pain.

I will leave treatment of his headaches condition to his treating neurologist.

I will see him back in the office following evaluation and treatment for his right shoulder. I do not feel that at this point he is in need of new imaging studies of his cervical spine.

I have discussed all of the above, as well as the treatment plan, with the case manager who was in the room with the patient today, as well as in the company of Victor Benjamin's wife.

Electronically signed by Karl Lozanne, MD at 08/23/2013 06:21

Karl Lozanne, MD
KL/cr
DOC#: 00004504/JOB#: 04852

# COLUMBIA NEUROSURGICAL ASSOCIATES, P.A.

www.columbianeurosurgical.com

Spine & Neurological Surgery

Thomas J. Holbrook, Jr., MD
William M. Rambo, Jr., MD
Randall G. Drye, MD
Scott B. Boyd, MD
Brett C. Gunter, MD
Karl A. Lozanne, MD

720 Rabon Road 132 Sunset Court
Columbia, SC 29209 W. Columbia, SC 29169
(803) 462-0423 - (F) 462-0432

Pain Medicine
Eva J. Rawl, MD

(803) 794-3700 - (F) 794-0322


**OFFICE VISIT**
**Patient:** Victor R. Benjamin
**Chart:**
**DOB:**
**Date:** 08/23/2013
**CNAWT:**

Mr. Benjamin is a 51-year-old who underwent an anterior cervical discectomy and plated fusion at the C4-5, C5-6, and C6-7 levels on 2/18/13 after presenting with a cervical spondylotic myelopathy following a work-related injury that occurred in June of 2011. He had a large piece of metal land on his head and shoulder and presented with significant right upper extremity weakness as well as myelopathy. He has been struggling with headaches. Following his surgery, he initially made improvements, but continued to struggle with right-sided shoulder region discomfort. Follow-up x-rays of the cervical spine showed good placement of the interbody plate and screws with no apparent dislocation. On my evaluation, I was concerned of shoulder pathology. He had never had his shoulder evaluated previously. I recommended an MRI of the right shoulder and he returns following completion of this study.

Victor has continued to struggle with discomfort across his right shoulder region. He has discomfort that originates in the trapezius and right neck and traverses towards the shoulder girdle with some discomfort into the right upper arm. The initial improvement that was made after surgery is no longer present. He feels that his imbalance has persisted. He ambulates with the aid of a cane. He has been struggling with intermittent headaches.

IMAGING: MRI of the right shoulder, 8/2/13 at ImageCare, shows supraspinatus, infraspinatus, as well as intra-articular tendinopathy of the long head of the biceps tendon. There is a Type II SLAP tear. There is a shoulder joint effusion.

Victor Benjamin is a 51-year-old who is still recuperating from his spinal cord injury and has struggled with right-sided neck and shoulder discomfort. The MRI reveals shoulder pathology.

From a cervical spine perspective, I recommend continued out-of-work status. I explained to Victor that the surgical procedure was not intended to repair his spinal cord but rather to provide a decompression in hopes of getting continued improvement. He has been able to transition to the aid of a cane for ambulation, but is still feeling unsteady on his feet. There is some persistent abnormal sensation in the right upper and lower extremity at times, which he describes as coldness. I suspect that this is from the spinal cord abnormality.

Regarding his right shoulder, I feel that he would benefit from evaluation by a shoulder specialist. I suspect that this is contributing to the right trapezius and shoulder region pain.

I will leave treatment of his headaches condition to his treating neurologist.

I will see him back in the office following evaluation and treatment for his right shoulder. I do not feel that at this point he is in need of new imaging studies of his cervical spine.

I have discussed all of the above, as well as the treatment plan, with the case manager who was in the room with the patient today, as well as in the company of Victor Benjamin's wife.

Electronically signed by Karl Lozanne, MD at 08/23/2013 08:21

Karl Lozanne, MD
KL/cr
DOC#: 00004504/JOB#: 04652

**BENJAMIN, VICTOR (id #2177119, dob: 04/19/1962)**
Encounter Summary

| Patient | | | |
|---|---|---|---|
| Name | BENJAMIN, VICTOR (54yo, M) ID# | Appt. Date/Time | 07/22/2016 10:30AM |
| DOB | | Service Dept. | MOPA_Gregg |
| Provider | KARL A. LOZANNE, MD | | |
| Insurance | Med Worker's Comp: SEDGWICK CLAIMS MANAGEMENT SERVICES<br>Employer Name : REXAM BEVERAGE<br>Case # : YYCC/51304<br>Case Injury Date : 06/15/2011<br>Prescription: ESI1 - Member is eligible. | | |

## Patient's Care Team

Insurance Adjuster (Worker's Comp): LAUREL MCPHERSON: Ph (813) 287-4140, Fax (813) 282-6783

## Chief Complaint

Neck/Cervical

## Problems

- Cervical myelopathy

## Medications

Reviewed Medications

| | | |
|---|---|---|
| amlodipine 5 mg tablet | 06/30/16 | filled |
| bupropion HCl 75 mg tablet<br>TAKE 1 TABLET BY MOUTH 2 TIMES A DAY | 01/21/16 | filled |
| clonazepam 2 mg tablet<br>TAKE 1 TABLET BY MOUTH TWICE DAILY | 06/22/16 | filled |
| diazepam 10 mg tablet<br>TAKE 1 TABLET BY MOUTH EVERY 8 HOURS | 07/13/16 | filled |
| oxycodone-acetaminophen 10 mg-325 mg tablet<br>TAKE 1 TABLET BY MOUTH TWICE DAILY | 06/25/16 | filled |
| pravastatin 20 mg tablet | 06/30/16 | filled |
| valsartan 160 mg tablet | 11/28/15 | filled |
| Vitamin D2 50,000 unit capsule | 07/20/16 | filled |

## Vaccines

None recorded.

## Allergies

Reviewed Allergies
DEMEROL

BENJAMIN, VICTOR (id # , dob:

## Past Medical History

Reviewed Past Medical History
Depression: Y
Epilepsy: Y
High Blood Pressure: Y
Mental Disorders: Y
Migraines: Y
Panic Attacks: Y
Poor Circulation: Y
Seizures/Epilepsy: Y

## Surgical History

Reviewed Surgical History

## Family History

Reviewed Family History

| | |
|---|---|
| Mother | - Arthritis |
| | - Hypertensive disorder |
| | - Hypercholesterolemia |
| Father | - Hypertensive disorder |
| | - Hypercholesterolemia |

## Social History

Reviewed Social History
Neuro - New Patient
Smoking Status: Never smoker
Back, leg, neck, arm - Steroid injections in back or neck: Y
Severity of pain: 8
Pain - Aching: Y
Pain - Burning: Y
Pain - Cramps: Y
Pain - Numbness: Y
Pain - Sharp: Y
Pain - Stiffness: Y
Pain - Throbbing: Y
Pain - Tingling: Y
Pain interferes - Bathing: Y
Pain interferes - Dressing: Y
Pain interferes - Grooming: Y
Pain interferes - Housework: Y
Pain interferes - Sleep: Y
Pain interferes - Work: Y
Pain frequency: constant
Painful activities - Bending: Y
Painful activities - Lying down: Y
Painful activities - Sitting: Y
Painful activities - Standing: Y
Painful activities - Walking: Y
Metal in body: Y
Cigar/Pipe Use: N
Chewing tobacco: none
Alcohol intake: Occasional
Number of children: 2
Marital status: Married
Diet: Regular
Work History: Disabled
Are you currently employed?: Y
Occupation: plant operator
Employer: rexam beverage

## Vitals

**BENJAMIN, VICTOR (id #: , dob: )**

Ht: 6 ft 07/22/2016 10:18 am | Wt: 180 lbs 07/22/2016 10:18 am | BMI: 24.4 07/22/2016 10:18 am

BP: 148/90 sitting 07/22/2016 10:23 am

## HPI

Mr. Benjamin continues to struggle with intermittent episodes of pain in the neck and at times in the arms. He explains that from day to day there are changes in his symptoms. He continues to struggle with abnormal sensations throughout his right upper extremity and at times shock like sensations going down his spine. He feels that the numbness and tingling in his hands limits their use.

## ROS

Patient reports exercise intolerance but reports no fever, no night sweats, no significant weight gain, and no significant weight loss. He reports vision change but reports no dry eyes and no irritation. He reports chest pain on exertion, arm pain on exertion, and shortness of breath when walking but reports no shortness of breath when lying down, no palpitations, and no known heart murmur. He reports muscle aches, muscle weakness, arthralgias/joint pain, and back pain but reports no swelling in the extremities. He reports weakness, numbness, seizures, frequent or severe headaches, migraines, and restless legs but reports no loss of consciousness. He reports depression and sleep disturbances but reports feeling safe in relationship and no alcohol abuse. He reports fatigue. He reports no difficulty hearing and no ear pain. He reports no frequent nosebleeds and no nose/sinus problems. He reports no sore throat, no bleeding gums, no snoring, no dry mouth, no mouth ulcers, no oral abnormalities, and no teeth problems. He reports no cough, no wheezing, no shortness of breath, no coughing up blood, and no sleep apnea. He reports no abdominal pain, no vomiting, normal appetite, no diarrhea, not vomiting blood, no dyspepsia, and no GERD. He reports no incontinence, no difficulty urinating, no hematuria, and no increased frequency. He reports no abnormal mole, no jaundice, and no rashes. He reports no swollen glands and no bruising. He reports no runny nose, no sinus pressure, no itching, no hives, and no frequent sneezing.

## Document Review

Available for my review- letter from Dr. Polletti- May 27, 2015;

## Physical Exam

Patient is a 54-year-old male.

awake, alert, answering questions appropriately
Cranial nerves are grossly intact
Motor strength in the right upper extremity is 4+/5 throughout, left upper extremity 5/5
breakaway in right lower extremity testing with strength 5/5; left lower extremity 5/5
Sensory exam to LT results is dysesthesia throught right upper extremity; symmetric to LT in lower extremities
Reflexes 3+ bilaterally at biceps tendon with mild Hoffman's on left; triceps 2+; patellar 4 bilaterally; Achilles 3 bilaterally, 2 beats of clonus on right
Gait is slow, unsteady, and careful. Able to walk and stand unassisted but uses aid of 4 pronged cane for balance.
Able to grab, hold, and manipulate his cane without difficulty.
Presents in soft cervical collar for support which he removes and puts on without difficulty.
Cervical ROM is limited in extension, flexion, and rotation. Incisions well healed.

## Assessment / Plan

Victor Benjamin is a 54-year-old who suffered a work-related injury in June 2011. A metal piece from atop the machine he was working on fell onto his head and shoulder resulting in a concussion, a left shoulder injury, and a spinal cord injury in the setting of cervical stenosis. He underwent multilevel anterior cervical decompression and fusion by me and subsequent posterior cervical decompression and fusion by Dr. Poletti. His shoulder injury was treated by an orthopedic physician. He has previously been released at maximal medical improvement by Dr. Poletti. I was asked to provide a repeat evaluation, determination if Mr. Benjamin has reached maximum medical improvement, and determination of whole person impairment rating.

I am in agreement that Mr. Benjamin has reached maximal medical improvement. He has a combined cervical and cortical spinal tract impairment.

Using the Guides to the Evaluation of Permanent Impairment, fifth edition, his impairment is as follows:
From a cervical spine perspective, he falls under the DRE cervical category IV with loss of motion segment due to surgical arthrodesis correlating to a whole person impairment rating of 28%. From a cortical spinal tract perspective, he falls

BENJAMIN, VICTOR (id # dob: )

under class I for bilateral upper extremity involvement and class II for effect on station and gait. His condition correlates to a whole person impairment of 19% and 19%, respectively. No impairment of bladder, anorectal, sexual, or respiratory function is warranted. Of particular note, there is no separate impairment for lower extremity involvement as this is encompassed by impairment to station and gait. Using the combined values chart (p.604), the total whole person impairment rating for Mr. Benjamin equals 53%.

I do not believe that he is in need of any further surgical intervention. Pain control would be under the guide of his pain management physician.
The above is my opinion to a reasonable degree of medical certainty. Feel free to contact me with any questions or concerns.

1. Cervical myelopathy
   G95.9: Disease of spinal cord, unspecified

Return to Office
None recorded.

Encounter Sign-Off
Encounter signed-off by Karl A. Lozanne, MD, 07/22/2016.

Encounter performed and documented by Karl A. Lozanne, MD
Encounter reviewed & signed by Karl A. Lozanne, MD on 07/22/2016 at 4:20pm

Florence Neurosurgery & Spine
1204 E. Cheves Street ~ Florence, S.C. 29506
ph: 843 673 0122 ~ fax: 843 673 0227
www.florenceneurosurgery.com

Andrew H. Rhea, M.D. James J. Brennan, M.D. Elizabeth A. Snoderly, D.O.
William B. Naso, M.D. Christopher G. Paramore, M.D.

Patient Name: VICTOR BENJAMIN
DOB:
Date of Service: 06/24/2011

## HISTORY

**Chief Complaint:** Headache

**History of Present Illness:** Mr. Benjamin is a 49-year-old black male was involved in an industrial accident in which he sustained a scalp laceration, a left parietal skull fracture, a closed head injury with concussion, and the right forearm tendon injury. We observed in the hospital. He underwent surgery for his tendon injury. He returns in follow-up today. He says he is having significant headaches. He complains of lightheadedness and dizziness. He also complains of some neck discomfort. He has pain in his right scapular region radiating into his right arm. He says he is supposed to start occupational therapy for his hand. He denies seizure activity.

**Past Medical History:** Hypercholesterolemia

**Past Surgical History:** As above

**Social History:** He is married and has two children. He works as a frontend maintainer. He denies tobacco or alcohol use or abuse.

**Review of Systems:** The patient denies chest pain, shortness of breath, or bowel or bladder incontinence. Please see the health history questionnaire for full details of the patient's review of systems, past medical history, and family and social history. The patient is to follow-up with his family physician for any positive review of systems.

## PHYSICAL EXAMINATION

VITAL SIGNS: BP 139/87 HR 66 RR 14 Temp. 97.9 Ht. 6-foot Wt. 190

NEURO/MUSCULOSKELETAL EXAM

Cognitive: The patient is awake alert and conversant, with fluent speech, normal affect, and fully oriented.

Cranial nerves: Pupils are equal and reactive. Extraocular movements are intact. The face is symmetric. The tongue is midline.

Motor exam: Both upper and lower extremities have normal bulk and normal tone with 5/5 strength throughout, including the left grip and both biceps, triceps, deltoids, iliopsoas, quadriceps, hamstrings, gastrocnemius, and anterior tibialis motor groups with good range of motion throughout. His right forearm and hand are in a splint.

Gait: No ataxia.

Florence Neurosurgery & Spine
1204 E. Cheves Street - Florence, S.C. 29506
ph: 843 673 0122 - fax: 843 673 0227
www.florenceneurosurgery.com

Andrew H. Rhea, M.D. James J. Brennan, M.D. Elizabeth A. Snoderly, D.O.
William B. Naso, M.D. Christopher G. Paramore, M.D.

Patient Name: VICTOR BENJAMIN
DOB:
Date of Service: 06/24/2011

MEDICAL DECISION MAKING

**Assessment/Diagnoses:** 1. Postconcussive syndrome 2. Parietal skull fracture 3. Neck pain with cervical myofasciitis

**Recommendations/Management Options:** We will proceed with cervical spine x-rays with flexion-extension views. Given his head injury and persistent headache and postconcussive symptoms I would recommend an MRI of the brain to make sure there has been no interval development of any extra-axial collections (particularly given his skull fracture) but also to see if there is any evidence for parenchymal injury. I think he would be a good candidate for vestibular rehab. We have also given him a prescription for Skelaxin may help with his myofascial complaints. We removed his scalp staples and left shoulder sutures as well.We will otherwise see him back in the office in 3 to 4 weeks. I discussed at length with the patient's case manager the patient's diagnosis, prognosis, and treatment plan. This was done in the patient's presence.

**Addendum:** AP, lateral, flexion and extension cervical spine x-rays were obtained. There is loss of the normal lordosis. There is degenerative disc disease throughout the cervical spine but no significant C5-6. There is an anterior osteophyte at C3-4. There is maintained in alignment from C1 to C7-T1. There is no gross instability with flexion and extension. I do not see any obvious fractures.

cc:

Electronically Signed by: William B. Naso, M.D. on Friday, June 24, 2011 1:22 pm

Florence Neurosurgery & Spine
1204 East Cheves Street
Florence, SC 29506
Phone (843) 673-0122
Fax (843) 673-0227

**NAME: BENJAMIN, VICTOR**
DOB:
Physician: NASO

**DATE OF EXAM: 06/27/2011**
Patient No:

**BRAIN WO**

**FINDINGS:**
Multiplanar images obtained, routine pulse sequences. Retention cysts in the floor of both maxillary sinuses. No sinus fluid levels. Orbits normal. Normal ventricles. No mass effect. Looks like prior left parietal craniotomy. No hemorrhage and restricted diffusion. No extraaxial collections.

**IMPRESSION:**
See above.

Scott Allen, MD

Electronic Signature

DD: 06/27/2011/DT: 06/28/2011/mes

Florence Neurosurgery & Spine
1204 E. Cheves Street ~ Florence, S.C. 29506
ph: 843 673 0122 ~ fax: 843 673 0227
www.florenceneurosurgery.com

Andrew H. Rhea, M.D. James J. Brennan, M.D. Elizabeth A. Snoderly, D.O.
William B. Naso, M.D. Christopher G. Paramore, M.D.

Patient Name: VICTOR BENJAMIN
DOB:
Date of Service: 07/05/2011

## TELEPHONE MESSAGE

DATE:
TIME OF CALL:
STAFF TAKING CALL: Pamela Muha, LPN
PATIENT'S HOME PHONE: (803) 428-3352
PATIENT'S WORK PHONE:
ALTERNATE CONTACT #: 803-316-6766

PHYSICIAN: DR NASO
REASON FOR CALL: I CALLED THE PATIENT AND NOTIFIED HIM THAT DR. NASO REVIEWED THE MRI OF THE BRAIN THAT WAS PERFORMED HERE ON 6-27-2011 AND THAT HE STATES THAT IT LOOKS OK. HE IS NOT SCHEDULED FOR A F/U AND ALSO STATES THAT HIS PT HAS NOT BEEN APPROVED. I TOLD HIM THAT I WOULD SPEAK WITH MRS. THERESA IN THE MORNING AND HAVE HER CHECK IN TO IT. HE VOICED UNDERSTANDING.

PHYSICIAN RESPONSE:

STAFF ACTION:

CALL RETURNED BY:

Electronically Signed by: William B. Naso, M.D. on Thursday, July 07, 2011 8:31 am

FLORENCE MRI & IMAGING
805 South Irby Street
Florence, SC 29501
(843) 292-0400 - fax (843) 292-0470

PATIENT: Benjamin, Victor
DOB:
MRN:
PATIENT PHONE: 803-428-3352
PHYSICIAN: George Sandoz, MD
DATE: 10/10/2011

EXAM: CERVICAL SPINE MRI WITHOUT CONTRAST

TECHNIQUE: Routine sequences obtained through the cervical spine. No intravenous contrast administered. The following sequences were performed on a GE Signa 1.5 Tesla magnet: Sagittal T2, sagittal T2 FS, axial T2, axial T2 GRE and coronal T1.

HISTORY: Intracranial injury, right side neck pain

FINDINGS: There is loss of the cervical curve. The cervical cord of normal size and signal intensity and the cervicomedullary junction is normal. No abnormal signal identified in the cervical spine. There is some lobular mucosal thickening inferiorly in the left maxillary sinus.

C2-C3: No abnormality.

C3-C4: There is a bulge of annulus with discogenic anterior and posterior osteophytes, bilateral uncinate joint osteophytes and there is mild bilateral osseous foraminal stenosis. There is total effacement of the ventral CSF and the AP diameter of the canal at the level of the disc is 9 mm consistent with a mild stenosis.

C4-C5: There is a mild degenerative bulge of annulus with discogenic osteophytes. Uncinate joint osteophytes are present on the right and there is effacement of the ventral CSF and the AP diameter of the canal at the level of the disc is 8-9 mm. There is mild osseous foraminal stenosis on the right.

C5-C6: Degenerative annular bulge that is asymmetric to the right and uncinate joint osteophyte on the right and the disc osteophyte complex causes moderate foraminal stenosis on the right. There is a borderline central canal stenosis and the AP diameter of the canal at the level of the disc is 9 mm.

C6-C7: There is a prominent uncinate joint osteophyte on the left and there is moderate to severe osseous foraminal stenosis on the left. The disc is normal. There is a small uncinate process osteophyte on the right.

C7-T1: No abnormality.

IMPRESSION:
1. Multilevel cervical spondylosis. There is a mild central canal stenosis at C3-4, C4-5 and C5-C6. There is foraminal stenosis on the right which is predominately osseous at C3-C4, C4-C5 and C5-C6.
2. C6-C7 there is moderate to severe osseous foraminal stenosis on the left.
3. Lobular inflammatory mucosal thickening in the left maxillary sinus.

Patient: Beniamin, Victor
MRN: :
Exam: CERVICAL SPINE MRI WITHOUT CONTRAST

Thank you for this consultation.

Margaret Lee, M.D.
ML / dg

DD: 10/10/2011
DT: 10/10/2011
Job: 13726986

This document has been electronically reviewed and signed.



FLORENCE MRI & IMAGING
805 South Irby Street
Florence, SC 29501
(843) 292-0400 - fax (843) 292-0470

**PATIENT:** Benjamin, Victor
**DOB:**
**MRN:**
**PATIENT PHONE:** 803-428-3352
**PHYSICIAN:** George Sandoz, MD
**DATE:** 10/15/2012

**EXAM:** MRI CERVICAL SPINE WITHOUT CONTRAST

**HISTORY:** 722.91-right sided neck pain. Right arm pain and tingling. Dizziness. Job injury 06/15/12.

**COMPARISON STUDIES:** Comparison made to 10/10/12.

**TECHNIQUE:** Sagittal T2 and FS-T2. Axial T2*-GRE and T2-FSE. Coronal T1.

**FINDINGS:** Polyps are present within the right maxillary sinus. Ethmoid sinus disease is also present. Mild thickening of the mucosa along the floor of the right maxillary sinus. Unremarkable paramidline brainstem and cerebellum.

Again seen is a developmentally small spinal canal. Decreased cord volume from C3 to C6-7. Mild increased signal within the left side of the cervical cord at C3-4.

C3-4: Moderate anterior endplate osteophytes. Mild annular bulge and moderate-sized Luschka joint osteophytes with narrowed C-4 neural foramina.

C4-5: Mild annular bulge with small endplate osteophytes. Small-moderate sized Luschka joint osteophytes with narrowed C-5 neural foramina, right greater than left.

C5-6: Mild degeneration of the disc and disc bulge. Small endplate osteophytes. Moderate right and small left-sided Luschka joint osteophytes.

C6-7: Severe narrowing of the left C-7 neural foramen secondary to large Luschka joint osteophytes. Mass effect on the extreme left lateral thecal sac anteriorly.

C7-T1 through T2-3: No disc displacements.

No facet arthritis. Mild edema of the endplates at C3-4 through C6-7.

**IMPRESSION:**
1. Cord compressive effects at C3-4 and C5-6 in particular. Bilateral C4 through C6 foraminal stenoses. Severe left C-7 bony neural foraminal stenosis.
2. Discogenic edema of the endplates at C3-4 through C6-7. Myelomalacia of the cervical cord at C3-4.
3. Again seen are left maxillary mucous retention cysts with some very mild interval improvement.

**Patient:** Benjamin, Victor
**MRN:**
**Exam:** MRI CERVICAL SPINE WITHOUT CONTRAST

Thank you for this consultation.

**Jeff Shramek, MD**
JS / bl

**DD: 10/15/2012**
**DT: 10/16/2012**
**Job: 16015130**

This document has been electronically reviewed and signed.

Jeffrey K. Shramek, MD.
Neuroradiologist

***

# IMAGECARE, LLC

710 RABON ROAD
COLUMBIA, SC 29203
803-462-3680

Name: Benjamin, Victor G
Patient ID:
DOB:
Acc#:
Patient Phone #: (803) 428-3352
***

Exam Date: 08/02/2016
Exam: MRI ST Neck wo
Reason:
Referrer: Lozanne, Karl a.

PROCEDURE: MRI SOFT TISSUE NECK FOR BRACHIAL PLEXUS

CLINICAL HISTORY: Right shoulder pain, right upper extremity weakness, claims work injury June 15, 2011.

TECHNIQUE: 5 mm thick sagittal T1, 4 mm thick axial T1, inversion recovery and MEDIC relative T2 weighted sequences are obtained with 4 mm thick coronal T1 and inversion recovery sequences.

FINDINGS:

Previous anterior cervical fusion and discectomy is noted at C4-5, C5-6 and C6-7. The cervical spine shows normal alignment on sagittal and coronal views. There is no significant central spinal canal stenosis throughout the cervical spine. There are no visible levels of significant foraminal stenosis identified.

There is no visible nerve root avulsion. There is limited visualization of the nerves of the brachial plexus with no abnormalities noted. The soft tissues of the neck appear unremarkable.

IMPRESSION:

1. STATUS POST CERVICAL SPINE FUSION WITH ACDF FROM C4 THROUGH C7, WITHOUT RESIDUAL SPINAL CANAL STENOSIS AND WITHOUT APPARENT NEURAL FORAMINAL STENOSIS.

2. NO APPARENT EVIDENCE OF BRACHIAL PLEXUS INJURY.

Timothy P. Close, M.D.
Electronic Signature
Date Finalized: 08/05/2013

DD: 08/02/2013 DT:08/05/2013

PATIENT: BENJAMIN, VICTOR
DOB:
MRN:
PHONE: 803-428-[illegible]52(Home)
PHYSICIAN: MICHAEL MCCARTHY, MD
EXAM DATE: 04/13/2015

EXAM: MR-Cervical Spine With and Without Contrast

REASON FOR EXAM: intervertebral disc d/o w/ myelopathy

COMPARISON: 10/15/2012.

TECHNIQUE: 1.5T MRI cervical spine utilizing sagittal and axial T1 and T2 sequences. Following uneventful IV contrast administration additional sagittal and axial T1 sequences were obtained.

CONTRAST: 15 mL Magnevist IV.

FINDINGS: No deformity of the cervicomedullary junction. There is again demonstration of extensive mucosal thickening in the paranasal sinuses.

The C2-C3 level is unremarkable.

At C3-C4, progressive degenerative disc disease although there may have been prior discectomy. There is evidence of posterior decompression and posterior fusion with posterior hardware present. The central canal is overall patent with mild stenosis to the left of midline. Mild hypertrophic endplate spur formation greater in paracentral locations. Abnormal increased T2 signal in the cord dorsolateral on the left is again noted, unchanged, and without abnormal contrast enhancement. Moderate left and mild right neural foraminal stenosis.

The patient is status post anterior cervical discectomy and fusion at the C4-C5-C6 levels with anterior hardware present and solid interbody fusion demonstrated. There is also continuation of this fusion to C5-C7 but without confirmation of osseous fusion across the disc space. The central canal is now patent through these levels as are the respective neural foramina other than moderate to severe bony stenosis of the left C7 neural foramen.

At C7-T1, there is a mild disc bulge with minimal central canal stenosis. Mild left and minimal right neural foraminal stenosis.

IMPRESSION:

1. Status post posterior decompression and posterior fusion at C3-C4. Minimal central canal stenosis asymmetric to the left due to hypertrophic spur formation. Persistent abnormal signal with no abnormal enhancement in the spinal cord on the left dorsolaterally suggests probable myelomalacia. Moderate left and mild right neural foraminal stenosis.
2. Status post ACDF at C4-C5-C6-C7. The central canal is patent through these levels. There is solid interbody fusion at C4-C5 and C5-C6 but not

PATIENT: BENJAMIN, VICTOR
DOB: 2
EXAM: MR-Cervical Spine With and Without Contrast
EXAM DATE: 04/13/2015

confirmed at C6-C7. There is at least moderate and potentially severe bony stenosis of the left C7 neural foramen.
3. Mild left C8 neural foraminal stenosis.
4. No unusual contrast enhancement.

James Thasing, DO

JAT/llh
DD: 04/13/2015 02:22 P
DT: 04/13/2015 05:34 P
Accession#: VS#: 120319892 CS#: 1342767
CC:

Electronically signed and Reviewed by James Thasing, DO 04/13/2015 08:59 P

**Progress Note**

Date: 4/15/2014
Provider: Roger Deal, M.D.
Visit Type: Scheduled

Patient: Benjamin, Victor (D)

**Content/Process**

Session Content:
Mr. Benjamin has had an enormous amount of interpersonal stress. He is responsible for taking care of both of his parents and his father has been sick in the hospital which has created moref stress for him in addition to dealing with his chronic pain.

We reviewed the way that he has been coping with the stressors and agreed that he has done a good job with the Klonopin, now that he has gotten the idea of being flexible on the dosing.

The only suggestion that I had was that since he has had some awakenings in the night and has taken a half of Klonopin but has not always fallen back to sleep. I suggested it would be better if he takes another half and did it within the first half an hour or so.

He is really doing much better than he did initially and now taking at least 2 mg sometimes up to 5 mg a night but on the average 2 to 3 mg and that has really helped him feel that he can cope much better.

He expressed a great deal of appreciation for the help that he has gotten from us since he has been coming here. He feels like he is on the right track now as he is clearly not going to be able to go back to work so he is going to change his direction in trying to cope better with the pain and just accept the fact that he is not going to be able to work in the same capacity as before but he can still be productive in another way.

**Interventions**

1) z - review target symptom list
2) z - review of recent stressors
3) z - educate regarding risks and benefits of medication
4) z- educated about relationship of chronic pain and worsening of target symptoms

Response to interventions: Improved control of anxiety and insomnia. Chronic pain remains a major problem.

**Medications**

Medication: Klonopin 2 to 4 mg q hs
Start Date: 3/15/2013

**Medication Plan**

Continue current medicines, with flexible doses on klonopin.

**Signatures**

Deal, M.D., Roger
e-Signed by Deal, M.D., Roger
Date: 04/22/2014 2:13 pm

**Progress Note**

Date: 6/17/2014
Provider: Lawrence Bergmann, Ph.D.
Visit Type: Scheduled

Patient: Benjamin, Victor
Date of Birth: Age: 52
Sex: Male

**Content/Process**

Other themes: reported continued pain, reported increased sensitivity to heat, remains very easily frustration, theme of session today was anger with others who do not behave in ways that the thinks they should

Session Content:
Very irritable today, strong theme of wrongs perpetrated on him by others including mother, father, son, work, wc, and others. Worked a bit to try to correct impressions but this just increased his frustration, will have to explore other options for management.

**Interventions**

1) active listening, provision of support for recovery
2) check in regarding psychological and physical status
3) ventilation related to details of current stressors
4) cognitive modification -- correction of errors
5) cognitive modification -- reviewed relationship between thoughts and feelings
6) cognitive modification -- development of more appropriate self-talk

Response to Interventions: ok, tough today

**Signatures**

Bergmann, Ph.D., Lawrence
e-Signed by Bergmann, Ph.D., Lawrence
Date: 06/17/2014 10:50 am

Progress Note

Date: 7/1/2014
Provider: Lawrence Bergmann, Ph.D.
Visit Type: Scheduled

Patient: Benjamin, Victor
Date of Birth:
Age: 52
Sex: Male

**Content/Process**

Other themes: reported no significant change, remains irritable and in conflict with many others, pain and physical limitations continue

Session Content:
Reported status and activities, reported conflict with a contractor and this remains a pattern of irritability. Discussed problem in detail, provided support and discussed options for management. Reviewed medications and he will be checking in with Dr. Deal today.

**Interventions**

1) active listening, provision of support for recovery
2) check in regarding psychological and physical status
3) ventilation related to details of current stressors
4) cognitive modification -- development of more appropriate self-talk

Response to Interventions: ok

**Signatures**

Bergmann, Ph.D., Lawrence
e-Signed by Bergmann, Ph.D., Lawrence
Date: 07/01/2014 12:28 pm

**Progress Note**

Date: 7/15/2014
Provider: Lawrence Bergmann, Ph.D.
Visit Type: Scheduled

Patient: Benjamin, Victor
Date of Birth: Age: 62
Sex: Male

**Content/Process**

Other themes: reported increased pain after spinal injection, reported that he is more irritable and that was displayed today, partner present for the session today

Session Content:
Discussed for a portion of the session his recent injection, issues with pain after. Expectations for treatment don't seem very realistic, lead to a discussion of how his pain and irritability impact others. Suggested increased separation between his feeling and his taking it out on others. On the other hand, suggested that his partner begin to set better limits. Discussed types of actions that she can take to reduce poor behavior.

**Interventions**

1) active listening, provision of support for recovery
2) check in regarding psychological and physical status
3) ventilation related to details of current stressors
4) normalization of trauma related symptoms
5) problem solving -- assist pt in generating options

Response to interventions: good

**Signatures**

Bergmann, Ph.D., Lawrence
e-Signed by Bergmann, Ph.D., Lawrence
Date: 07/15/2014 1:50 pm

Progress Note

Date: 7/22/2014
Provider: Lawrence Bergmann, Ph.D.
Visit Type: Scheduled

Patient: Benjamin, Victor
Date of Birth: Age:
Sex: Male

**Content/Process**

Other themes: reported continued pain, concerns about last injection, reported his primary concern are legal issues regarding recent surgery

Session Content:
Reported on his medical status, reported that he has lost a case at the wc commission and was most concerned about that today. Of course, could not really help him with this but did provide an opportunity for ventilation, support provided. Discussed medication, concerns about further injections.

**Interventions**

1) active listening, provision of support for recovery
2) check in regarding psychological and physical status
3) ventilation related to details of current stressors
4) problem solving – assist pt in generating options
5) cognitive modification -- development of more appropriate self-talk

Response to Interventions: good

**Signatures**

Bergmann, Ph.D., Lawrence
e-Signed by Bergmann, Ph.D., Lawrence
Date: 07/22/2014 12:37 pm

**Progress Note**

Date: 9/25/2014
Provider: Lawrence Bergmann, Ph.D.
Visit Type: Scheduled

Patient: Benjamin, Victor
Date of Birth: Age
Sex: Male

Content/Process

Other themes: reported that his father died suddenly yesterday, presented as upset and teary as would be expected

Session Content:
Session focused on the loss of his father with ventilation and support provided. Other conversation today centered on legal and medical access issues. Reported continued pain that is intolerable to him and not improving. Continues to hope for significant improvement.

Interventions

1) active listening, provision of support for recovery
2) check in regarding psychological and physical status
3) ventilation related to details of current stressors
4) normalization of trauma related symptoms
5) problem solving -- assist pt in generating options
6) provided information concerning grief/loss

Response to interventions: ok

Signatures

Bergmann, Ph.D., Lawrence .
e-Signed by Bergmann, Ph.D., Lawrence
Date: 09/29/2014 6:52 am

**Progress Note**

Date: 10/14/2014
Provider: Lawrence Bergmann, Ph.D.
Visit Type: Scheduled

Patient: Benjamin, Victor
Date of Birth: Age:
Sex: Male

**Content/Process**

Other themes: presented today as teary, frustated, grieving, has issues with medication, cognitive symptoms remain

Session Content:
reported his status as overwhelmed, reported that he continues to struggle with his father's death and other illness. Expectations for others are extremely high. Theme of the session was on his and other losses. Has been having issues with medication and is trying to sort them out with attending md at this point as Dr. Deal is not available. Ventilation and support provided.

**Interventions**

1) active listening, provision of support for recovery
2) check in regarding psychological and physical status
3) cognitive modification -- correction of errors
4) Ventilation related to details of current stressors
5) provide information about grief

Response to interventions: ok

**Signatures**

Bergmann, Ph.D., Lawrence
e-Signed by Bergmann, Ph.D., Lawrence
Date: 10/14/2014 12:23 pm

## Progress Note

Date: 4/21/2015
Provider: Lawrence Bergmann, Ph.D.
Visit Type: Scheduled

Patient: Benjamin, Victor
Date of Birth: Age:
Sex: Male

**Content/Process**

Themes Discussed

Other themes: noted no changes with continued pain, cognitive issues and irritability, reported his family had a birthday get together for him this past weekend, continues to put energy into legal conflicts

Session Content:
Discussed birthday and weekend activities, reviewed status with no change, noted a day of increased pain, has a clean bill of health for issues that may have been promoting weight loss, discussed his management. Continued work to limit impact of irritability via cognitive mod.

**Interventions**

1) active listening, provision of support for recovery
2) check in regarding psychological and physical status
3) cognitive modification – correction of errors
4) cognitive modification – development of more appropriate self-talk
5) ventilation related to details of current stressors

Response to interventions: good

**Signatures**

Bergmann, Ph.D., Lawrence
e-Signed by Bergmann, Ph.D., Lawrence
Date: 04/21/2015 1:06 pm

Progress Note

Date: 4/28/2015
Provider: Lawrence Bergmann, Ph.D.
Visit Type: Scheduled

Patient: Benjamin, Victor
Date of Birth: Age:
Sex: Male

Content/Process

Themes Discussed

Other themes: seemed pretty frustrated today after he reported that his car died on the way up, sees this as a never ending pattern of misfortune

Session Content:
Sessoin was focused on his frustration with his life and that was more or less topped off by his car blowing up on the way. Provided ventilatoin and some support for his misfortune today and also suggested that lumping together every single bad thing that is happening may not be accurate or helpful. Discussed his concerns about wc and he has not received his wc check in several weeks, discussed use of medication.

Interventions

1) active listening, provision of support for recovery
2) cognitive modification – correction of errors
3) cognitive modification – development of more appropriate self-talk
4) ventilation related to details of current stressors
5) review relationship between pain and psychological factors

Response to interventions: good

Signatures

Bergmann, Ph.D., Lawrence
e-Signed by Bergmann, Ph.D., Lawrence
Date: 04/29/2015 6:27 am

**Progress Note**

**Date:** 5/12/2015
**Provider:** Lawrence Bergmann, Ph.D.
**Visit Type:** Scheduled

**Patient:** Benjamin, Victor
**Date of Birth:** **Age:**
**Sex:** Male

**Content/Process**

Themes Discussed

Other themes: continued complaints of pain that he describes as sometimes unbearable, reported that he is having problems accessing care as well, continued complaints about the behavior of others, overinvolvement with others problems

Session Content:
Began session with long discussion of complaints regarding pain and getting an injection that has been recommended to him, apparently authorization has been denied. Went on to discuss the role of stress on pain management, challenged his involvement with family members and the resentment that he experiences, emotions that undoubtedly impact his level of pain.

**Interventions**

1) active listening, provision of support for recovery
2) check in regarding psychological and physical status
3) challenging client
4) cognitive modification -- correction of errors
5) cognitive modification -- reviewed relationship between thoughts and feelings

Response to Interventions: ok

**Signatures**

Bergmann, Ph.D., Lawrence
e-Signed by Bergmann, Ph.D., Lawrence
Date: 05/12/2015 1:41 pm

Progress Note

Date: 10/13/2015
Provider: Lawrence Bergmann, Ph.D.
Visit Type: Scheduled

Patient: Benjamin, Victor
Date of Birth: Age:
Sex: Male

Content/Process

Themes Discussed

Other themes: continued multiple physical complaints, continues reports of frustration with medical access, noted that pain in his neck is worse and not being attended to, no new psychological complaints, flood damage to home rpeortes

Session Content:
Reported on the damage to his home after recent storm, reported that pain has continued to be an issue for him, noted connection between symptoms and stress, continues to insert himself into others lives in a way that increases stress and caused conflict. Discussed alternate approaches to management of people in his life. Much ventilation and complaints about medical issues and treatment.

Interventions

1) active listening, provision of support for recovery
2) check in regarding psychological and physical status
3) ventilation related to details of current stressors
4) normalization of trauma related symptoms
5) review relationship between pain and psychological factors

Response to Interventions: ok

Signatures

Bergmann, Ph.D., Lawrence
e-Signed by Bergmann, Ph.D., Lawrence
Date: 10/13/2015 2:51 pm

## Progress Note

Date: 11/3/2015
Provider: Lawrence Bergmann, Ph.D.
Visit Type: Scheduled

Patient: Benjamin, Victor
Date of Birth: Age:
Sex: Male

**Content/Process**

Themes Discussed

Other themes: came a day early but were able to accomodate him, reported that he had a very difficult weekend with a high level of anger related to an incident with his son

Session Content:
After check in, session focused on incident with his son. Described the intenelly of his anger as very high. Spent a good bit of the session justifying hiw positions, I did not challenge as he did not ask me for my opinion. Reinforced his efforts at understanding and recognizing just how bad things were getting. Primarily ventilation.

**Interventions**

1) active listening, provision of support for recovery
2) ventilation related to details of current stressors
3) normalization of trauma related symptoms
4) cognitive modification -- development of more appropriate self-talk

Response to Interventions: ok

**Signatures**

Bergmann, Ph.D., Lawrence
e-Signed by Bergmann, Ph.D., Lawrence
Date: 11/03/2015 12:28 pm

# Progress Note

Date: 12/29/2015
Provider: Lawrence Bergmann, Ph.D.
Visit Type: Scheduled

Patient: Benjamin, Victor
Date of Birth: Age:
Sex: Male

## Content/Process

Themes Discussed

Other themes: reported that he remains primarily concerned about pain, remains irritable and focused on advice giving and controlling others, reported continued depressed mood

Session Content:
Reported status and activities, reported on periods of pain and response to it. Reported on specific incidents with his family where he continues to be irritable and difficult to deal with. I continued to challenge this with some headway, he does not always see the consequences of his behavior and attitude toward others. Discussed legal issues and I reframed his perception of what "should" be the outcome.

## Interventions

1) active listening, provision of support for recovery
2) check in regarding psychological and physical status
3) TF-CBT - introduction
4) cognitive modification -- correction of errors
5) cognitive modification -- development of more appropriate self-talk

Response to Interventions: good

## Signatures

Bergmann, Ph.D., Lawrence
e-Signed by Bergmann, Ph.D., Lawrence
Date: 12/29/2015 3:51 pm

# Progress Note

Date: 1/12/2016
Provider: Lawrence Bergmann, Ph.D.
Service: 90834 Psychotherapy, 45 minutes
Session Time: 12:00 pm - 12:45 pm Duration: 45 mins.
Visit Type: Scheduled

Patient: Benjamin, Victor
Date of Birth: Age:
Sex: Male

## Content/Process

Themes Discussed

Other themes: reported continued pain and continued complaints, reported continued efforts to involve himself in the legal system, concerns about financial future

Session Content:
Reported status and activities, reported that his pain has been rather difficult. Remains focused on pain and is pretty inactive and uninvolved. Discussed his legal concerns and issues, is very concerned about future financial situation. I continued to stress the importance of purpose, activity and looking ahead to his future after wc. Expressed my concerns about his lifestyle after settlement.

## Interventions

1) active listening, provision of support for recovery
2) ventilation related to details of current stressors
3) problem solving -- assist pt in generating options
4) cognitive modification -- correction of errors
5) cognitive modification -- development of more appropriate self-talk

Response to interventions: ok

## Signatures

Bergmann, Ph.D., Lawrence
e-Signed by Bergmann, Ph.D., Lawrence
Date: 01/13/2016 6:42 am

# Progress Note

Date: 2/16/2016
Provider: Lawrence Bergmann, Ph.D.
Session Time: 11:15 am - 12:00 pm Duration: 45 mins.
Visit Type: Scheduled

Patient: Benjamin, Victor
Date of Birth: Age:
Sex: Male

## Content/Process

Themes Discussed

Other themes: reported continued pain and physical limitations, reported that he is now feeling much better as he has withdrawn from the antidepressant, remains irritable, no new complaints

Session Content:
Discussed status and activities, continues to struggle with a high degree of frustration and irritability and session is a constant balancing of anger and working to be more rational. Discussed changes without some of the medication and he is doing much better, discussed the general learnings from his medical experiences. Continued ventilation about family members and others.

## Interventions

1) active listening, provision of support for recovery
2) check in regarding psychological and physical status
3) ventilation related to details of current stressors
4) cognitive modification -- correction of errors
5) cognitive modification -- development of more appropriate self-talk

Response to Interventions: good

## Signatures

Bergmann, Ph.D., Lawrence
e-Signed by Bergmann, Ph.D., Lawrence
Date: 02/16/2016 12:44 pm

## Progress Note

Date: 3/1/2016
Provider: Lawrence Bergmann, Ph.D.
Service: 90834 Psychotherapy, 45 minutes
Session Time: 10:30 am - 11:15 am Duration: 45 mins.
Visit Type: Scheduled

Patient: Benjamin, Victor
Date of Birth: Age:
Sex: Male

**Content/Process**

Themes Discussed

Other themes: reported no new complaints, continues to to report both cognitive and depressive symptoms, remains irritable and easily frustrated

Session Content:
Discussed status and activities, discussed issues with finding a psychiatrist and available options. Most of the session was focused on dissatisfaction with various people in his life, continued today to provide balance and cognitive restructuing. Noted continued concerns about outcome of legal issues associated with wc case.

**Interventions**

1) active listening, provision of support for recovery
2) check in regarding psychological and physical status
3) ventilation related to details of current stressors
4) normalize and validate
5) problem solving -- assist pt in generating options

Response to Interventions: ok

**Signatures**

Bergmann, Ph.D., Lawrence
e-Signed by Bergmann, Ph.D., Lawrence
Date: 03/02/2016 8:21 am

## Patient Cancellation Note

Date: 3/8/2016
Provider: Lawrence Bergmann, Ph.D.
Type: Patient Cancellation

Patient: Benjamin, Victor
Date of Birth: --- Age:
Sex: Male

Reason: sick

Electronic Signature by Provider Pending

# Progress Note

Date: 3/15/2016
Provider: Lawrence Bergmann, Ph.D.
Service: 90834 Psychotherapy, 45 minutes
Session Time: 11:15 am - 12:00 pm Duration: 45 mins.
Visit Type: Scheduled

Patient: [illegible]jamin, Victor
Date of Birth: [illegible] Age:
Sex: Male

## Content/Process

Themes Discussed

Other themes: reported that he has been very irritable, angry and upset during the past week, remains overinvolved in others business and this is impacting his condition

Session Content:
Discussed status and activities, discussed period when he has been so mad. Same basic approach with providing information about head injury and anger and then focusing on better management. In this case, focused on setting boundaries and knowing when he should and should not intervene. Emphasized the consequences of intervening when there may be no reasonable solution or outcome.

## Interventions

1) active listening, provision of support for recovery
2) cognitive modification -- correction of errors
3) cognitive modification -- development of more appropriate self-talk
4) ventilation related to details of current stressors

Response to interventions: good

## Signatures

Bergmann, Ph.D., Lawrence
e-Signed by Bergmann, Ph.D., Lawrence
Date: 03/15/2016 2:15 pm

# Progress Note

Date: 4/6/2016
Provider: Lawrence Bergmann, Ph.D.
Service: 90834 Psychotherapy, 45 minutes
Session Time: 11:00 am - 11:45 am Duration: 45 mins.
Visit Type: Scheduled

Patient: Benjamin, Victor
Date of Birth: Age:
Sex: Male

## Content/Process

Themes Discussed

Other themes: continues to present as frustrated and irritable, primary concerns today related to legal issues and concerns about his future

Session Content:
Much ventilation and dissatisfaction regarding efforts to settle his wc case. Described a recent meeting and just how far from a settlement he seems to be. Not happy with his representation or the wc system. Worked during the session to balance his concerns with moderation. Provided him information and continued cognitive managemenet.

## Interventions

1) active listening, provision of support for recovery
2) ventilation related to details of current stressors
3) normalize and validate
4) review relationship between pain and psychological factors

Response to interventions: ok

## Signatures

Bergmann, Ph.D., Lawrence
e-Signed by Bergmann, Ph.D., Lawrence
Date: 04/07/2016 6:03 am

# Progress Note

Date: 5/4/2016
Provider: Lawrence Bergmann, Ph.D.
Service: 90834 Psychotherapy, 45 minutes
Session Time: 10:00 am - 10:45 am Duration: 45 mins.
Visit Type: Scheduled

Patient: Benjamin, Victor
Date of Birth: Age:
Sex: Male

## Content/Process

Themes Discussed

Other themes: accompanied by wife today, no new complaints, noted continued pain and physical limitations, continued frustration with legal issues and very easily irritated

Session Content:
Session began with check in and did check in with partner as well, no new complaints. Session was primarily check in with continued cognitive modification of thoughts that lead to anger. Challenged exaggerations and magnification. Ventilation concerning legal issues.

## Interventions

1) active listening, provision of support for recovery
2) check in regarding psychological and physical status
3) ventilation related to details of current stressors
4) cognitive modification – correction of errors
5) cognitive modification – development of more appropriate self-talk

Response to Interventions: good

## Signatures

Bergmann, Ph.D., Lawrence
e-Signed by Bergmann, Ph.D., Lawrence
Date: 05/04/2016 2:39 pm

(15) List any medications you currently take: Ultracet 37.5 Mg, Imipact 150Mg, Zanaflex 4 mg, Pravastatin 40 mg, Xanax .25 Mg, Diovan 160 Mg

(16) Do you have allergies to any medications? YES NO
If YES, list the medications: _____

(17) Do you currently have any problems in the following areas? If YES, please provide additional information.

| | YES | NO | Details |
|---|---|---|---|
| Eyes (poor vision, eye pain, tearing, redness, etc.) | ✓ | | when head hurts sharp pain, eyes hurt too |
| General / constitutional (fever, heat stroke, weight loss, weight gain, unusually tired) | | ✓ | |
| Ears, nose, throat (hard of hearing, stuffy nose, earache, cough, dry mouth, etc.) | ✓ | | ringing in both ears |
| Cardiovascular (high bp, racing pulse, etc.) | | ✓ | |
| Respiratory (congestion, wheezing, short of breath, etc.) | | ✓ | |
| Gastrointestinal (stomach upset, diarrhea, constipation, hernia, ulcers, etc.) | | ✓ | |
| Genital, kidney, bladder (painful urination, frequent urination, impotence, yellow jaundice, etc.) | | ✓ | |
| Females are you pregnant? Nursing? | | | |
| Muscles, bones, joints (joint pain, stiffness, swelling, cramps, arthritis, etc.) | ✓ | | arms, wrists, hands contracted, stiff, painful |
| Skin (pimples, warts, growths, rash, etc.) | | ✓ | |
| Neurological (numbness, headache, seizures, paralysis, etc.) | ✓ | | headaches, Seizures numbness on mal for Seizures. |
| Psychiatric (anxiety, depression, insomnia) | ✓ | | Dr. Deale / Dr. Bergman |
| Endocrine (diabetes, hypothyroid, etc.) | | ✓ | |
| Blood / lymph (bleeding, cholesterolemia, anemia, problems related to blood transfusion, etc.) | | ✓ | |
| Allergic / immunologic (sneezing, swelling, redness, itching, hives, lupus, etc.) | | ✓ | |

(18) Social History
Have you ever had a blood transfusion? .....YES (NO)

Do you drink alcohol .....YES (NO) If YES, how much? _____

Do you presently smoke?... YES (NO) If YES, how many packs per day? _____
How many years? _____

Are you a past smoker?..... YES (NO) If YES, how many packs per day? _____
How many years? _____

# SOUTHEASTERN SPINE INSTITUTE

**BENJAMIN, VICTOR**
Patient
DOB:

**History of present illness:** Mr. Benjamin is being seen as a new patient today. He was referred by Dr. Sandoz. He is complaining of an achy pain in his neck and right shoulder blade region with numbness and tingling down his right arm and to some degree his left arm. He is also complaining of a stabbing and achy low back pain with achiness behind both knees. He quantifies his pain as being 75 percent in the back, 25 percent in his legs, 75 percent in his neck, and 25 percent in his arms. He states that he had an accident in June of 2011 where a 30-pound guard fell on his head, shoulder, and back. He did suffer a skull fracture and some tendon damage in his right arm due to this accident. His symptoms are made worse with all activities from sitting, standing, rising from sitting, leaning forward, walking, lying on his side, back, or stomach, driving, coughing, sneezing, and bending forward. He rates his pain as 8/10 on a pain scale. He states that he does get some relief with pain medications, but they do put him to sleep. He has tried three cervical epidural steroid injections of which the second worked very well and lasted four to five months, but the last one did not give him any lasting relief. He has tried physical therapy with no lasting relief as well. He does have an MRI of his cervical spine from October 15, 2012. Today I am recommending AP/lateral lumbar films as well. He denies any loss of bowel/bladder function, any paralysis, or any focal muscle weaknesses.

**Past medical history:** Hypertension, concussion, hypercholesterolemia, seizures.

**Past surgical history:** Right arm tendon repair.

**Current Medications:** Ultracet, Vimpat, Zanaflex, Pravastatin, Xanax, Diovan.

**Allergies:** DEMEROL.

**Family history:** Hypertension, diabetes.

**Social history:** He is currently disabled. He used to work for a beverage company driving a forklift. He denies any alcohol, tobacco, or illicit drug use. He is a never smoker.

**Review of systems:** Positive for eye pain with headaches, ringing in both ears, joint pain in his arms or his hands, headaches, seizures, anxiety, and depression. He denies any fevers, chills, night sweats, changes in weight, changes in appetite, chest pain, palpitations, shortness of breath, dyspnea, wheezing, kidney/bowel/bladder dysfunction, paralysis, diabetes, and hypothyroidism.

(Continued)

1105 Chuck Dawley Blvd. Mt. Pleasant, SC 29464 (843) 849-1551 Fax (843) 884-0629

# SOUTHEASTERN SPINE INSTITUTE

**BENJAMIN, VICTOR**
Patient
DOB:

Page 2

**Physical examination:** He is a well-developed, well-nourished male alert and oriented x3 in no acute distress. He is 6 feet tall weighing 190 pounds. He is ambulatory with a non-antalgic gait. He does have some weakness noticed at the deltoids and at the biceps/triceps bilaterally. He has diminished grip strength more pronounced on the right than on the left. He does have resisted thumb extension weakness bilaterally more pronounced on the right than on the left. His DTRs at the brachioradialis are 2+ and symmetric. He does have a slightly hyperreflexic biceps DTR on the right compared to the left. He has negative straight leg raising bilaterally. Strength in the lower extremity is 5/5 and symmetric. He does have intact DTRs 2+ at the patellar and Achilles tendons bilaterally. No lower extremity edema noted. No vascular lesions. No long tract signs. He does have a negative Hoffmann's sign in the upper extremities bilaterally.

Steven C. Poletti, M.D.

SCP/RA/dmp
T- 11/13/12

1106 Chuck Dawley Blvd. Mt. Pleasant, SC 29464 (843) 849-1551 Fax (843) 884-0629

# SOUTHEASTERN SPINE INSTITUTE

**BENJAMIN, VICTOR**
Patient
DOB:
November 5, 2012

Victor has a difficult problem in that he has posterior stenosis with cervical myelomalacia secondary to a cord contusion at the C3-4 level. He was in an accident 18 months ago, which had the effect of causing him to have a head injury with unconsciousness. He has some persistent symptoms into his arms and legs. He has a positive Lhermitte's sign.

He has myelomalacia in his cord. He has severe stenosis. He has spasticity. He has a positive Babinski, upgoing toes, hyperreflexia, positive Hoffmann's sign, severe stenosis at C3-4 with myelomalacia. Other levels have some spondylitic changes, but this C3-4 myelomalacia and cord contusion necessitates posterior cervical decompression. I have seen him and examined him with Dr. Rick Frisch. I do think that posterior cervical decompression with fusion is indicated.

He understands the severity of the procedure and that he certainly has to do it or else he will worsen, and he wishes to proceed. We will go ahead in the coming weeks pending surgical approval.

Steven C. Poletti, M.D.

SCP/dmp
T- 11/6/12

1106 Chuck Dawley Blvd. Mt. Pleasant, SC 29464 (843) 849-1551 Fax (843) 884-0529

1106 Chuck Dawley Blvd., Suite 200 ■ Mt. Pleasant, SC 29464

Patient Name: Victor Benjamin Encounter Date: 1/20/2014 Date of Birth:
Account Number:

Mr. Benjamin returns to the office today with complaints of neck, shoulder, and right arm pain. He has continued issues with difficulty walking and imbalance. He denies any bowel or bladder issues.

Mr. Benjamin has had somewhat of an unusual history over the past year or two. He was seen in 2012 with cervical myelomalacia at C3-4. Then, he had surgery through his work comp carrier in Columbia. He had three level fusion surgery done by Dr. Lozanne at C4-5, C5-6, and C6-7. He did not have surgery at C3-4.

He's had AP and lateral views of the cervical spine today, which show appropriate positioning of the anterior plate and interbodies at C4-5, C5-6, and C6-7. No settling or shifting has been detected. There's a solid-appearing fusion. There's continued evidence of disc-height collapse, spondylosis, and kyphosis noted at C3-4.

He has had some persistent issues. He had a laceration on his right arm, but no further treatment was recommended by the upper extremity specialist.

His neurologic exam continues to show lower extremity hyperreflexia. He has an altered gait. He has loss of motion in his cervical spine. Hand myelopathy signs are seen.

Ultimately, he requires an immediate cervical MRI scan with and without contrast. We will reassess this C3-4 problem that he had more than a year ago. We will discuss treatment options with him once the images are obtained.

**Diagnosis Codes:**
722.81 POSTLAMINECTOMY SYND CERVICAL

**Impression:** Cervical pain.

**Treatment Plan:** Valium 5 mg tablets were prescribed; side effects were discussed and appropriate instructions were provided. An MRI of the cervical spine was ordered. The patient is to return when the result of MRI is available.

Seen By: Justin P. Swain, PA

Date:1/20/2014
sk

DIGITALLY SIGNED

SOUTHEASTERN SPINE INSTITUTE
1105 Chuck Dawley Blvd., Suite 200 E Mt. Pleasant, SC 29464

Patient Name: Victor Benjamin  Encounter Date: 8/14/2014  Date of Birth:
Account Number

**History of Present Illness:** Mr. Benjamin is seen today for a 1 month follow-up appointment. He is approximately 6 months status post cervical fusion at the C3-4 level. He is fused from C-4 through C-7 which was done previously. He is someone who continues to have neck and low back pain. He had a right sided L4-5 LESI done July 10, 2014. He states this seemed to exacerbate the pain for approximately 2 weeks. He then started feeling some slight improvement. He has good days and bad days. He continues to have right sided back pain that radiates through his right buttock and leg. He has had issues with balance as of late and is using a cane for ambulation. He denies any bowel or bladder disturbance, any paralysis. He continues to require pain medication which he gets from another provider.

He has weaned out of his cervical collar at this point in time. He does continue to wear this when driving or when his neck muscles feel fatigued. He has been doing well otherwise without the collar. He has neck pain and shoulder pain. He continues to experience numbness into his hands.

**Past Medical History:** High Cholesterol (272.0 ), Hypertension 401.9 (401.9 ), headaches

**Current Medications:** NuLYTELY with Flavor Packs 420 gram Oral Solution SolR, metoclopramide 10 mg tablet Oral, Norco 10 mg-325 mg tablet 2 by mouth as directed 30 min prior to MRI, Valium 5 mg tablet 3 by mouth as directed 30 minutes before MRI, pravastatin 40 mg tablet Oral, clonazepam 2 mg tablet Oral, Valium 10 mg tablet 1 by mouth TID prn spasms, oxycodone 10 mg tablet 1-2 by mouth prn pain, hydrocodone 10 mg-acetaminophen 325 mg tablet Oral, doxycycline hyclate 100 mg capsule Oral, diazepam 5 mg tablet Oral, ciprofloxacin 0.3 % Eye Drops Opht, amlodipine 5 mg tablet Oral, amoxicillin 500 mg-potassium clavulanate 125 mg tablet Oral, CIPRODEX 0.3 %-0.1 % Ear Drops, Susp DrpS Otic, fluticasone 50 mcg/actuation Nasal Spray, Susp SpSn Nasl

**Drug Allergies:** Demerol

**Imaging:** AP/lateral views of his cervical spine were reviewed with him today. There is appropriate positioning of the screws at the C3-4 level. There is evidence of solid fusion at the C-4 through C-7 level. He did have an updated lumbar MRI scan that shows disc disruption and right sided disc protrusion at the L4-5 level. He has a sacralized segment at L5-S1. There is loss of signal at the L3-4 level.

**Diagnosis Codes:**
722.81 POSTLAMINECTOMY SYND CERVICAL
722.10 DISPLACED LUMBAR INTERVERT DISC

**Treatment Plan:** His x-rays are stable. He is to continue with off duty status. We will keep a close eye on him regarding his neck and low back. We discussed the possibility of him seeing a physical therapist to work on balance and gait. This is something he could potentially benefit from. We will see him back in the office in 1 month's time for re-

DIGITALLY SIGNED Lane Tuggle, PA-C
9/18/2014

evaluation. We discussed that if he were to have any worsening pain or changes in his symptoms he will contact our office for a sooner appointment. Otherwise we will see him in 1 month for updated cervical x-rays.The patient is instructed to call us if pain persists or get worse. Patient to return in 1 month for follow up.

Seen By: Lane Tuggle, PA-C

LT/dam

X-ray: AP/lateral views of his cervical spine were reviewed with him today. There is appropriate positioning of the screws at theC3-4 level. There is evidence of solid fusion at the C-4 through C-7 level.

1106 Chuck Dawley Blvd., Suite 200 ■ Mt. Pleasant, SC 29464

Patient Name: Victor Benjamin  Encounter Date: 3/19/2015  Date of Birth:
Account Number

Mr. Benjamin is being seen today for follow up visit. He is status post posterior instrumentation of C3-4 level with previous anterior fusion status post accident while at work. We continue to monitor him. He continues to have chronic pain complaints in his right upper extremity. He describes nummbness, tingling, and upper extremity weakness, all which has not changed since last visit. He does still have burning into his right hand and myelopathic sign seen. He has difficulty with some ADLS and fine motor movements involving hands. He is requiring Norco 2-3 times daily for pain control which is provided by his PCP, Dr. Belmor. He states he has had a 20 pound weight loss in the past two months which is unintentional. This is being worked up by his PCP. He denies any fever, chills, night sweats, cough, recent hospitalization.

On physical exam he is alert and oriented x 3 with an appropriate affect. He has decreased strength on the right compared to the left with shoulder abduction, tricept extension, wrist flexion. Negative Hoffman sign. He is ambulating with cane.

Xrays of the cervical spine were obtained and reviewed today and compared to previous films in January. He has stable implementation at the posterior C3-4 level. Previous anterior fusion C4-7 is also stable and unchanged.

**Diagnosis Codes:**
723.4 Cervical Radiculitis

**Treatment Plan:** Mr. Benjamin continues to have chronic pain and functional limitations. Overall his xrays and physical exam are unchanged. He is to undergo EMG and MRI with Dr. Sandalls which I would like to follow up with. I have written prescription for Brown's cream today for adjunct pain relief. He will follow with us in the office in 3 months. I have advised him to call sooner with any concerns. Patient to return in 3 months for follow up.

Justin Swain, PAC

DIGITALLY SIGNED Justin P. Swain, PA
3/24/2015

# PATIENT MEDICATION AGREEMENT

Patient Name: Victor Benjamin Pharmacy: CVS

Doctor: Dr. Poletti Family Doctor: Dr. Belnor

**Please read and initial the following:**

VB Only your physician at The Southeastern Spine Institute will prescribe narcotic medication for you. It is our legal obligation to contact DHEC if we find you are getting medication from any other providers.

VB You agree not to ask for narcotic medications from any other doctor without the knowledge and assent of your physician at The Southeastern Spine Institute.

VB You agree to keep all scheduled appointments, not just with your physician, but also with recommended therapists and physicians. Three or more missed appointments or same day cancellations will lead to patient dismissal.

VB You agree to provide regular urine samples for drug screens. Positive tests for any illegal substances, or narcotics not prescribed by your pain doctor, may result in your dismissal and referral elsewhere for substance abuse evaluation and management.

VB No prescriptions will be refilled early.

VB No prescriptions will be refilled if you lose, destroy, or have any of your medication stolen.

VB Prescription refills will be authorized only during regular office hours. If you want to refill your prescription, call two working days in advance of renewal date.

VB Patients taking chronic narcotics should NOT drink alcohol.

VB No prescription dosage changes will be made without an office visit.

VB Only one pharmacy may be used.

VB You agree to comply fully with all aspects of your treatment program including behavioral medicine (psychology/psychiatry) and physical therapy, if recommended. Failure to do so may result in discontinuation of your medication and referral to another provider or treatment center.

VB Successful pain management includes using multiple interventions, including active participation in regular exercise and use of psychological coping strategies. Failure to follow the prescribed treatment plan including medication, therapy, etc., may result in discontinuation of medications and/or referral to another provider or treatment center.

**Side Effects:**

Opioids (narcotics) may cause drowsiness that can be worsened with alcohol, benzodiazepines, and other sedating medications. Use care when driving and operating machinery. An overdose can cause severe side effects, even death.

Other common, usually temporary, side effects include nausea, itching, and sweating. Psychological depression and lowered testosterone levels (in men) may also occur. Sleep apnea, if present, may be worsened by opioids. Constipation commonly occurs, and often does not improve with time. It is impossible to predict opioid side effects in any individual patient. Having side effects on one opioid does not necessarily mean there will be side effects on another opioid.

You must take opioids only as directed. Federal law prohibits giving this medication to anyone else. Physical dependence will develop with regular use, but does not by itself indicate addiction; this means that a withdrawal syndrome will develop if you stop your medication abruptly. Tolerance may develop to the pain relieving effects of opioids; this means that the pain relief may decrease over time, but in chronic pain states this usually occurs slowly, if at all.

Not all pain conditions respond to opioids. Some pain may only be partially responsive to opioid therapy. Total elimination of pain is an unrealistic goal. Increasing dosages may indicate that opioids are not effective or that there is an underlying problem with addiction or psychological dependence. Discontinuation of opioid medications may need to be done under these circumstances: not enough pain relief, persistent side effects, not achieving goals of opioid treatment (such as improvement in function), problematic dosage increases, or inability to comply with the treatment agreement.

I, the undersigned, agree to follow these guidelines that have been fully explained to me. All of my questions and concerns regarding treatment have been adequately answered.

I, the undersigned, give permission to my pain doctor to contact my other healthcare providers, for the purposes of sharing information concerning my situation, as is deemed necessary for coordinated, high quality care.

If I do not follow these guidelines fully, my doctor may stop opioid treatment and refer me elsewhere for care.

A copy of this document has been given to me, if requested.

Patient Signature: VICTOR BENJAMIN Date: 10-2-15

Witness Signature: Lisa Schafer Date: 10-2-15

1106 Chuck Dawley Blvd., Suite 200 ■ Mt. Pleasant, SC 29464

Patient Name: Victor Benjamin  Encounter Date: 12/17/2015  Date of Birth:
Account Number:

Mr. Benjamin is being seen today for a 2 month follow-up appointment. He has surgical history to involve posterior decompression and fusion at the C3-4 level done in 2014. He previously underwent anterior cervical discectomy and fusion at the levels below his fusion through C7 at an outside facility. We also monitor him for low back pain secondary to lumbar spinal stenosis and a posterior disc protrusion at the L4-5 level. He underwent a right-sided L4-5 epidural injection in October. He states he got good pain relief with this injection and continues to benefit from this. His main complaint today is of left-sided neck pain that radiates down his left arm. He states he noticed an increase in his pain this past Sunday. He denies any inciting incident or known trauma. He has been resting which helped some. He continues to ambulate with a cane. He was debating using his hard collar secondary to increased neck pain. He denies loss of bowel or bladder function, any focal muscle deficits, or paralysis.

He continues to be monitored by Dr. Sandoz for pain management. He also sees Dr. Saarb. He has been well-maintained with his medication.

AP and lateral views of his cervical spine were obtained and reviewed with him today. There is appropriate positioning of the instrumentation at C3-4. There is no further shifting or collapse of his previous fusion site.

We discussed generalized precautions and restrictions. He is someone who is totally and permanently disabled from returning to any form of work. I will give him a Medrol Dosepak for acute pain control of his neck. If he were to have no relief from the Medrol Dosepak we could potentially move forward with updated imaging to include an MRI scan of the cervical spine. He understands this. I will give him an order for a soft cervical collar for adjunct pain control to be used intermittently. We will see him back in the office for a routine follow-up in 3 months time for reevaluation and updated imaging. He could potentially undergo a repeat epidural injection for his lumbar spine depending on his symptoms. He'll contact our office with any further issues in the meantime.

**Imaging Orders:**
AP and Lateral views of the cervical spine were ordered, obtained and interpreted from an orthopedic standpoint.
**Diagnosis Codes:**
M54.12 Radiculopathy, cervical region
M47.27 Other spondylosis with radiculopathy, lumbosacral region

**Treatment Plan:** A Medrol Dosepak was prescribed; side effects were discussed and appropriate instructions were provided. Prescription is written for the patient to be fitted with a soft cervical collar today and begin wearing immediately for weak spinal musculature and pain reduction. This should increase the ability to preform activities of daily living while limiting further progression of disc pathology. The patient is instructed to call us if pain persists or get worse. Patient to return in 3 months for follow up.

Lane Tuggle, PA-C

DIGITALLY SIGNED Lane Tuggle, PA-C
1/20/2016

Patient Name: Benjamin, Victor
Account number:
DOB:
Encounter Date: 12/17/2015

DIGITALLY SIGNED Lane Tuggle, PA-C
1/20/2016

Main Campus
1106 Clark Dudley Blvd.
Mt. Pleasant, SC 29466

1111 Clark Dudley Blvd.
Mt. Pleasant, SC 29464

(843) 849-1551
Fax (843) 884-0619
1-800-433-0174

Spinal Surgery
Donald R. Johnson, II, MD
Steven O. Poland, MD
R. Alan Dennis, MD
Richard J. Brisch, MD
Thomas J. Anderson, MD
Daniel R. Burke, PA-C
Justin C. Poole, PA-C
Courtney E. Rook, PA-C
G. Ryan Aycoff, PA-C
Lisa Tingle, PA-C
Amanda Hamilton, PA-C

Conservative Spine Care
Leonard E. Varner, MD
John E. Johnson, MD
G. Robert Richardson III, MD
Kristal W. Lindley, PA-C
Carolyn Hyer, PA-C
Michael Fixson, PA-C

Pain Management
Mark D. Nelmes, MD
W. Ross Richardson, MD
Virginia G. Ekas, PA-C
Kathleen L. Bolanosky, PA-C
Christine Chandler, PA-C

Neuromuscology
Richard C. Baker, MD

Affiliated Physicians

Neurology-Intraoperative
Neuromonitoring
Diego "Tim" Lee, MD

Vascular Spine
Access Surgery
Thomas C. Appleby, MD

Date: 5/27/2015
Re: Victor Benjamin
DOB:
MR#:

Jeffrey C. Chandler, P.C.
Chandler Law Firm
P.O. Drawer 1889
Myrtle Beach, SC 29578-1889

Dear Mr. Chandler:

I first saw Mr. Benjamin at the request of Dr. Sandoz in November of 2012. He had severe spinal stenosis at the C3-4 level after an accident, which rendered him unconscious. He has obvious spinal cord compression and bruising of the spinal cord or myelomalacia, it was recommended that he consider surgical intervention; and he was ultimately sent to Dr. Lozanne where he had surgery at C4-5, C5-6, and C6-7 but did not have surgery at C3-4. He developed progressive spondylosis or disc space collapse at the C3-4 level with worsening of stenosis at the C3-4 level but more importantly continued presence of spinal cord edema or bruising. On his physical examination, he was developing progressive loss of use of his upper extremities with an altered gait and imbalance.

I saw Mr. Benjamin on 1/21/12 with the MRI scan showing the edema within his spinal canal and believed that he should consider surgery, and I felt absolutely that he should not do any type of therapy and that surgery was mandatory. He underwent the operative intervention on what I would describe as an urgent basis in February of 2014 to involve posterior cervical decompression and fusion. Dr. Lozanne saw the patient, and I received records from him noting that he saw myelomalacia or spinal cord edema at the C3-4 level. Dr. Lozanne did state that the spinal cord itself "looked to have been damaged to some degree at the C3-4 level".

I would invite really any neurosurgeon or neuroradiologist to review the MRI scan from January 20, 2014; and I think it would be obvious that there is severe stenosis at the C3-4 level. When comparing the stenosis with spinal cord compression at the C3-4 level on the MRI scan from January 20, 2014 compared to the MRI scan from October 15, 2012, it is clearly worse at the adjacent level after the fusion. I would describe his problem as obviously surgical and obviously

Patient Name: Benjamin, Victor
Account number:
DOB:
Encounter Date: 5/27/2015

urgent, I honestly don't know of anyone who would feel different in terms of worsening cervical stenosis with spinal cord compression and evidence of myelomalacia. Apparently there is some determination by the Workman's Compensation Commission that operative intervention was either not urgent or necessary in 2014. I would respectfully opine that I don't know of a spinal surgeon who would have that opinion.

Suffice it to say this man had a serious or catastrophic neurologic injury. He has signs and symptoms of upper and lower extremity weakness. This type of spinal cord edema or compression is what commonly would be referred to as incomplete quadriparesis or as a form of incomplete quadriplegia. He has a disabling problem that will prevent him from walking normally or using his hands normally for fine motor activities. He is obviously permanently disabled from returning to any type of employment and meets what I would describe as the necessary criteria for pursuing Social Security disability.

With regards to the urgency of the clinical situation for Mr. Benjamin, when you have spinal stenosis of this severity with edema or bruising in the spinal cord, if you don't decompress the stenosis the patient's symptoms will get worse. Again, I would invite this man's imaging studies and clinical records to be reviewed by any other spinal or neurosurgeon and I'm confident that their opinion would match mine with regards to the urgent nature of the surgery and its absolute necessity.

Specifically with regards to impairment, Mr. Benjamin has undergone a multilevel fusion operation. Specific impairment would be due to alteration of motion-segment integrity requiring fusion. This would be per DRE Cervical Category IV. He would have a 28-percent impairment rating.

With regards to impairment in addition from the spinal cord injury as both I and Dr. Lozanne have described, he has additional impairment not only from the fusion but from the myelomalacia or spinal cord compression. He has station and gait disorders and impairment to both his upper and lower extremity. He is limited to level surfaces of walking and has criteria for impairment due to station and gait disorder, and he does not have digital dexterity in his hands as a consequence of the injury. Impairment with regards to whole-person impairment, which is in addition for criteria of impairment for the upper extremities, is per table 15-8, page 396 of the AMA Guides for Permanent Impairment Fifth Edition. This would be an additional 39-percent whole-person impairment rating and is added to the previous impairment. Therefore, his total numerical impairment is 67 percent to the whole person.

Again, this man has a form of spinal cord injury or incomplete quadriplegia, and this is the rationale behind him having this level of disabling impairment and injury. Again, my opinions are held to a reasonable degree of medical certainty. I would be glad to see him back at any time.

Sincerely,

Steven C Poletti MD

SCP/dmp

1106 Chuck Dawley Blvd., Suite 200 ■ Mt. Pleasant, SC 29464

Patient Name: Victor Benjamin  Encounter Date: 10/2/2015  Date of Birth:
Account Number:

CC: Follow up neck and right upper extremity pain, low back and right lower extremity pain.

HPI: Mr. Benjamin presents today, accompanied by his wife, for follow up evaluation. He is someone we continue to follow for complaints of chronic neck pain with radiation into the right upper extremity, as well as low back pain with radiation into his right hip. He has previous surgical history of C4-7 done at an outside facility with posterior fusion of C3-4 done by Dr. Richard Frisch and Dr. Steven Poletti in February, 2014. His is a difficult situation as he reports chronic radiculopathy of the right upper extremity after undergoing an EMG with his pain management physician Dr. Sandoz. He states he is considering a possible cervical rhizotomy and remains stable with regards to his cervical spine. He also has chronic low back pain with radiation into his right buttock and posterolateral hip. He previously underwent a right L4-5 LESI 7/10/2015 and states this helped his pain. He states that his pain in his lower extremity seems to be worsening and he feels subjective weakness when ascending stairs. He denies any focal muscle deficits, paralysis, or changes in bowel and bladder function.

Imaging: AP and lateral lumbar plane films were obtained and reviewed with him today. They show evidence of diffuse lumbar spondylosis with degeneration at the L5-S1 level and facet arthropathy. These are compared with his previous images from 5/15/2014 And appear relatively stable. We have also reviewed cervical plain films which the patient brought with him today. They show appropriate positioning of posterior instrumentation at the C3-4 level. His previous fusion site appear stable.

Physical exam: He is well-developed, well-nourished, 53-year-old male who is alert and oriented ×3 and in no acute distress. He is ambulatory with slightly antalgic gait using the assistance of a cane primarily for fall prevention. Strength of the lower extremity is 5/5 with hip flexion, ankle dorsi flexion and 4/5 with knee flexion, knee extension, plantar flexion bilaterally. Positive straight leg raise on the right, negative on the left. Negative Hoffman's sign. Strength of the upper extremity is intact. Restricted, painful, cervical range of motion.

**Diagnosis Codes:**
M54.12 Radiculopathy, cervical region
M47.27 Other spondylosis with radiculopathy, lumbosacral region

**Treatment Plan:** Greater than 15 minutes of face to face time was spent with Mr. Benjamin and his wife discussing his current pain complaints, updated imaging, and plan of care. Recommendation today is for an updated lumbar MRI scan in order to evaluate his neurologic structures given his persistent and increasing pain. We will also place an order for a right L4-5 years thigh as he has historically done well with this and present with similar symptoms. This is to be completed at his convenience. With regards to cervical spine he does remain stable and he is to continue to follow up with Dr. Sandoz for further pain management. He is to return for follow-up evaluation in 3 months time or on completion of his lumbar MRI scan. He is instructed to contact our office if his symptoms progress or worsen in any way.Lumbar epidural steroid injection was ordered. An MRI of the lumbar spine was ordered. The scan will need to include 3-D reformations to evaluate for any potential extraforaminal herniations as well as anticipation of injection

DIGITALLY SIGNED Anne E. Buck, PA-C
10/2/2015

Patient Name: Benjamin, Victor
Account number:
DOB: /
Encounter Date: 10/2/2015

therapy or surgical intervention. The patient is instructed to call us if pain persists or get worse. Patient to return in 3 months for follow up. The patient is to return when the result of MRI is available.

Anne E. Buck, PA-C

DIGITALLY SIGNED Anne E. Buck, PA-C
10/2/2015

Richard C. Holgate, M.D.

The Southeastern Spine Institute
1106 Chuck Dawley Blvd.
Mount Pleasant, SC 29464
843-849-1551

# FINAL REPORT

**Patient:** Victor Benjamin **Exam Date:** 10/19/2015

**Patient Phone:** – **Exam Name:** Lumbar

**SSN:** **Modality:** MRI

**Patient #:** **Referring Doctor:** Poletti, Steven

**Clinical Information:** M/53 WITH LOW BACK AND RIGHT LEG PAIN FOR FOUR YEARS. NO RECENT TRAUMA. HT-6'0" WT-171 LBS.

**TECHNIQUE:** The patient is examined on the High Field GE Horizon LX High Speed MR System . A phased array coil is used to obtain high resolution images of the lumbar spine. **SERIES:** 1) COR, T1, SE, 7 mm; 2) SAG, Proton, FSE, 3 mm; 3) AX, Oblique, Proton, T2, FSE, 3 mm; 4) AX, T1, SE, 5 mm. 5) AX, Proton, FSE, 4 mm.; **ADDITIONAL SEQUENCES:** 1) MR myelotomography. **3D REFORMATIONS:** 1)COR-OBL,T2FSE/FS, 20mm MIPS. 2) SAG-OBL reformations both right and left.

**OVERVIEW:** Overview of the lumbar spine shows normal bony alignment and normal marrow signal apart from Modic changes with no evidence of a congenital anomaly of the spine. Images of the hips, sacroiliac joints, piriformis muscles and proximal sciatic nerves reveal no abnormality.

**THORACIC SPINE:** Views of the distal thoracic spine show a normal spinal cord and conus medullaris, normal vertebrae and mild noncompressive spondylosis.

**INTERVERTEBRAL DISCS:**
**L1-2, L2-3.** Mild noncompressive spondylosis.

**L3-4.** Mild facet arthropathy, signal loss and a minimal bulge but no sign of root compression.

**L4-5.** Moderate facet arthropathy, signal loss and a diffuse shallow protrusion of disc. There is moderate to severe bilateral lateral recess stenosis (see myelogram).

**L5-S1.** Mild noncompressive spondylosis.

**3D REFORMATIONS AND MYELOTOMOGRAPHY:** MR myelotomography is a 3D sequence which displays the distribution of cerebral spinal fluid within the lumbar subarachnoid space and simulates an x-ray myelogram without spinal injection. Multiple oblique projections were performed and confirm the findings above.

**Opinion:** MRI of the lumbar spine including 3D myelotomographic images and multiplanar reformations shows spondylosis with moderate to severe lateral recess stenosis and potential root compression at L4-5.

**Patient:** Victor Benjamin
**Patient #:**

Exam Name: Lumbar

Exam Date: 10/19/2015

Richard C. Holgate, MD
DISC Radiologists
1341C Old Georgetown Road - Mount Pleasant, SC 29464
(843) 884-8095 - (800) 898-1294 - Fax (843) 856-7312

1106 Chuck Dawley Blvd., Suite 200 ■ Mt. Pleasant, SC 29464

Patient Name: Victor Benjamin  Encounter Date: 12/17/2015  Date of Birth:
Account Numb

Mr. Benjamin is being seen today for a 2 month follow-up appointment. He has surgical history to involve posterior decompression and fusion at the C3-4 level done in 2014. He previously underwent anterior cervical discectomy and fusion at the levels below his fusion through C7 at an outside facility. We also monitor him for low back pain secondary to lumbar spinal stenosis and a posterior disc protrusion at the L4-5 level. He underwent a right-sided L4-5 epidural injection in October. He states he got good pain relief with this injection and continues to benefit from this. His main complaint today is of left-sided neck pain that radiates down his left arm. He states he noticed an increase in his pain this past Sunday. He denies any inciting incident or known trauma. He has been resting which helped some. He continues to ambulate with a cane. He was debating using his hard collar secondary to increased neck pain. He denies loss of bowel or bladder function, any focal muscle deficits, or paralysis.

He continues to be monitored by Dr. Sandoz for pain management. He also sees Dr. Saarb. He has been well-maintained with his medication.

AP and lateral views of his cervical spine were obtained and reviewed with him today. There is appropriate positioning of the instrumentation at C3-4. There is no further shifting or collapse of his previous fusion site.

We discussed generalized precautions and restrictions. He is someone who is totally and permanently disabled from returning to any form of work. I will give him a Medrol Dosepak for acute pain control of his neck. If he were to have no relief from the Medrol Dosepak we could potentially move forward with updated imaging to include an MRI scan of the cervical spine. He understands this. I will give him an order for a soft cervical collar for adjunct pain control to be used intermittently. We will see him back in the office for a routine follow-up in 3 months time for reevaluation and updated imaging. He could potentially undergo a repeat epidural injection for his lumbar spine depending on his symptoms. He'll contact our office with any further issues in the meantime.

**Imaging Orders:**
AP and Lateral views of the cervical spine were ordered, obtained and interpreted from an orthopedic standpoint.
**Diagnosis Codes:**
M54.12 Radiculopathy, cervical region
M47.27 Other spondylosis with radiculopathy, lumbosacral region

**Treatment Plan:** A Medrol Dosepak was prescribed; side effects were discussed and appropriate instructions were provided. Prescription is written for the patient to be fitted with a soft cervical collar today and begin wearing immediately for weak spinal musculature and pain reduction. This should increase the ability to preform activities of daily living while limiting further progression of disc pathology. The patient is instructed to call us if pain persists or get worse. Patient to return in 3 months for follow up.

Lane Tuggle, PA-C

DIGITALLY SIGNED Lane Tuggle, PA-C
1/20/2016

Patient Name: Benjamin, Victor
Account number:
DOB:
Encounter Date: 12/17/2015

DIGITALLY SIGNED Lane Tuggle, PA-C
1/20/2016

GRAND STRAND SPECIALTY ASSOCIATES NEUROLOGY

**Grand Strand Specialty Associates**
PO Box 70899
Myrtle Beach, SC 29572
(843) 449-2338

Providing information about your personal and family medical history is one of the best ways to help your physician learn a great deal about your health in a short period of time. The questions in the Medical History Worksheet are designed to help you remember and communicate important details of your past and current health history. Complete as much of the worksheet as possible, answering as many of the questions as you can.

Name Victor Benjamin Date of Birth

Height 6 ft Weight 185 #'s ☐ Right-handed ☒ Left-handed

Please describe the problem you are experiencing:
Headaches, Neckaches Back + Shoulder Pains on right Side → Right
left Side

How long have you been having this problem? 6-15-11 W/C

How often does this problem occur? Neck, Shoulder + Head all the time

How severe is the problem? ☐ Very severe ☐ Moderately severe ☐ Mild Sometimes more severe than others

Are there things that make this problem worse? Arcoral pain 2 3rd side/30%
Nope Can just wake up and I am in Pains
Shoot down neck & crack

Are there things that make this problem better?
Pain Pills, Medicine etc

What activities can you no longer do because of this problem?
Stand for a long time get dizzy sometimes, Can't hold things in right hand
Can't grip nothing w/ right hand

Do you experience this problem with movement? ☒ Yes ☐ No
and without + still have the pains.

Do you experience this problem at rest? ☒ Yes ☐ No not as bad.

H.A. left side 8/10
Neck back 8/10

## Medical History

Prior Medical Problems (Include any Neurological and/or Orthopaedic related problems):
High blood pressure, high Cholesterol, broken Ankle in 2007, None until this accident, Dr. Nasir in Florence
- Dizzy + unsteady sometimes No fully top of the
- forgetting a lot / unable / mean behavior / [illegible]

Prior Surgical History (List all operations and dates):
Right Arm on 6-17-11 due to the accident - Nichols Med. Center
HR Neck | EEG | EMG 2-4-6 | Neuropsych | - Neuro in Florence - Lumbar

Name: Benjamin Victor Date

Previous Hospitalizations other than Surgery (Include reason for hospitalization and dates):

None

Medications (List all present medications with dosages - include over-the-counter vitamins, Tylenol, etc.):

Privastatin - Cholesterol Medicine 7.1 pOQD
Diovan. - High blood Pressure Med. 120 Mg
Proflavi - Vitamin for Prostate Preventative

Allergic History to Medications (List medication and specific allergy and/or reaction):

N/A NKDA

Family History (List age and medical problems of parents, siblings, and children - if any deaths have occurred in the family please list age and cause of death):

Mother: Throat Cancer - High Blood Pressure
Father: High Blood Pressure, Allergy - Thyroid;
Brother(s): X4 - A&W
Sister(s): X2 - 1 - Leukemia 1 - A&W
Children: X2 - 1 Allergy

Social History

Do you smoke? ☐ Yes ☑ No

How long have you smoked?

Did you ever quit? Never Start ☐ Yes ☐ No For How Long?

Do you drink alcohol? ☐ Yes ☑ No

If yes, indicate the number of drinks (and type) you take in an average week.

(Please include beer and wine)

Do you use other drugs? ☐ Yes ☑ No

Have you ever had a blood transfusion? ☐ Yes ☑ No

Marital Status: ☐ Single ☑ Married (28 years) ☐ Widowed ☐ Divorced ☐ Widowed/Divorced/Remarried

Name: Benjamin Victor Date

Location prior to living in Myrtle Beach area _____

Present Occupation/Past Occupations Disable - Past - Front end Maintainer. Not working

## Review of Body Systems

Do you have a present or past history of any of the following (Please place an appropriate check next to each item):

| General | Present | Past | Never |
|---|---|---|---|
| Fever | ☐ | ☑ | ☐ |
| Chills | ☐ | ☐ | ☐ |
| Sweats | ☐ | ☐ | ☐ |
| Weight change (loss or gain) | ☐ | ☐ | ☐ |
| Weakness | ☐ | ☐ | ☐ |
| Fatigue | ☐ | ☐ | ☐ |
| Swollen Glands | ☐ | ☐ | ☐ |
| Difficulty Sleeping | ☐ | ☐ | ☐ |
| **Dermatologic** | **Present** | **Past** | **Never** |
| New Skin Growths | ☐ | ☐ | ☐ |
| Change in color or size of skin growth | ☐ | ☐ | ☐ |
| Rashes | ☐ | ☐ | ☐ |
| Mouth sores | ☐ | ☐ | ☐ |
| Hair loss | ☐ | ☐ | ☐ |
| Sun sensitivity | ☐ | ☐ | ☐ |
| Fingernail changes | ☐ | ☐ | ☐ |
| **Eyes, Ears, Nose, Throat** | **Present** | **Past** | **Never** |
| Wear eye glasses | ☐ | ☐ | ☐ |
| Eye pain | ☐ | ☐ | ☐ |
| Hearing loss | ☐ | ☐ | ☐ |
| Ringing in ears | ☑ | ☐ | ☐ |
| Ear infections | ☐ | ☐ | ☐ |
| Sinus disorders | ☐ | ☐ | ☐ |
| Post nasal drip | ☐ | ☐ | ☐ |
| Nose bleeds | ☐ | ☐ | ☐ |
| Phlegm in throat | ☐ | ☐ | ☐ |
| Frequent colds or sore throats | ☐ | ☐ | ☐ |
| Hoarseness | ☐ | ☐ | ☐ |
| Difficulty swallowing | ☐ | ☐ | ☐ |
| **Breast** | **Present** | **Past** | **Never** |
| Fibrocystic breast disease | ☐ | ☐ | ☐ |
| **Genitourinary** | **Present** | **Past** | **Never** |
| Blood in urine | ☐ | ☐ | ☐ |
| Pus in urine | ☐ | ☐ | ☐ |
| Painful urination | ☐ | ☐ | ☐ |
| Frequent urination | ☐ | ☐ | ☐ |
| Urgent urination | ☐ | ☐ | ☐ |
| Kidney infection | ☐ | ☐ | ☐ |
| Bladder infection | ☐ | ☐ | ☐ |
| Prostate infection | ☐ | ☐ | ☐ |
| Impotence | ☐ | ☐ | ☐ |
| Genital discharge | ☐ | ☐ | ☐ |

| Pulmonary | Present | Past | Never |
|---|---|---|---|
| Shortness of breath | ☐ | ☐ | ☐ |
| Wheezing | ☐ | ☐ | ☐ |
| Chronic Cough | ☐ | ☐ | ☐ |
| Blood-streaked sputum | ☐ | ☐ | ☐ |
| Bronchitis | ☐ | ☐ | ☐ |
| Pneumonia | ☐ | ☐ | ☐ |
| Asthma | ☐ | ☐ | ☐ |
| Abnormal chest x-ray | ☐ | ☐ | ☐ |
| **Cardiovascular** | **Present** | **Past** | **Never** |
| Chest Pain | ☐ | ☐ | ☐ |
| Chest pain w/ walking/exercise | ☐ | ☐ | ☐ |
| Heart murmur | ☐ | ☐ | ☐ |
| Rheumatic fever | ☐ | ☐ | ☐ |
| Fainting | ☐ | ☐ | ☐ |
| Swelling in ankles | ☐ | ☐ | ☐ |
| Sleep on more than one pillow | ☐ | ☐ | ☐ |
| Calf or leg pain | ☐ | ☐ | ☐ |
| Varicose veins | ☐ | ☐ | ☐ |
| Abnormal electrocardiogram | ☐ | ☐ | ☐ |
| **Gastrointestinal** | **Present** | **Past** | **Never** |
| Nausea | ☐ | ☐ | ☐ |
| Vomiting | ☐ | ☐ | ☐ |
| Indigestion | ☐ | ☐ | ☐ |
| Heartburn | ☐ | ☐ | ☐ |
| Recurring diarrhea | ☐ | ☐ | ☐ |
| Frequent constipation | ☐ | ☐ | ☐ |
| Recent change in bowel habits | ☐ | ☐ | ☐ |
| Blood in bowel movements | ☐ | ☐ | ☐ |
| Black bowel movements | ☐ | ☐ | ☐ |
| Jaundice | ☐ | ☐ | ☐ |
| Hemorrhoids | ☐ | ☐ | ☐ |
| **Rheumatologic** | **Present** | **Past** | **Never** |
| Pain, stiffness or swelling in joints | ☐ | ☐ | ☐ |
| Bursitis | ☐ | ☐ | ☐ |
| Arthritis | ☐ | ☐ | ☐ |
| Low back pain | ☑ | ☐ | ☐ |
| Low back stiffness | ☐ | ☐ | ☐ |
| Numbness or tingling in legs | ☐ | ☐ | ☐ |
| Foot pain | ☐ | ☐ | ☐ |

Name: Benjamin Victor _____ Date _____

| Neurologic | Present | Past | Never |
|---|---|---|---|
| Recurrent headaches | ☒ | ☐ | ☐ |
| Migraine headaches | ☒ | ☐ | ☐ |
| Fainting | ☐ | ☐ | ☐ |
| Dizziness | ☒ | ☐ | ☐ |
| Memory loss | ☒ | ☐ | ☐ |
| Seizures | ☐ | ☐ | ☐ |
| Visual disturbances (blurred/double) | ☐ | ☐ | ☐ |
| Speech difficulty | ☐ | ☐ | ☐ |
| Muscle weakness | ☒ | ☐ | ☐ |
| Muscle paralysis | ☐ | ☐ | ☐ |
| Ringing in ears | ☒ | ☐ | ☐ |
| History of head injury *New* | ☒ | ☐ | ☐ |

| Endocrine | Present | Past | Never |
|---|---|---|---|
| Frequent Urination | ☐ | ☐ | ☐ |
| Urination at night | ☐ | ☐ | ☐ |
| Muscle cramps/weakness | ☐ | ☐ | ☐ |
| Weight change | ☐ | ☐ | ☐ |
| Heat/cold intolerance | ☐ | ☐ | ☐ |
| Tremors | ☐ | ☐ | ☐ |
| Difficulty climbing stairs | ☐ | ☐ | ☐ |
| Difficulty arising from chair | ☐ | ☐ | ☐ |
| Palpitations | ☐ | ☐ | ☐ |
| Hair Loss | ☐ | ☐ | ☐ |
| Excessive hair growth | ☐ | ☐ | ☐ |

Lidia A. Benjamin
Person Completing Form

Spouse
Relationship to Patient

VECTOR BENJAMIN
Signature

9-16-11
Date

**********

☐ Hx. Reviewed with patient - no changes

☐ Hx. Reviewed with patient - see note for changes

Physician Signature

9/16/11
Date

☐ Hx. Reviewed with patient - no changes

☐ Hx. Reviewed with patient - see note for changes

Physician Signature

Date

☐ Hx. Reviewed with patient - no changes

☐ Hx. Reviewed with patient - see note for changes

Physician Signature

Date

Name: Benjamin Victor

Date

GRAND STRAND
SPECIALTY ASSOCIATES
NEUROLOGY

Neurology:
Jeff A. Benjamin, D.O.
Barbara L. Sarb, D.O.
Michael McCaffrey, M.D.

Neurology & Ophthalmology:
George M. Sandoz, M.D.

| | |
|---|---|
| PATIENT: | Victor Benjamin |
| DATE OF BIRTH: | |
| DATE: | 09/16/2011 11:00 AM |
| VISIT TYPE: | Consultation |

**Chief Complaint/Reason for visit:**
This 49 year old male presents with head injury, neck pain and dizziness.

**History of Present Illness**

**1. head injury**
Onset: sudden. The severity of the symptoms is moderate. The symptoms have not changed. Ventilator support was not used in the hospital. The location of the injury is in the left parietal region. The location of pain is facial, head and neck. The mechanical force causing the injury was coup. Context includes metal guard hit head. The patient does not use alcohol. There are no risk factors. Aggravating factors include exertion, lying down, sound and touch. Denies relieving factors. Associated symptoms include confusion, headache, incoordination, irritability, loss of consciousness, memory difficulty, personality change, restlessness, speech difficulty, stiff neck, unusual behavior, visual disturbance and weakness. Additional information: event on 6-15-11, was control panel, amnestic for event and skull fracture left.

**2. neck pain**
Onset: sudden. The severity of the problem is moderate. The problem has worsened. The frequency of pain is daily. Location of pain is bilateral posterior neck. There was radiation of pain to the left upper arm, left elbow and left forearm. The patient describes the pain as aching and burning. The event(s) surrounding the occurrence of the symptom include 30 lbs metal guard hit head. Trauma occurred on 06/15/2011. Aggravating factors include climbing stairs, flexion, hyperextension, kneeling, lifting, lying down, walking and working. Denies relieving factors. Associated symptoms include difficulty sleeping, disequilibrium, muscle spasm, numbness, other joint pain, tenderness and tingling. Pertinent negatives include bladder retention.

**3. dizziness**
Onset was sudden. Severity is moderate. The duration of each episode is Month(s). The problem is unchanged. It occurs persistently. The patient describes it as (an) imbalance and spinning. It occurs while. The patient has sustained a head injury in the past. Symptom is aggravated by rapid rise and turning. Relieving factors include position change. Associated symptoms include hearing loss, loss of consciousness, neck stiffness, paresthesias and tinnitus. Pertinent negatives include diplopia or ear ache.

**Vital Signs**

**Height**

| Time | Ft | In | Cm | Last Measured | Method | % |
|---|---|---|---|---|---|---|
| 12:07 PM | 6.0 | | | | | |

**Weight / BSA / BMI**

| Time | Lb | Oz | Kg | Context | % | BMI | BSA |
|---|---|---|---|---|---|---|---|
| 12:07 PM | 184.00 | | | | | 24.95 | |

**Blood Pressure**

| Time | BP | Position | Side | Site | Method | Cuff Size |
|---|---|---|---|---|---|---|
| 12:07 PM | 140/78 | sitting | | | | |

Benjamin, Victor

Measured By
Time
12:07 PMPenny Powers

Physical Exam
Constitutional:
Level of distress is moderate distress. Well nourished. Well developed.
Eyes:
Right
Fundus is benign.
Left
Fundus is benign.
Ears:
Right
Normal tympanic membrane.
Left
Normal tympanic membrane.
Vascular:
Bruits
Carotid bruits: absent.
Musculoskeletal:
Cervical spine has muscle spasm, moderately reduced ROM
Lumbar spine has muscle spasm
Neurological:
Level of Consciousness: Normal.
Orientation: Alert and oriented X 3. Grossly normal intellect. .
Memory: Intact. .
Cranial nerves: II-XII grossly intact. .
Trigeminal:
Motor and Reflexes: normal.
Facial: normal.
Acoustic: Weber test abnormal; lateralizes to the right
Glossopharyngeal: normal.
Vagus: normal.
Spinal Accessory: normal.
Hypoglossal: normal.
Sensory: No sensory loss. .
Motor: No motor weakness. .
Balance & Gait: Balance and gait intact. .
Coordination: Coordination intact. .
Fine Motor: Skills normal. .
Biceps deep tendon reflex is 2+ on the right and 1+ on the left,
Brachioradialis deep tendon reflex is 2+ bilaterally.
Triceps deep tendon reflex is 2+ bilaterally.
Patellar reflex is 2+ bilaterally.
Achilles reflex is 2+ bilaterally.
Brudzinski's sign: Negative.

Clinical Assessment
The patient is a 49-year old male who presents with head injury, neck pain and dizziness. Having some difficulty with ambulation. Needs some assistance with ADLs.

Assessment/ Plan
Intracranial injury of other and unspecified natur (854.01)
From traumatic injury will check mri brain perform neuropsych testing and trial with Lamictal for moodstabilazer.
Memory loss (780.93)
Due to injury or ptsd, eeg will be perform.
Dizziness (780.4)
Due to injury causing damage on innerr ear, will give meclizine and exercisses, will check nystagmogram.
Headache (784.0)

Benjamin, Victor

Post trauma in nature, trial with Nucynta.
Pain-neck (723.1)
Due to trauma, ncs and mri cervical spine as well for pt, pain control with nucynta.
Pain-limb (729.5)
Due to trauma, consult with orthopedic surgeons.

**Office Services**

| Status | Order | Reason | Interpretation | Value |
|---|---|---|---|---|
| completed | Adequate nutritional intake | | | |
| completed | Patient agrees with treatment plan & instructions | | | |

**Instructions / Education**

| Status | Completed | Order | Reason |
|---|---|---|---|
| completed | 09/21/2011 | Risks/ benefits of treatment plan | |
| completed | 09/21/2011 | Reviewed medications | |
| completed | 09/21/2011 | Activity as tolerated | |
| completed | 09/21/2011 | Take new medication as prescribed | |

**To be scheduled/ordered**

| Status | Order | Reason | Assessment | Timeframe | Appointment | |
|---|---|---|---|---|---|---|
| scheduled | Office visit | Continue current treatment | | 854.01 | -today | 09/21/2011 |
| ordered | MRI C- SPINE W/O DYE | | 854.01 | | 09/21/2011 | |
| ordered | MRI BRAIN W/O & W/DYE | | 854.01 | | 09/21/2011 | |
| ordered | AUDITOR EVOKE POTENT, COMPRE | | | 780.4 | 09/21/2011 | |
| ordered | SPONTANEOUS NYSTAGMUS TEST | | | 780.4 | 09/21/2011 | |
| completed | Follow-up if symptoms persist / worsen | | | 854.01 | 09/21/2011 | |
| completed | Follow-up for increased symptoms | | 854.01 | -today | 09/21/2011 | |
| ordered | EEG MONITORING/COMPUTER 24hr | | | 780.93 | 09/21/2011 | |
| ordered | MUSCLE TEST, ONE LIMB | | 854.01 | | 09/21/2011 | |
| scheduled | Office visit | Discuss test results | | 854.01 | -today | 09/21/2011 |
| scheduled | Office Visit | Follow-up on medication | | 854.01 | -today | 09/21/2011 |
| completed | Follow-up for medication side effect | | 854.01 | -today | 09/21/2011 | |

George M. Sandoz MD

Document generated by: George Sandoz 09/21/2011

Grand Strand Specialty Associates
8170 Rourk Street, Myrtle Beach, SC 29572

Benjamin, Victor

GRAND STRAND
SPECIALTY ASSOCIATES

Orthopedic Surgery/Traumatology
Christopher Bertken, DO

Neurosurgery
Thomas Andersen, MD
Eugene Giddens, MD

Neurology
Jeff Baydoun, DO
Barbara Sirk, DO
Michael McCallroy, MD

Neurology & Ophthalmology
George Sanchez, MD

| | |
|---|---|
| PATIENT: | Victor Benjamin |
| DATE OF BIRTH: | |
| DATE: | 02/02/2012 8:30 AM |
| VISIT TYPE: | Office Visit |
| HISTORIAN: | self |

**Chief Complaint/Reason for visit:**
This 49 year old male presents with dizziness and loss of consciousness.

**History of Present Illness**
1. dizziness
Onset was sudden. Severity is severe. The duration of each episode is Month(s). The problem is worsening. The patient describes it as (an) imbalance, severe and spinning. It occurs while. The patient has sustained a head injury in the past. Symptom is aggravated by turning. Relieving factors include position change. Associated symptoms include hearing loss, loss of consciousness, headache, neck stiffness, palpitations and tinnitus. Pertinent negatives include chest pain.
2. loss of consciousness
Onset: sudden. Severity: moderate. Duration: Minute(s). The problem is worse. The patient describes it as jerking movements. It occurred due to motor vehicle accident. Associated symptoms include vertigo. Pertinent negatives include bladder incontinence.

**Vital Signs**
Height

| Time | Ft | In | Cm | Last Measured | Method | % |
|---|---|---|---|---|---|---|
| 9:17 AM | | | | 09/16/2011 | | |

Weight / BSA / BMI

| Time | Lb | Oz | Kg | Context | % | BMI | BSA |
|---|---|---|---|---|---|---|---|
| 9:17 AM | 187.00 | | | | | | |

Blood Pressure

| Time | BP | Position | Side | Site | Method | Cuff Size |
|---|---|---|---|---|---|---|
| 9:17 AM | 138/90 | sitting | | | | |

Temp / Pulse / Respiration

| Time | Temp F | Temp C | Temp Site | Pulse | Pattern | Resp |
|---|---|---|---|---|---|---|
| 9:17 AM | | | | 60 | | |

Measured By

| Time | |
|---|---|
| 9:17 AM | Katie Whitaker |

Benjamin, Victor

Physical Exam
Constitutional:
Level of distress is moderate distress. Well nourished. Well developed.
Musculoskeletal:
Cervical spine has muscle spasm
No lumber spine tenderness. Normal mobility and curvature.
Neurological:
Level of Consciousness: Normal.
Orientation: Alert and oriented X 3. Grossly normal intellect.
Memory: Intact.
Cranial nerves: II-XII grossly intact.
Sensory: No sensory loss.
Motor: No motor weakness.
Balance & Gait: Balance and gait intact.
Coordination: Coordination intact.
Fine Motor: Skills normal.
Deep Tendon Reflexes: symmetrically increased.

Clinical Assessment
The patient is a 49-year bld male who presents with dizziness and loss of consciousness. The patient is compliant with medication. Responding to current treatment. Having some difficulty with ambulation. Needs some assistance with ADLs.

Assessment/ Plan
Other and unspecified disc disorder of cervical re (722.91)
stressed need to take meds/est to control his symptoms, stop tramadol due to n&v, trial with vicodin q 6 hrs and see response.
Dizziness and giddiness (780.4)
Etiology unclear, due to ptsd or cardiac in nature, trial with klonopin 1 mg qhs.
Alteration of consciousness, other (780.09)
Possible due to seizure, will check eeg and see if any paroxismal event.

Office Services

| Status | Order | Reason | Interpretation | Value |
|---|---|---|---|---|
| completed | Adequate nutritional intake | | | |
| completed | Patient agrees with treatment plan & instructions | | | |

Instructions / Education

| Status | Completed | Order | Reason |
|---|---|---|---|
| completed | 02/02/2012 | Risks/ benefits of treatment plan | |
| completed | 02/02/2012 | Continue current medication | |

To be scheduled/ordered

| Status | Order | Reason | Assessment | Timeframe | Appointment | |
|---|---|---|---|---|---|---|
| ordered | EEG MONITORING/COMPUTER 24hr | | | 780.09 | 02/02/2012 | |
| completed | Follow-up for medication side effect | | 722.91 | today | 02/02/2012 | |
| scheduled | Office Visit | Follow-up on medication | | 722.91 | today | 02/02/2012 |
| completed | Follow-up for increased symptoms | | 722.91 | today | 02/02/2012 | |
| scheduled | Office visit | Continue current treatment | | 722.91 | today | 02/02/2012 |
| scheduled | Office visit | Discuss test results | | 722.91 | today | 02/02/2012 |
| completed | Follow-up if symptoms persist / worsen | | | 722.91 | 02/02/2012 | |

George M. Sandoz MD

Document generated by: George Sandoz 02/02/2012

Benjamin, Victor

GRAND STRAND
SPECIALTY ASSOCIATES

Orthopedic Surgery/Traumatology:
Christopher Boulton, DO

Neurosurgery:
Thomas Anderson, MD
Eugene Oskiderts, MD

Neurology:
Jeff Benjamin, DO
Barbara Sarb, DO
Michael Mccoffrey, MD

Neurology & Ophthalmology:
George Sandoz, MD

| | |
|---|---|
| PATIENT: | Victor Benjamin |
| DATE OF BIRTH: | |
| DATE: | 02/21/2012 3:30 PM |
| VISIT TYPE: | Office Visit |

**Chief Complaint/Reason for visit:**
This 49 year old male presents with loss of consciousness.

**History of Present Illness**
**1. loss of consciousness**
Onset: sudden. Severity: moderate. Duration: 1-4 minutes. The problem is unchanged. The patient describes it as staring. It occurred due to head trauma. Associated symptoms include neurological symptoms and performance changes. Pertinent negatives include bladder incontinence. Additional information: ED.

**Vital Signs**

**Physical Exam**
**Constitutional:**
No acute distress. Well nourished. Well developed.
**Musculoskeletal:**
No cervical spine tenderness. Normal mobility and curvature.
No lumbar spine tenderness. Normal mobility and curvature.
**Neurological:**
Level of Consciousness: Normal.
Orientation: Alert and oriented X 3. Grossly normal intellect.
Memory: Intact.
Cranial nerves: II-XII grossly intact.
Sensory: No sensory loss.
Motor: No motor weakness.
Balance & Gait: Balance and gait intact.
Coordination: Coordination intact.
Fine Motor: Skills normal.
Deep Tendon Reflexes: DTR's preserved and symmetric.

**Clinical Assessment**
The patient is a 49-year old male who presents with loss of consciousness. The patient is compliant with medication. Not responding to current treatment.

**Assessment/ Plan**
**Epilepsy, unspecified (345.90)**
Noted on EEG trial withKeppra 500 mg bid, directly relatexd to tbi, ED still present last visit agreed upon intake of

GRAND STRAND
SPECIALTY ASSOCIATES

Orthopedic Surgery/ Traumatology:
Christopher Boulton, DO

Neurosurgery:
Thomas Anderson, MD
Eugene Giddens, MD

Neurology:
Jeff Benjamin, DO
Barbara Sarb, DO
Michael Mccuffrey, MD

Neurology & Ophthalmology:
George Sandez, MD

| | |
|---|---|
| PATIENT: | Victor Benjamin |
| DATE OF BIRTH: | |
| DATE: | 04/25/2012 11:45 AM |
| VISIT TYPE: | Office Visit |

**Chief Complaint/Reason for visit:**
This 50 year old male presents with seizure, follow up, headache and neck pain.

**History of Present Illness**
1. seizure, follow up
Date of last seizure was 02/2012. Date of last EEG was 02/22/2012. The type of seizure is Focal with secondary generalization. The context of the seizure includes TBI. Medication(s) used lacosamide with good results; he is compliant with medication; there are no side effects of medication. Symptom is aggravated by and lack of sleep. Associated symptoms include altered level of consciousness and staring. Additional information: He is not driving.
2. headache
Onset: sudden. Severity: moderate. It occurs daily, has Month(s) duration, and is worse. Location was entire head. The patient describes it as sharp and throbbing. Timing of headache: daytime. Symptom is aggravated by bright lights and noise. Relieving factors include prescription drugs. Associated symptoms include LOC and neurological symptoms. Pertinent negatives include dizziness.
3. neck pain
Onset: sudden. The severity of the problem is moderate. The problem has improved. The frequency of pain is intermittent. Location of pain is bilateral posterior neck. There was radiation of pain to the bilateral upper arm. The patient describes the pain as aching and burning. The event(s) surrounding the occurrence of the symptom include motor vehicle accident. Relieving factors tried include injection and narcotic analgesics. Associated symptoms include difficulty sleeping and muscle spasm. Pertinent negatives include bladder retention. Additional information: ed.

**Active Medications (started before visit)**

| Drug Name | Dose | Qty | Description |
|---|---|---|---|
| Vimpat every day | 100 Mg | 60 | take 1 tablet (100MG) by oral route 2 times |
| Vimpat every day | 50 Mg | 60 | take 1 tablet (50MG) by oral route 2 times |

**Vital Signs**

**Physical Exam**
**Constitutional:**
Level of distress is mild distress. Well nourished. Well developed.
**Musculoskeletal:**
Cervical spine has muscle spasm
No lumbar spine tenderness. Normal mobility and curvature.

Neurological:
Level of Consciousness: Normal.
Orientation: Alert and oriented X 3. Grossly normal intellect. .
Memory: Intact. .
Cranial nerves: II-XII grossly intact. .
Sensory: No sensory loss. .
Motor: No motor weakness. .
Balance & Gait: Balance and gait intact. .
Coordination: Coordination intact. .
Fine Motor: Skills normal. .
Deep Tendon Reflexes: DTR's preserved and symmetric. .
Comments: +tinnels

Clinical Assessment
The patient is a 50-year old male who presents with seizure, follow up, headache and neck pain. The patient is compliant with medication. Responding to current treatment. Needs some assistance with ADLs.

Assessment/ Plan
Epilepsy, unspecified, without mention of intracta (345.90)
Other and unspecified disc disorder of cervical re (722.91)
Intracranial injury of other and unspecified natur (854.01)
Migraine, variants (346.20)
Carpal tunnel syndrome (354.0)
Continue with Vimpat 100 mg bid, tolerating esl well, doing well with current management, treatment with botox for migraine is indicated, awaiting input by Dr Welsch for cts. Discussed with CNM.

George M. Sandoz MD

Document generated by: George Sandoz 04/25/2012

CC Providers:
Leonard Goldschmidt
4882 Socastee Blvd
Myrtle Beach, SC 29588

Grand Strand Specialty Associates
8170 Rourk Street, Myrtle Beach, SC 29572

Benjamin, Victor

# Grand Strand Regional Medical Center

## Spine & Neuro Center

PATIENT: Victor Benjamin
DATE OF BIRTH: 06/07/2012 8:15 AM
DATE:
VISIT TYPE: Office Visit

**Chief Complaint/Reason for visit:**
This 50 year old male presents with seizure, follow up and headache.

**History of Present Illness**
1. seizure, follow up
Date of last seizure was 02/19/2012. Date of last EEG was 02/22/2012. The type of seizure is Focal with secondary generalization. The context of the seizure includes TBI. Medication(s) used Levetiracetam with good results. Symptom is aggravated by and lack of sleep. Associated symptoms include automatic behaviors and unresponsiveness. Additional information: He is not driving.
2. headache
Onset: sudden. Severity: moderate. It occurs daily, has Month(s) duration, and is unchanged. Location was occipital. There was radiation to anterior. The patient describes it as blinding and throbbing. Timing of headache: daytime. It occurred due to recent head trauma. Symptom is aggravated by bright lights, head position and noise. Relieving factors include prescription drugs. Associated symptoms include neurological symptoms and stiff neck.

**Active Medications (started before visit)**

| Drug Name | Dose | Qty | Description |
|---|---|---|---|
| Ultracet as needed, for up to 5 days; do not exceed 8 tablets in 24hrs | 37.5-325mg | 60 | take 2 tablet by oral route every 4 - 6 hours |
| Floricet needed not to exceed 6 tablets per 24hrs | 50-325-40 | 60 | take 1 tablet by oral route every 4 hours as |
| Vimpat every day | 100 Mg | 60 | take 1 tablet (100MG) by oral route 2 times |
| Vimpat every day | 50 Mg | 60 | take 1 tablet (50MG) by oral route 2 times |

**Vital Signs**

**Physical Exam**
**Constitutional:**
Level of distress is moderate distress. Well nourished. Well developed.
**Musculoskeletal:**
No cervical spine tenderness. Normal mobility and curvature.
No lumbar spine tenderness. Normal mobility and curvature.
**Neurological:**
Level of Consciousness: Normal.
Orientation: Alert and oriented X 3. Grossly normal intellect. .
Memory: Intact. .
Cranial nerves: II-XII grossly intact. .
Sensory: No sensory loss. .
Motor: No motor weakness. .
Balance & Gait: Balance and gait intact. .

Coordination: Coordination intact. .
Fine Motor: Skills normal. .
Deep Tendon Reflexes: symmetrically increased.

**Clinical Assessment**
The patient is a 50-year old male who presents with seizure, follow up and headache. The patient is compliant with medication. Responding to current treatment. Having some difficulty with ambulation. Needs some assistance with ADLs.

**Assessment/ Plan**
CH MGR WO ARA W NT WO ST (346.71)
Doing better after botox, will continue with meds.
Epilepsy, unspecified, without mention of intracta (345.90)
Tolerating meds, issue with concentration and performing complex task, continue with keppra, ED treated with meds, cpm.

**Office Services**

| Status | Order | Reason | Interpretation | Value |
|---|---|---|---|---|
| completed | Adequate nutritional intake | | | |
| completed | Patient agrees with treatment plan & instructions | | | |

**Instructions / Education**

| Status | Completed | Order | Reason |
|---|---|---|---|
| completed | 06/19/2012 | Reviewed medications | |
| completed | 06/19/2012 | Avoid driving | |
| completed | 06/19/2012 | Continue current medication | |
| completed | 06/19/2012 | Avoid high risk activity due to seizures/LOC | |
| completed | 06/19/2012 | Risks of declining treatment | |
| completed | 06/19/2012 | Activity as tolerated | |

**To be scheduled/ordered**

| Status | Order | Reason | Assessment | Timeframe | Appointment | |
|---|---|---|---|---|---|---|
| scheduled | Office visit | Continue current treatment | 346.71 | -today | 06/19/2012 | |
| completed | Follow-up for medication side effect | | 346.71 | -today | 06/19/2012 | |
| completed | Follow-up if symptoms persist / worsen | | | 346.71 | 06/19/2012 | |
| scheduled | Office Visit | Follow-up on medication | | 346.71 | -today | 06/19/2012 |
| completed | Follow-up for increased symptoms | | 346.71 | -today | 06/19/2012 | |

George M. Sandoz MD

Document generated by: George Sandoz 06/19/2012

Grand Strand Spine & Neuro
8170 Rourk Street, Myrtle Beach, SC 29572
Phone: (843) 449-2336
Fax: (843) 497-2505

Benjamin, Victor

# Grand Strand
## Regional Medical Center
## Spine & Neuro Center

PATIENT: Victor Benjamin
DATE OF BIRTH:
DATE: 06/20/2012 11:45 AM
VISIT TYPE: Office Visit

**Chief Complaint/Reason for visit:**
This 50 year old male presents with head injury.

**History of Present Illness**
**1. head injury**
Onset: sudden. The symptoms have not changed. The location of pain is head. The mechanical force causing the injury was coup. The patient does not use alcohol. The patient does not use drugs. Aggravating factors include exertion, light and touch. Associated symptoms include clumsiness, headache, irritability, memory difficulty, restlessness, seizure, stiff neck, vomiting and dizziness.

**Active Medications (started before visit)**

| Drug Name | Dose | Qty | Description |
|---|---|---|---|
| Ultracet | 37.5-325mg | 60 | take 2 tablet by oral route every 4 - 6 hours as needed, for up to 5 days; do not exceed 8 tablets in 24hrs |
| Floricet | 50-325-40 | 50 | take 1 tablet by oral route every 4 hours as needed not to exceed 6 tablets per 24hrs |
| Vimpat | 100 Mg | 60 | take 1 tablet (100MG) by oral route 2 times every day |
| Vimpat | 50 Mg | 60 | take 1 tablet (50MG) by oral route 2 times every day |

**Vital Signs**

**Physical Exam**
**Constitutional:**
Level of distress is moderate distress. Well nourished. Well developed.
**Vascular:**
Bruits
Carotid bruits: absent.
**Musculoskeletal:**
Cervical spine has muscle spasm
No lumbar spine tenderness. Normal mobility and curvature.
**Neurological:**
Level of Consciousness: Normal.
Orientation: Alert and oriented X 3. Grossly normal intellect. .
Memory: Intact. .
Cranial nerves: II-XII grossly intact. .
Trigeminal:
Motor and Reflexes: normal.
Facial: normal.
Acoustic: Weber test abnormal, lateralizes to the left
Glossopharyngeal: normal.

Benjamin, Victor

Vagus: normal.
Sensory: No sensory loss. .
Motor: No motor weakness. .
Balance & Gait: Balance and gait intact. .
Coordination: Coordination intact. .
Fine Motor: Skills normal. .
Deep Tendon Reflexes: DTR's preserved and symmetric. .
Brudzinski's sign: Negative.

**Clinical Assessment**
The patient is a 60-year old male who presents with head injury. The patient is compliant with medication. Responding to current treatment. Needs some assistance with ADLs.

**Assessment/ Plan**
Late effect of intracranial injury without mention (907.0)
Continue with current management of migraine, dizziness, neck pain, ED, directly associated with mva.

Epilepsy, unspecified, without mention of intracta (345.90)
Six months since last event and remains seizure free, will restore his driving privilges as today, stressed compliance and continue with Keppra 500 mg bid.

**Office Services**

| Status | Order | Reason | Interpretation | Value |
|---|---|---|---|---|
| completed | Adequate nutritional intake | | | |
| completed | Patient agrees with treatment plan & instructions | | | |

**Instructions / Education**

| Status | Completed | Order | Reason |
|---|---|---|---|
| completed | 06/22/2012 | Risks/ benefits of treatment plan | |
| completed | 06/22/2012 | Reviewed medications | |
| completed | 06/22/2012 | Activity as tolerated | |
| completed | 06/22/2012 | Continue current medication | |

**To be scheduled/ordered**

| Status | Order | Reason | Assessment | Timeframe | Appointment | |
|---|---|---|---|---|---|---|
| completed | Follow-up if symptoms persist / worsen | | | 907.0 | 06/22/2012 | |
| scheduled | Office Visit | Follow-up on medication | | 907.0 | -today | 06/22/2012 |
| scheduled | Office visit | Continue current treatment | | 907.0 | -today | 06/22/2012 |
| completed | Follow-up for medication side effect | | 907.0 | -today | 06/22/2012 | |
| completed | Follow-up for increased symptoms | | 907.0 | -today | 06/22/2012 | |

George M. Sandoz MD

Document generated by: George Sandoz 06/22/2012

CC Providers:
Leonard Goldschmidt
4882 Socastee Blvd
Myrtle Beach, SC 29588

Grand Strand Spine & Neuro
8170 Rourk Street, Myrtle Beach, SC 29572
Phone: (843) 449-2336
Fax: (843) 497-2505

Benjamin, Victor

# Grand Strand
## Regional Medical Center
## Spine & Neuro Center

| | |
|---|---|
| PATIENT: | Victor Benjamin |
| DATE OF BIRTH: | |
| DATE: | 08/16/2012 10:00 AM |
| VISIT TYPE: | Office Visit |

**Chief Complaint/Reason for visit:**
This 50 year old male presents with neck pain and head injury.

**History of Present Illness**
**1. neck pain**
Onset: sudden. The problem is severe. Duration: Month(s). The problem has resolved. The frequency of pain is weekly. Location of pain is bilateral posterior neck. There was radiation of pain to the bilateral upper arm. The patient describes the pain as aching and burning. The event(s) surrounding the occurrence of the symptom include injury. Aggravating factors include standing, Valsalva and working. Relieving factors tried include narcotic analgesics. Associated symptoms include difficulty sleeping, disequilibrium, muscle spasm, sexual dysfunction and weakness. Pertinent negatives include bladder retention. Additional information: during week end unable to move his neck.
**2. head injury**
Onset: sudden. The severity of the symptoms is moderate. The symptoms have not changed. The location of the injury is in the bilateral parietal region. The location of pain is head and neck. The mechanical force causing the injury was coup. Context includes metal cover hit his head. The patient does not use alcohol. The patient does not use drugs. Aggravating factors include exertion and sound. Relieving factors tried include narcotic analgesics. Associated symptoms include headache, memory difficulty, nausea, stiff neck and weakness. Additional information: mood down, no seizure and no relief with botox for headache.

**Active Medications (started before visit)**

| Drug Name | Dose | Qty | Description |
|---|---|---|---|
| Ultracet | 37.5-325mg | 60 | take 2 tablet by oral route every 4 - 6 hours as needed, for up to 5 days; do not exceed 8 tablets in 24hrs |
| Floricet | 50-325-40 | 60 | take 1 tablet by oral route every 4 hours as needed not to exceed 6 tablets per 24hrs |
| Vimpat | 100 Mg | 60 | take 1 tablet (100MG) by oral route 2 times every day |
| Vimpat | 50 Mg | 60 | take 1 tablet (50MG) by oral route 2 times every day |

**Vital Signs**

**Physical Exam**
**Constitutional:**
No acute distress. Well nourished. Well developed.
**Musculoskeletal:**
Cervical spine has muscle spasm
Lumbar spine has muscle spasm
**Neurological:**
Level of Consciousness: Normal.
Orientation: Alert and oriented X 3. Grossly normal intellect.

Intact. .
Cranial nerves: II-XII grossly intact. .
Acoustic: Weber test abnormal, lateralizes to the left
Sensory: No sensory loss. .
Motor: No motor weakness. .
Balance & Gait: Balance and gait intact. .
Coordination: Coordination intact. .
Fine Motor: Skills normal. .
Deep Tendon Reflexes: symmetrically increased.
Comments: +tinnet's

**Clinical Assessment**
The patient is a 50-year old male who presents with neck pain and head injury.

**Assessment/ Plan**
**Late effect of intracranial injury without mention** (907.0)
CPM, will set for ENT eval for tinnitus. Tial with cymbalta 60 mg daily.
**Epilepsy, unspecified, without mention of intracta** (345.90)
Controled with Vimpat 100 mg bid.
**Other and unspecified disc disorder of cervical re** (722.91)
For PT and awaiting result of esi.

**Office Services**

| Status | Order | Reason | Interpretation | Value |
|---|---|---|---|---|
| completed | Adequate nutritional intake | | | |
| completed | Patient agrees with treatment plan & instructions | | | |

**Instructions / Education**

| Status | Completed | Order | Reason |
|---|---|---|---|
| completed | 08/16/2012 | Take new medication as prescribed | |
| completed | 08/16/2012 | Reviewed medications | |
| completed | 08/16/2012 | Risks/ benefits of treatment plan | |
| completed | 08/16/2012 | Activity as tolerated | |
| completed | 08/16/2012 | Continue current medication | |

**To be scheduled/ordered**

| Status | Order | Reason | Assessment | Timeframe | Appointment | |
|---|---|---|---|---|---|---|
| completed | Follow-up for medication side effect | | 907.0 | -today | 08/16/2012 | |
| scheduled | Office visit | Continue current treatment | | 907.0 | -today | 08/16/2012 |
| scheduled | Office Visit | Follow-up on medication | | 907.0 | -today | 08/16/2012 |
| completed | Follow-up if symptoms persist / worsen | | | 907.0 | 08/16/2012 | |
| completed | Follow-up for increased symptoms | | 907.0 | -today | 08/16/2012 | |

George M. Sandoz MD

**Document generated by: George Sandoz 08/16/2012**

**Grand Strand Spine & Neuro**
8170 Rourk Street, Myrtle Beach, SC 29572
Phone: (843) 449-2336
Fax: (843) 497-2505

# Grand Strand
## Regional Medical Center
## Spine & Neuro Center

| | |
|---|---|
| PATIENT: | Victor Benjamin |
| DATE OF BIRTH: | |
| DATE: | 10/23/2012 8:00 AM |
| VISIT TYPE: | Office Visit |

**Chief Complaint/Reason for visit:**
This 50 year old male presents with neck pain.

**History of Present Illness**
1. neck pain
Onset: sudden. The problem is severe. The problem has worsened. The frequency of pain is daily. Location of pain is bilateral posterior neck. There was radiation of pain to the bilateral upper arm. The patient describes the pain as aching and throbbing. The event(s) surrounding the occurrence of the symptom include motor vehicle accident. Aggravating factors include Valsalva and working. Relieving factors tried include narcotic analgesics. Associated symptoms include difficulty sleeping, muscle spasm, numbness and tenderness. Pertinent negatives include bladder retention.

**Social History**
Reviewed, no changes. Last detailed document date: 09/28/2012.

**Active Medications (started before visit)**

| Drug Name | Dose | Qty | Description |
|---|---|---|---|
| Ultracet | 37.5 Mg-325 Mg | 60 | take 2 tablet by oral route every 4 - 6 hours as needed, for up to 5 days; do not exceed 8 tablets in 24hrs |
| Florical | 50 Mg-325 Mg-40 Mg | 60 | take 1 tablet by oral route every 4 hours as needed not to exceed 6 tablets per 24hrs |
| Vimpat | 100 Mg | 60 | take 1 tablet (100MG) by oral route 2 times every day |
| Vimpat | 50 Mg | 60 | take 1 tablet (50MG) by oral route 2 times every day |

**Allergies**
New allergies added during this encounter. Active list below.

| Allergen/Ingredient | Brand | Reaction: |
|---|---|---|
| Meperidine Hcl | | |

**Vital Signs**
Height

| Time | ft | in | cm | Last Measured | Method | % |
|---|---|---|---|---|---|---|
| 9:23 AM | 6.0 | | | 09/18/2011 | | |

Weight / BSA / BMI

Benjamin, Victor

| Time | lb | oz | kg | Context | % | BMI kg/m2 | BSA m2 |
|---|---|---|---|---|---|---|---|
| 9:23 AM | 188.00 | | | | | 25.49 | |

Blood Pressure

| Time | BP mmHg | Position | Side | Site | Method | Cuff Size |
|---|---|---|---|---|---|---|
| 9:23 AM | 140/78 | sitting | | | | |

Measured By

| Time | |
|---|---|
| 9:23 AM | Penny Powers |

{sub_vs_condense: NOT FOUND}

Physical Exam
Constitutional:
Level of distress is moderate distress. Well nourished. Well developed.
Musculoskeletal:
Cervical spine has muscle spasm, moderate pain w/motion
Lumbar spine has muscle spasm
Neurological:
Level of Consciousness: Normal.
Orientation: Alert and oriented X 3. Grossly normal intellect. .
Memory: Intact. .
Cranial nerves: II-XII grossly intact. .
Optic Nerve: Optic normal.
Trigeminal:
Motor and Reflexes: normal.
Facial: normal.
Acoustic: Weber test abnormal, lateralizes to the left
Glossopharyngeal: normal.
Vagus: normal.
Sensory: No sensory loss. .
Motor: No motor weakness. .
Balance & Gait: Balance and gait intact. .
Coordination: Coordination intact. .
Fine Motor: Skills normal. .
Deep Tendon Reflexes: DTR's preserved and symmetric. .

Clinical Assessment
The patient is a 50-year old male who presents with neck pain. The patient is compliant with medication. Responding to current treatment. Having some difficulty with ambulation. Needs some assistance with ADLs.

Assessment/ Plan
Other and unspecified disc disorder of cervical re (722.91)
Worsen since last visit, due to changes from work related injury, will need surgery, continue with meds, referral sent.

Medications (added or continued this visit)

| Drug Name | Dose | Qty | Description |
|---|---|---|---|
| Ultracet | 37.5 Mg-325 Mg | 60 | take 2 tablet by oral route every 4 - 6 hours as needed, for up to 5 days; do not exceed 8 tablets in 24hrs |
| Floricet | 50 Mg-325 Mg-40 Mg | 60 | take 1 tablet by oral route every 4 hours as needed not to exceed 6 tablets per 24hrs |
| Vimpat | 100 Mg | 60 | take 1 tablet (100MG) by oral route 2 times every day |
| Vimpat | 50 Mg | 60 | take 1 tablet (50MG) by oral route 2 times every day |

Office Services

| Status | Order | Reason | Interpretation | Value |
|---|---|---|---|---|
| | Benjamin, Victor | | | |

completed Patient agrees with treatment plan & instructions

| Instructions / Education | | | Reason |
|---|---|---|---|
| Status | Completed | Order | |
| completed | 10/23/2012 | Reviewed medications | |
| completed | 10/23/2012 | Risks/ benefits of treatment plan | |
| completed | 10/23/2012 | Activity as tolerated | |
| completed | 10/23/2012 | Continue current medication | |

| To be scheduled/ordered | | | | | |
|---|---|---|---|---|---|
| Status | Order | Reason | Assessment | Timeframe | Appointment |
| completed | Follow-up if symptoms persist / worsen | | | 723.1 | 10/23/2012 |
| scheduled | Office Visit | Follow-up on medication | | 723.1 | -today 10/23/2012 |
| scheduled | Office Visit | Continue current treatment | | 723.1 | -today 10/23/2012 |
| completed | Follow-up for medication side effect | Follow-up visit | 723.1 | | 10/23/2012 |
| completed | Follow-up for increased symptoms | | 723.1 | -today | 10/23/2012 |
| | | | 723.1 | -today | 10/23/2012 |

Document generated by: George Sandoz 10/23/2012

CC Providers:
Leonard Goldschmidt
4882 Socastee Blvd
Myrtle Beach, SC 29588

Grand Strand Spine & Neuro
6170 Rourk Street, Myrtle Beach, SC 29572
Phone: (843) 445-2336
Fax: (843) 497-2505

Benjamin, Victor




| | |
|---|---|
| PATIENT: | Victor Benjamin |
| DATE OF BIRTH: | 2 |
| DATE: | 02/13/2015 12:30 PM |
| VISIT TYPE: | Office Visit |
| Historian: | self |

This 52 year old male presents for neck pain.

## History of Present Illness:

1. neck pain

   Onset: sudden. The problem is severe. Duration: year. The problem has worsened. The frequency of pain is daily. Location of pain is bilateral posterior neck. There is radiation of pain to the right face, right upper arm, right elbow and right forearm. The patient describes the pain as aching. The event(s) surrounding the occurrence of the symptom include injury. Aggravating factors include flexion, hyperextension, stooping, straining and working. Relieving factors include narcotic analgesics. Associated symptoms include difficulty sleeping, muscle atrophy, muscle spasm and tenderness. Pertinent negatives include bowel dysfunction not spinal related. Additional information: Doing fair until 1 week ago developed pain 10/10 worse from elbow down.

## Medications (active prior to today)

| Medication Name | Sig Dose | Start Date | Stop Date | Refilled | Elsewhere |
|---|---|---|---|---|---|
| Lidoderm 5 % (700 mg/patch) Adhesive Patch | apply 1 patch by transdermal route every day (May wear up to 12hours.) | 04/25/2013 | | | N |
| Vimpat 100 mg tablet | take 1 tablet (100MG) by oral route 2 times every day | 10/28/2014 | | 10/28/2014 | N |
| hydrocodone 10 mg-acetaminophen 325 mg tablet | take 1 Tablet by oral route every 6 hours as needed for pain | 01/13/2015 | | 01/13/2015 | N |
| hydrocodone 10 mg-acetaminophen 325 mg tablet | take 1 Tablet by oral route every 12 hours as needed for pain | 01/13/2015 | | 01/13/2015 | N |
| hydrocodone 10 mg-acetaminophen 325 mg tablet | take 1 Tablet by oral route every 12 hours as needed for pain | 01/13/2015 | | 01/13/2015 | N |
| Valium 10 mg tablet | take 1 tablet by oral route every 8 hours | 01/13/2015 | | 01/13/2015 | N |
| clonazepam 2 mg tablet | take 1 tablet by oral route 2 times every evening | 01/13/2015 | | 01/13/2015 | N |

Allergies:

| Ingredient | Reaction | Medication Name - Comment |
|---|---|---|
| MEPERIDINE HCL | | Demerol |

REVIEW OF SYSTEMS

| System | Neg/Pos | Details |
|---|---|---|
| GI | Negative | Bowel dysfunction not spinal related. |
| Psych | Positive | Difficulty sleeping. |
| MS | Positive | Muscle spasms, Muscular atrophy, Musculoskeletal tenderness. |

Physical Exam

| Exam | Findings | Details |
|---|---|---|
| Constitutional | Normal | No acute distress. Well nourished. Well developed. |
| Cardiovascular | Normal | Heart rate - Regular rate. Rhythm - Regular. Extremities - No edema. |
| Musculoskeletal | * | Cervical spine - muscle spasm. Elbow - Right: pain. Hands - Right + Tinel's Sign. |
| Musculoskeletal | Normal | Elbow -Left: Normal. |
| Neurological | * | Motor - weak r triceps. DTRs - symmetrically increased. |
| Neurological | Normal | Level of consciousness - Normal. Orientation - Normal. Memory - Normal. II. Optic - PERRL. III. Oculomotor - Grossly intact. IV. Trochlear - Grossly intact. V. Trigeminal - Grossly intact. Motor and reflexes: Grossly intact. Sensation: Grossly intact. VI. Abducens - Grossly intact. VII. Facial - Grossly intact. VIII. Acoustic - Grossly intact. IX. Glossopharyngeal - Grossly intact. X. Vagus - Grossly intact. XI. Spinal accessory - Grossly intact. XII. Hypoglossal - Grossly intact. Sensory - Normal. Balance & gait - Normal. Coordination - Normal. Fine motor skills - Normal. Hand dominance - Right-handed. |

Assessment/Plan

| # | Detail Type | Description |
|---|---|---|
| 1. | Assessment | Intervertebral disc disorder with myelopathy, cervical region (722.71). |
| | Impression | Worsen will see response to Butrans tens unit, thoracic spine nas re-order. |
| | Plan Orders | Further diagnostic evaluations ordered today include(s) MRI C-SPINE W/O & W/DYE, NCS 3-4 Studies Right arm and SOMATOSENSORY TESTING Bilateral leg/arm to be performed. |

Medications *(added, continued or stopped this visit)*:

| Started | Medication | Directions | Instruction | Stopped |
|---|---|---|---|---|
| 02/13/2015 | Butrans 10 mcg/hour transdermal patch | apply 1 patch by transdermal route every 7 days | | |
| 01/13/2015 | clonazepam 2 mg tablet | take 1 tablet by oral route 2 times every evening | | |
| 01/13/2015 | hydrocodone 10 mg-acetaminophen 325 mg tablet | take 1 Tablet by oral route every 6 hours as needed for pain | Do not fill until 2-12-15 | |
| 01/13/2015 | hydrocodone 10 mg-acetaminophen | take 1 Tablet by oral route every 12 hours as needed for | Do not fill until 3-12-15 | |

| | | |
|---|---|---|
| | 325 mg tablet | pain |
| 01/13/2015 | hydrocodone 10 mg-acetaminophen 325 mg tablet | take 1 Tablet by oral route every 12 hours as needed for pain |
| 04/25/2013 | Lidoderm 5 % (700 mg/patch) Adhesive Patch | apply 1 patch by transdermal route every day (May wear up to 12hours.) |
| 01/13/2015 | Valium 10 mg tablet | take 1 tablet by oral route every 8 hours |
| 10/28/2014 | Vimpat 100 mg tablet | take 1 tablet (100MG) by oral route 2 times every day |

*Provider: George M. Sandoz MD 02/13/2015 12:53 PM*
*Document generated by:* George Sandoz 02/13/2015 12:53 PM

**Grand Strand Spine and Neuro**
8170 Rourk Street
Myrtle Beach, SC 29572
Ph: (843) 449-2886
Fax: (843) 497-2505

# Grand Strand
## Regional Medical Center
## Spine & Neuro Center

| | |
|---|---|
| PATIENT: | Victor Benjamin |
| DATE OF BIRTH: | |
| DATE: | 06/20/2013 8:45 AM |
| VISIT TYPE: | Office Visit |

**Chief Complaint/Reason for visit:**
This 51 year old male presents with headache, neck pain and head injury.

**History of Present Illness**
1. headache
Onset: sudden. Severity: moderate-severe. It occurs daily, has Year(s) duration, and is worse. Location was frontal right, ocular right and occipital. There was radiation to anterior. The patient describes it as pressure and throbbing. Timing of headache: daytime. It occurred due to recent head trauma. Symptom is aggravated by head position, noise and stress. Denies relieving factors. Associated symptoms include blurred vision, dizziness and head trauma.
2. neck pain
Onset: sudden. The severity of the problem is moderate. The problem has worsened. The frequency of pain is daily. Location of pain is bilateral posterior neck. There was radiation of pain to the bilateral upper arm. The patient describes the pain as aching, burning and throbbing. The event(s) surrounding the occurrence of the symptom include axial loading. Aggravating factors include exertion, flexion, hyperextension, walking and working. Relieving factors tried include narcotic analgesics. Associated symptoms include difficulty sleeping, muscle spasm, sexual dysfunction not spinal related and tenderness. Pertinent negatives include bladder retention. Additional information: worsen and no relief of pain.
3. head injury
Onset: sudden. The severity of the symptoms is incapacitating. The symptoms have worsened. The location of the injury is in the bilateral frontal region. The location of pain is facial, head and neck. The mechanical force causing the injury was coup. Context includes metal object hit him in the head. The patient does not use alcohol. The patient does not use drugs. Denies relieving factors. Associated symptoms include clumsiness, gait disturbance, headache, incoordination, irritability, memory difficulty, nausea, personality change, restlessness, seizure, stiff neck and unusual behavior.

**Active Medications (started before visit)**

| Drug Name | Dose | Qty | Description |
|---|---|---|---|
| Lidoderm | 5 % (700 Mg/patch) | 30 | apply 1 patch by transdermal route every day (May wear up to 12hours.) |
| Klonopin | 1 Mg | 60 | take 1 - 2 Tablet (1MG) by oral route every evening |
| Restoril | 30 Mg | 30 | take 1 capsule (30MG) by oral route every day at bedtime as needed |
| Vimpat | 50 Mg | 60 | take 1 tablet (50MG) by oral route 2 times every day |

Medication list reviewed

**Allergies**
Reviewed, no changes.

| Allergen/Ingredient | Brand | Reaction: |
|---|---|---|
| Meperidine Hcl | | |

Benjamin, Victor

**Vital Signs**

**Height**

| Time | ft | in | cm | Last Measured | Method | % |
|---|---|---|---|---|---|---|
| 8:38 AM | 6.0 | | | 09/19/2011 | | 0 |

**Weight / BSA / BMI**

| Time | lb | oz | kg | Context | % | BMI kg/m2 | BSA m2 |
|---|---|---|---|---|---|---|---|
| 8:38 AM | 183.00 | | | dressed with shoes | 0 | 24.82 | |

**Blood Pressure**

| Time | BP mm/Hg | Position | Side | Site | Method | Cuff Size |
|---|---|---|---|---|---|---|
| 8:38 AM | 163/97 | sitting | left | brachial | manual | adult |

**Temp / Pulse / Respiration**

| Time | Temp F | Temp C | Temp Site | Pulse/min | Pattern | Resp/min |
|---|---|---|---|---|---|---|
| 8:38 AM | | | | 52 | | |

**Measured By**

| Time | |
|---|---|
| 8:38 AM | Jalessa Grant |

(sub_vs_condense: NOT FOUND)

**Physical Exam**

**Constitutional:**
Level of distress is moderate distress, irritable, in pain. Well nourished. Well developed.
**Musculoskeletal:**
Cervical spine has muscle spasm
No lumbar spine tenderness. Normal mobility and curvature.
**Neurological:**
Level of Consciousness: Normal.
Orientation: Alert and oriented X 3. Grossly normal intellect. .
Memory: Intact. .
Cranial nerves: II-XII grossly intact. .
Facial: normal.
Acoustic: Weber test abnormal, lateralizes to the right
Glossopharyngeal: normal.
Vagus: normal.
Sensory: No sensory loss. .
Motor: No motor weakness. .
Balance & Gait: using cane.
Coordination: Coordination intact. .
Fine Motor: Inaccurate movements.
Deep Tendon Reflexes: symmetrically decreased.
Comments: frontal release sign, mms 26/30

**Clinical Assessment**

The patient is a 51-year old male who presents with headache, neck pain and head injury. The patient is compliant with medication. Not responding to current treatment. Having some difficulty with ambulation. Needs some assistance with ADLs.

**Assessment/ Plan**

**Cervical disc displacement w/o myelopathy (722.0)**
**CHR POST-TRAUMA HEADACHE (338.22)**
**Epilepsy, unspecified (345.90)**
**Subjective tinnitus (388.31)**
**Intracranial injury of other and unspecified natur (854.01)**
**Late effect of intracranial injury without mention (907.0)**
S/p injury when a metal cover hit him in the head, s/p cervical surgery due to cervical dd worsen symptoms and no resolution of pain, new mri and evoked response order, injury cause epilepsy tolerating Vimpat 100 mg bid well no new event for mre than 6 months and reinstated driving priviliges, awaiting input by ENT for tinnitus continue with

Benjamin, Victor

Epilepsy, unspecified (345.90)
Subjective tinnitus (388.31)
Intracranial injury of other and unspecified natur (854.01)
Late effect of intracranial injury without mention (907.0)
S/p injury when a metal cover hit him in the head, s/p cervical surgery due to cervical dd worsen symptoms and no resolution of pain, new mri and evoked response order, injury cause epilepsy tolerating Vimpat 100 mg bid well no new event for mre than 6 months and reinstated driving priviliges, awaiting input by ENT for tinnitus continue with psychiatric support for issue from TBI, lost income and anxiety/anger/frontal release issue, trial with Vibryd with starter pack then 40 mg daily, 3 months follow up for pain control and other after testing schedule.

**Medications (added or continued this visit)**

| Drug Name | Dose | Qty | Description |
|---|---|---|---|
| Vimpat | 100 Mg | 60 | take 1 tablet (100MG) by oral route 2 times every day |
| Vibryd | 40 Mg | 30 | take 1 tablet (40MG) by oral route every day with food |
| Lorcet 10-650 | 10 Mg-650 Mg | 120 | take 1 tablet by oral route every 6 hours as needed for pain |
| Lorcet 10-650 | 10 Mg-650 Mg | 120 | take 1 tablet by oral route every 4 - 6 hours as needed for pain |
| Vibryd | 10 Mg (7)-20 Mg (7)-40 Mg (16) 1 | | |
| Lidoderm | 5 % (700 Mg/patch) | 30 | apply 1 patch by transdermal route every day (May wear up to 12hours.) |
| Klonopin | 1 Mg | 60 | take 1 - 2 Tablet (1MG) by oral route every evening |
| Restoril | 30 Mg | 30 | take 1 capsule (30MG) by oral route every day at bedtime as needed |
| Vimpat | 50 Mg | 60 | take 1 tablet (50MG) by oral route 2 times every day |

**Office Services**

| Status | Order | Reason | Interpretation | Value |
|---|---|---|---|---|
| completed | Adequate nutritional intake | | | |
| completed | Patient agrees with treatment plan & instructions | | | |

**Instructions / Education**

| Status | Completed | Order | Reason |
|---|---|---|---|
| completed | 06/20/2013 | Risks/ benefits of treatment plan | |
| completed | 06/20/2013 | Reviewed medications | |
| completed | 06/20/2013 | Continue current medication | |
| completed | 06/20/2013 | Activity as tolerated | |

**To be scheduled/ordered**

| Status | Order | Reason | Assessment | Timeframe | Appointment | |
|---|---|---|---|---|---|---|
| scheduled | Office visit | Discuss test results | | 722.0 | -today | 06/20/2013 |
| completed | Follow-up for medication side effect | | 722.0 | -today | 06/20/2013 | |
| scheduled | Office Visit | Follow-up on medication | | 722.0 | -today | 06/20/2013 |
| scheduled | Office visit | Continue current treatment | | 722.0 | -today | 06/20/2013 |
| completed | Follow-up for increased symptoms | | 722.0 | -today | 06/20/2013 | |
| completed | Follow-up if symptoms persist / worsen | | | 722.0 | 06/20/2013 | |
| ordered | SOMATOSENSORY TESTING | | 722.0 | | 06/20/2013 | |
| ordered | MRI C-SPINE W/O & W/DYE | | 722.0 | | 06/20/2013 | |

Document generated by: George Sandoz 06/20/2013

Grand Strand Spine & Neuro
6170 Rourk Street, Myrtle Beach, SC 29572
Phone: (843) 449-2336
Fax: (843) 497-2505

Benjamin, Victor

# Grand Strand
HEALTH SYSTEM

## Spine & Neuro Center

PATIENT: Victor Benjamin
DATE OF BIRTH:
DATE: 07/16/2015 11:00 AM
VISIT TYPE: Office Visit
Historian: self

This 53 year old male presents for neck pain and back pain.

### History of Present Illness:

1. neck pain
   Onset: sudden. The problem is severe. The problem has worsened. The frequency of pain is daily. Location of pain is bilateral posterior neck. There is radiation of pain to the bilateral upper arm. The patient describes the pain as aching and burning. The event(s) surrounding the occurrence of the symptom include injury. Aggravating factors include exertion, hyperextension, pushing, straining, walking and working. Relieving factors include ice, injection, massage, narcotic analgesics, NSAIDs, physical therapy and standing. Associated symptoms include bladder incontinence, decreased mobility, difficulty sleeping, incoordination, loss of balance, muscle atrophy, muscle spasm, numbness, sexual dysfunction, tenderness, tingling and weakness. Pertinent negatives include bladder dysfunction not spinal related, bladder retention, bowel dysfunction not spinal related, bowel incontinence, bowel retention, dermatomic rash, dysphagia, joint pain, rash, sexual dysfunction (not spinal related) and weight loss. Additional information: feels worse unable to ambulate forlon distance causing decrease on ADL's, in bed until 3 back in bed after few hours and no relief with hydrocodone.
2. back pain
   Onset: sudden with injury. Duration: year. The problem is worsening. It occurs persistently. Location of pain is lower back. Pain is radiated to the dermatome anteriorly. The patient describes the pain as an ache, burning and throbbing. Context: trauma. Symptoms are aggravated by daily activities. Symptoms are relieved by pain meds/drugs.

### Medications (active prior to today)

| Medication Name | Sig Desc | Start Date | Stop Date | Refill | Elsewhere |
|---|---|---|---|---|---|
| Lidoderm 5 % (700 mg/patch) Adhesive Patch | apply 1 patch by transdermal route every day (May wear up to 12hours) | 04/25/2013 | | | N |
| Valium 10 mg tablet | take 1 tablet by oral route every 8 hours | 01/13/2015 | | 01/13/2015 | N |
| promethazine 25 mg | take 1 tablet by oral route | 02/18/2015 | | | N |

| | | | | |
|---|---|---|---|---|
| tablet | every 8 hours prn nausea | | | |
| hydrocodone 10 mg-acetaminophen 325 mg tablet | take 1 Tablet by oral route every 12 hours as needed for pain | 04/14/2015 | 04/14/2015 | N |
| hydrocodone 10 mg-acetaminophen 325 mg tablet | take 1 Tablet by oral route every 12 hours as needed for pain | 04/14/2015 | 04/14/2015 | N |
| hydrocodone 10 mg-acetaminophen 325 mg tablet | take 1 Tablet by oral route every 6 hours as needed for pain | 04/14/2015 | 04/14/2015 | N |
| clonazepam 2 mg tablet | take 1 tablet by oral route 2 times every evening | 04/14/2015 | 04/14/2015 | N |
| Vimpat 100 mg tablet | take 1 tablet (100MG) by oral route 2 times every day | 04/22/2015 | 04/22/2015 | N |

## Allergies:

| Ingredient | Reaction | Medication Name | Comment |
|---|---|---|---|
| MEPERIDINE HCL | | Demerol | |

## REVIEW OF SYSTEMS

| System | Neg/Pos | Details |
|---|---|---|
| Constitutional | Negative | Weight loss. |
| ENMT | Negative | Dysphagia. |
| GI | Negative | Bowel dysfunction not spinal related, fecal incontinence and fecal retention. |
| GU | Positive | Urinary incontinence. |
| GU | Negative | Bladder dysfunction not spinal related, sexual dysfunction not spinal related and urinary retention. |
| Neuro | Positive | Incoordination, Loss of balance, Numbness, Tingling. |
| Psych | Positive | Difficulty sleeping. |
| Integumentary | Negative | Dermatomic rash and rash. |
| MS | Positive | Decreased mobility, Muscle spasms, Muscular atrophy, Musculoskeletal tenderness, Weakness. |
| MS | Negative | Joint pain. |
| Reproductive | Positive | Sexual dysfunction. |

## Physical Exam

| Exam | Findings | Details |
|---|---|---|
| Constitutional | * | Level of distress - moderate distress. |
| Constitutional | Normal | Well nourished. Well developed. |
| Cardiovascular | Normal | Heart rate - Regular rate. Rhythm - Regular. Extremities - No edema. |
| Musculoskeletal | * | Cervical spine - muscle spasm, Range of motion: severe pain w/ motion. Lumbar spine - muscle spasm, Range of motion: severely reduced ROM. |
| Neurological | * | Motor - spastic Quadriparesis. Balance & gait - spastic hemiparesis. DTRs - symmetrically increased. |
| Neurological | Comments | fluent speech |
| Neurological | Normal | Level of consciousness - Normal. Orientation - Normal. Memory - Normal. II. Optic - PERRL. III. Oculomotor - Grossly intact. IV. Trochlear - Grossly intact. V. Trigeminal - Grossly intact, Motor and reflexes: Grossly |

| | | |
|---|---|---|
| | | Intact, Sensation: Grossly intact. VI. Abducens - Grossly intact. VII. Facial - Grossly intact. VIII. Acoustic - Grossly intact. IX. Glossopharyngeal - Grossly intact. X. Vagus - Grossly intact. XI. Spinal accessory - Grossly intact. XII. Hypoglossal - Grossly intact. Sensory - Normal. Coordination - Normal. Fine motor skills - Normal. Hand dominance - Right-handed. |
| Psychiatric | * | Anhedonia. Inappropriate mood and affect - severely depressed. |
| Psychiatric | Normal | Orientation - Oriented to time, place, person & situation. Normal insight. Normal judgment. |

## Assessment/Plan

[illegible]

1. Assessment Lumbago (724.2).
   Impression Doing physical well not yet to be completed

2. Assessment Late effect of intracranial injury without mention of skull fracture (907.0)
   Impression Causing seizure and migraine controled with meds.

3. Assessment Chronic pain syndrome (338.4).
   Impression [illegible] Interpersonal relation suffering due to poor mood control seek treatment for meds and better pain control using oxycodone or hydromorphone.

## Medications *(added, continued or stopped this visit)*:

| Started | Medication | Directions | Instruction | Stopped |
|---|---|---|---|---|
| 07/16/2015 | Cialis 10 mg tablet | take 1 tablet by oral route every day as needed | | |
| 04/14/2015 | clonazepam 2 mg tablet | take 1 tablet by oral route 2 times every evening | | |
| 04/14/2015 | hydrocodone 10 mg-acetaminophen 325 mg tablet | take 1 Tablet by oral route every 12 hours as needed for pain | | |
| 04/14/2015 | hydrocodone 10 mg-acetaminophen 325 mg tablet | take 1 Tablet by oral route every 12 hours as needed for pain | Do not fill until 5-13-15 | |
| 04/14/2015 | hydrocodone 10 mg-acetaminophen 325 mg tablet | take 1 Tablet by oral route every 6 hours as needed for pain | Do not fill until 6-12-15 | |
| 07/16/2015 | hydromorphone 4 mg tablet | take 1 tablet by oral route every 8 hours | | |
| 07/16/2015 | Lexapro 10 mg tablet | take 1 tablet by oral route every day | | |
| 04/25/2013 | Lidoderm 5 % (700 mg/patch) Adhesive Patch | apply 1 patch by transdermal route every day (May wear up to 12hours.) | | |
| 07/16/2015 | oxycodone-acetaminophen 10 mg-325 mg tablet | take 1 tablet by oral route every 8 hours as needed | | |
| 02/16/2015 | promethazine 25 mg tablet | take 1 tablet by oral route every 8 hours prn nausea | | |

| | | |
|---|---|---|
| 01/13/2015 | Valium 10 mg tablet | take 1 tablet by oral route every 8 hours |
| 04/22/2015 | Vimpat 100 mg tablet | take 1 tablet (100MG) by oral route 2 times every day |

*Provider: George M. Sandoz MD 07/16/2015 12:36 PM*
*Document generated by:* George Sandoz 07/16/2015 12:36 PM

# Grand Strand
Regional Medical Center

## Spine & Neuro Center

| | |
|---|---|
| PATIENT: | Victor Benjamin |
| DATE OF BIRTH: | [illegible] |
| DATE: | 10/08/2013 4:29 PM |
| VISIT TYPE: | Office Visit |

**Chief Complaint/Reason for visit:**
This 51 year old male presents with neck pain, dizziness, headache, seizure and follow up.

**History of Present Illness**

**1. neck pain**
Onset: sudden. The severity of the problem is moderate. The problem has worsened. The frequency of pain is daily. Location of pain is bilateral posterior neck. There was radiation of pain to the bilateral upper arm. The patient describes the pain as aching, burning and throbbing. The event(s) surrounding the occurrence of the symptom include axial loading. Aggravating factors include exertion, flexion, pushing, rotation and working. Relieving factors tried include narcotic analgesics. Associated symptoms include difficulty sleeping, muscle spasm, numbness, sexual dysfunction and tenderness. Pertinent negatives include bladder retention.

**2. dizziness**
Onset was sudden. Severity is moderate-severe. The duration of each episode is Month(s). The problem is worsening. It occurs persistently. The patient describes it as (an) unstable horizon. It occurs while. The patient has sustained a head injury in the past. Symptom is aggravated by turning. Relieving factors include position change. Associated symptoms include hearing loss, neck stiffness, paresthesias, seizures, tinnitus, vomiting and weakness. Pertinent negatives include diplopia.

**3. headache**
Onset: sudden. Severity: moderate-severe. It occurs daily, has Month(s) duration, and is worse. Location was occipital. There was radiation to posterior. The patient describes it as pressure and throbbing. Timing of headache: upon awakening. Symptom is aggravated by bright lights, head position and noise. Relieving factors include prescription drugs. Associated symptoms include dizziness, memory loss, neurological symptoms, performance changes, stiff neck and vertigo.

**4. seizure, follow up**
Date of last seizure was 02/19/2012. Date of last EEG was 02/22/2012. The type of seizure is Focal with secondary generalization. The context of the seizure includes TBI. Medication(s) used vimpat with good results.; he is compliant with medication; there are no side effects of medication Symptom is aggravated by and lack of sleep. Associated symptoms include aura, staring and unresponsiveness. Additional information: He is driving.

**Active Medications (started before visit)**

| Drug Name | Dose | Qty | Description |
|---|---|---|---|
| Vimpat | 100 Mg | 60 | take 1 tablet (100MG) by oral route 2 times every day |
| Vilbryd | 40 Mg | 30 | take 1 tablet (40MG) by oral route every day with food |
| Lorcet 10-650 | 10 Mg-650 Mg | 120 | take 1 tablet by oral route every 6 hours as needed for pain |
| Lidoderm (May wear up to 12hours.) | 5 % (700 Mg/patch) | 30 | apply 1 patch by transdermal route every day |

Benjamin, Victor

**Allergies**

| Allergen/Ingredient | Brand | Reaction: |
|---|---|---|
| Meperidine Hcl | | |

**Vital Signs**
{sub_vs_condense: NOT FOUND}

**Physical Exam**
**Constitutional:**
Level of distress is mild distress. Well nourished. Well developed.
**Musculoskeletal:**
Cervical spine has muscle spasm, moderate pain w/motion
No lumbar spine tenderness. Normal mobility and curvature.
Right shoulder has tenderness
**Neurological:**
Level of Consciousness: Normal.
Orientation: Alert and oriented X 3. Grossly normal intellect. .
Memory: Intact. .
Optic Nerve: Optic normal.
Oculomotor: normal.
Trochlear: normal.
Abducens: normal.
Trigeminal:
Motor and Reflexes: normal.
Facial: normal.
Acoustic: normal.
Glossopharyngeal: normal.
Vagus: normal.
Spinal Accessory: normal.
Hypoglossal: normal.
Sensory: No sensory loss. .
Motor: No motor weakness. .
Balance & Gait: Balance and gait intact. .
Coordination: Coordination intact. .
Fine Motor: Skills normal. .
Deep Tendon Reflexes: DTR's preserved and symmetric. .

**Clinical Assessment**
The patient is a 51-year old male who presents with neck pain, dizziness, headache and seizure, follow up. The patient is compliant with medication. Responding to current treatment. Having some difficulty with ambulation. Needs some assistance with ADLs.

**Assessment/ Plan**
**CHR POST-TRAUMA HEADACHE (339.22)**
Continue with Lorcet for pain control, consider botox to relief symptoms.
**Epilepsy, unspecified (345.90)**
Tolerating Vimpat 100 bid well and without side effect, cpm.
**Dizziness (780.4)**
Due to inner damage as noted on nystagmogram, for tinnitus no treatment is available
**Other and unspecified disc disorder of cervical re (722.91)**
Still pending esi cervical spine to minimize impairment and maximize recovery.
**Pain in joint involving shoulder region (719.41)**
Noted on mri shoulder finally done not seen orthopedic surgeon.
**Late effect of intracranial injury without mention (907.0)**
causing significant anxiety issues, stressed compliance with meds, sleeping affected, will stp clonopin and trial with Trazodone 50-150 mg qhs and see response, discussed with cnm.

Benjamin, Victor

**Medications (added or continued this visit)**

| Drug Name | Dose | Qty | Description |
|---|---|---|---|
| Trazodone Hcl | 150 Mg | 30 | take 1 tablet (150MG) by ORAL route every day at bedtime |
| Lorcet 10-650 | 10 Mg-650 Mg | 120 | take 1 tablet by oral route every 4 - 6 hours as needed for pain |
| Lorcet 10-650 | 10 Mg-650 Mg | 120 | take 1 tablet by oral route every 6 hours as needed for pain |
| Vimpat | 100 Mg | 60 | take 1 tablet (100MG) by oral route 2 times every day |
| Vibryd | 40 Mg | 30 | take 1 tablet (40MG) by oral route every day with food |
| Lidoderm | 5 % (700 Mg/patch) | 30 | apply 1 patch by transdermal route every day (May wear up to 12hours.) |

**Office Services**

| Status | Order | Reason | Interpretation | Value |
|---|---|---|---|---|
| completed | Adequate nutritional intake | | | |
| completed | Patient agrees with treatment plan & instructions | | | |

**Instructions / Education**

| Status | Completed | Order | Reason |
|---|---|---|---|
| completed | 10/08/2013 | Risks/ benefits of treatment plan | |
| completed | 10/08/2013 | Continue current medication | |
| completed | 10/08/2013 | Activity as tolerated | |

**To be scheduled/ordered**

| Status | Order | Reason | Assessment | Timeframe | Appointment | |
|---|---|---|---|---|---|---|
| scheduled | Office visit | Continue current treatment | 339.22 | -today | 10/08/2013 | |
| completed | Follow-up for medication side effect | | 339.22 | -today | 10/08/2013 | |
| completed | Follow-up for increased symptoms | | 339.22 | -today | 10/08/2013 | |
| completed | Follow-up if symptoms persist / worsen | | | 339.22 | 10/08/2013 | |
| scheduled | Office Visit | Follow-up on medication | | 339.22 | -today | 10/08/2013 |

Document generated by: George Sandoz 10/08/2013

CC Providers:
Leonard Goldschmidt
4882 Socastee Blvd
Myrtle Beach, SC 29588

Grand Strand Spine & Neuro
8170 Rourk Street, Myrtle Beach, SC 29572
Phone: (843) 449-2336
Fax: (843) 497-2505

Benjamin, Victor

# Grand Strand HEALTH SYSTEM

## Spine & Neuro Center

PATIENT: Victor Benjamin
DATE OF BIRTH:
DATE: 02/13/2015 12:30 PM
VISIT TYPE: Office Visit
Historian: self

This 52 year old male presents for neck pain.

### History of Present Illness:

1. neck pain
   Onset: sudden. The problem is severe. Duration: year. The problem has worsened. The frequency of pain is daily. Location of pain is bilateral posterior neck. There is radiation of pain to the right face, right upper arm, right elbow and right forearm. The patient describes the pain as aching. The event(s) surrounding the occurrence of the symptom include injury. Aggravating factors include flexion, hyperextension, stooping, straining and working. Relieving factors include narcotic analgesics. Associated symptoms include difficulty sleeping, muscle atrophy, muscle spasm and tenderness. Pertinent negatives include bowel dysfunction not spinal related. Additional information: Doing fair until 1 week ago developed pain 10/10 worse from elbow down.

### Medications (active prior to today)

| Medication Name | Sig Desc | Start Date | Stop Date | Refilled | Elsewhere |
|---|---|---|---|---|---|
| Lidoderm 5 % (700 mg/patch) Adhesive Patch | apply 1 patch by transdermal route every day (May wear up to 12hours.) | 04/25/2013 | | | N |
| Vimpat 100 mg tablet | take 1 tablet (100MG) by oral route 2 times every day | 10/28/2014 | | 10/28/2014 | N |
| hydrocodone 10 mg-acetaminophen 325 mg tablet | take 1 Tablet by oral route every 6 hours as needed for pain | 01/13/2015 | | 01/13/2015 | N |
| hydrocodone 10 mg-acetaminophen 325 mg tablet | take 1 Tablet by oral route every 12 hours as needed for pain | 01/13/2015 | | 01/13/2015 | N |
| hydrocodone 10 mg-acetaminophen 325 mg tablet | take 1 Tablet by oral route every 12 hours as needed for pain | 01/13/2015 | | 01/13/2015 | N |
| Valium 10 mg tablet | take 1 tablet by oral route every 8 hours | 01/13/2015 | | 01/13/2015 | N |
| clonazepam 2 mg tablet | take 1 tablet by oral route 2 times every evening | 01/13/2015 | | 01/13/2015 | N |

## Allergies:

| Ingredient | Reaction | Medication Name | Comment |
|---|---|---|---|
| MEPERIDINE HCL | | Demerol | |

## REVIEW OF SYSTEMS

| System | Neg/Pos | Details |
|---|---|---|
| GI | Negative | Bowel dysfunction not spinal related. |
| Psych | Positive | Difficulty sleeping. |
| MS | Positive | Muscle spasms, Muscular atrophy, Musculoskeletal tenderness. |

## Physical Exam

| Exam | Findings | Details |
|---|---|---|
| Constitutional | Normal | No acute distress. Well nourished. Well developed. |
| Cardiovascular | Normal | Heart rate - Regular rate. Rhythm - Regular. Extremities - No edema. |
| Musculoskeletal | * | Cervical spine - muscle spasm. Elbow - Right: pain. Hands - Right: + Tinel's Sign. |
| Musculoskeletal | Normal | Elbow -Left: Normal. |
| Neurological | * | Motor - weak r triceps. DTRs - symmetrically increased. |
| Neurological | Normal | Level of consciousness - Normal. Orientation - Normal. Memory - Normal. II. Optic - PERRL. III. Oculomotor - Grossly intact. IV. Trochlear - Grossly intact. V. Trigeminal - Grossly intact. Motor and reflexes: Grossly intact. Sensation: Grossly intact. VI. Abducens - Grossly intact. VII. Facial - Grossly intact. VIII. Acoustic - Grossly intact. IX. Glossopharyngeal - Grossly intact. X. Vagus - Grossly intact. XI. Spinal accessory - Grossly intact. XII. Hypoglossal - Grossly intact. Sensory - Normal. Balance & gait - Normal. Coordination - Normal. Fine motor skills - Normal. Hand dominance - Right-handed. |

## Assessment/Plan

| # | Detail Type | Description |
|---|---|---|
| 1. | Assessment | Intervertebral disc disorder with myelopathy, cervical region (722.71). |
| | Impression | Warren will see response to Butrans tens unit, mri cervical spine per his order. |
| | Plan Orders | Further diagnostic evaluations ordered today include(s) MRI C-SPINE W/O & W/DYE, NCS 3-4 Studies Right arm and SOMATOSENSORY TESTING Bilateral leg/arm to be performed. |

## Medications *(added, continued or stopped this visit)*:

| Started | Medication | Directions | Instruction | Stopped |
|---|---|---|---|---|
| 02/13/2015 | Butrans 10 mcg/hour transdermal patch | apply 1 patch by transdermal route every 7 days | | |
| 01/13/2015 | clonazepam 2 mg tablet | take 1 tablet by oral route 2 times every evening | | |
| 01/13/2015 | hydrocodone 10 mg-acetaminophen 325 mg tablet | take 1 Tablet by oral route every 6 hours as needed for pain | Do not fill until 2-12-15 | |
| 01/13/2015 | hydrocodone 10 mg-acetaminophen | take 1 Tablet by oral route every 12 hours as needed for | Do not fill until 3-12-15 | |

| | | |
|---|---|---|
| | 325 mg tablet | pain |
| 01/13/2015 | hydrocodone 10 mg-acetaminophen 325 mg tablet | take 1 Tablet by oral route every 12 hours as needed for pain |
| 04/25/2013 | Lidoderm 5 % (700 mg/patch) Adhesive Patch | apply 1 patch by transdermal route every day (May wear up to 12hours.) |
| 01/13/2015 | Valium 10 mg tablet | take 1 tablet by oral route every 8 hours |
| 10/28/2014 | Vimpat 100 mg tablet | take 1 tablet (100MG) by oral route 2 times every day |

*Provider: George M. Sandoz MD 02/13/2015 12:53 PM*
*Document generated by:* George Sandoz 02/13/2015 12:53 PM

**Grand Strand Spine and Neuro**
8170 Rourk Street
Myrtle Beach, SC 29572
Ph: (843) 497-2336
Fax (843) 497-2505

Grand Strand Spine & Neuro Ctr.
8170 Rourke Street
Myrtle Beach, SC 29572
(843) 449-2336

Patient: Benjamin, Victor
Sex: Male
Age:
I.D.#:
Ref. M.D.:

Physician: Dr Sandoz
Test Date: 03/26/15

**History/Comments:**

DOB 04-19-62 Intervetrebral disc disorder with myopathy of cervical region

**Motor Nerve Study**

| Right Median Nerve<br>Rec Site: APB<br>Stim Site | Lat (ms) | Norm Lat | Amp (mV) | Norm Amp | C.V. (m/s) | Norm C.V. |
|---|---|---|---|---|---|---|
| Wrist | 3.4 | 4.5 | 8.9 | 3 | | 48 |
| Elbow | 8.6 | | 8.6 | | 50.3 | |

| Right Ulnar Nerve<br>Rec Site: ADM<br>Stim Site | Lat (ms) | Norm Lat | Amp (mV) | Norm Amp | C.V. (m/s) | Norm C.V. |
|---|---|---|---|---|---|---|
| Wrist | 3.3 | 3.6 | 12.6 | 5 | | 48 |
| B.Elbow | 6.8 | | 11.3 | | 84.4 | |
| A.Elbow | 8.2 | | 9.0 | | 70.6 | |

**Sensory Nerve Study**

| Right Median Nerve<br>Rec Site: Wrist<br>Stim Site | Norm Lat | Pk Lat (ms) | Amp (uV) | Norm Amp |
|---|---|---|---|---|
| Thumb | 2.3 | 2.3 | 58.9 | 40 |
| Index | | 2.3 | 48.2 | |

| Right Ulnar Nerve<br>Rec Site: Wrist<br>Stim Site | Norm Lat | Pk Lat (ms) | Amp (uV) | Norm Amp |
|---|---|---|---|---|
| 5th dig | 2.2 | 2.5 | 14.7 | 11 |
| Ring | | 2.3 | 12.0 | |

| Right Radial Nerve<br>Rec Site: Wrist<br>Stim Site | Norm Lat | Pk Lat (ms) | Amp (uV) | Norm Amp |
|---|---|---|---|---|
| Index | 2.7 | 2.1 | 21.7 | 15 |
| | | 2.1 | 28.3 | |

Patient: Benjamin, Victor Test Date: 03/26/15
I.D.#:

## F-Wave Study

| Right Median Nerve<br>Rec Site: APB<br>Stim Site: Wrist | Latency<br>ms | Normal<br>Latency |
|---|---|---|
| M wave | 3.75 | |
| F wave | 28.92 | 32 |

| Right Ulnar Nerve<br>Rec Site: ADM<br>Stim Site: Wrist | Latency<br>ms | Normal<br>Latency |
|---|---|---|
| M wave | 3.33 | |
| F wave | 31.33 | 32 |

## EMG Study

| Name | Ins Act | Fibs | PSW | Fascics | Polyph | MU Amp | MU Dur | Config | Pattern | Recruit |
|---|---|---|---|---|---|---|---|---|---|---|
| R. Pronator Ter. | norm | none | none | none | none | norm | norm | norm | norm | norm |
| R. Biceps Brachi. | norm | none | none | none | none | norm | norm | norm | norm | norm |
| R. Triceps | norm | none | none | none | none | norm | norm | norm | norm | norm |
| R. Deltoid | norm | none | none | none | none | norm | norm | norm | norm | norm |
| R. Ext Carp Uln | norm | none | none | none | none | norm | norm | norm | norm | norm |
| R. Flex Dig Prof | norm | none | none | none | none | norm | norm | norm | norm | norm |
| R. ADQ | norm | none | none | none | none | norm | norm | norm | norm | norm |
| R. Dors.Int.1 | norm | none | none | none | none | norm | norm | norm | norm | norm |
| R. Abd.Pol.Br. | norm | none | none | none | none | norm | norm | norm | norm | norm |
| R. Low Cerv Para | inc | 3+ | 3+ | none | none | norm | norm | norm | norm | norm |

**Summary/Interpretation:**
Right median CMAP normal distal latency, amplitude, and conduction velocity. F-waves normal.
Right ulnar CMAP normal distal latency, amplitude, and conduction velocity. F-waves normal.
Right median SNAP borderline distal latency and normal amplitude.
Right ulnar SNAP prolonged distal latency and normal amplitude.
Right radial SNAP normal distal latency and amplitude.

Needle electromyography examination of the right upper extremity and right cervical paraspinal muscles demonstrated: Increased insertional activity and 3+ fibs and PSW at the right low lumbar paraspinal muscles.

Impression: 1. Borderline right sensory CTS.
2. Mild right ulnar sensory neuropathy at the wrist.
3. Right cervical radiculopathy.
4. Clinical correlation is recommended.

George Sandoz, M.D.

Patient: Benjamin, Victor
I.D.#:
Test Date: 03/26/15

R. Median MNC

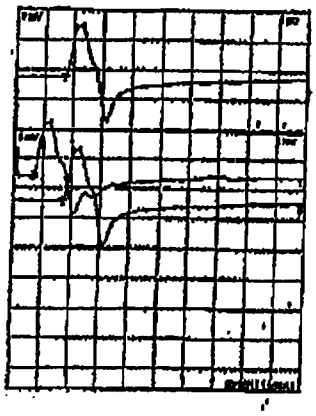

R. Ulnar MNC

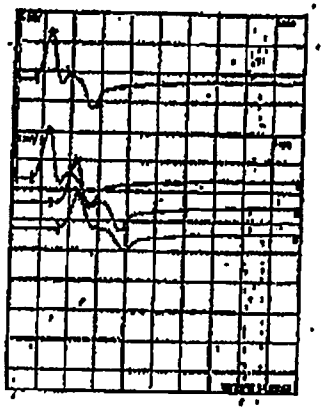

R. Median SNC

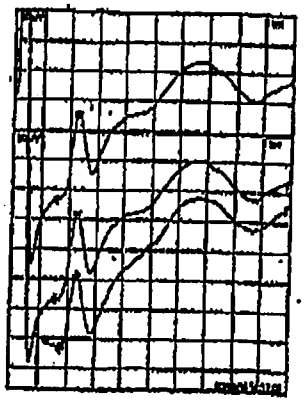

R. Ulnar SNC

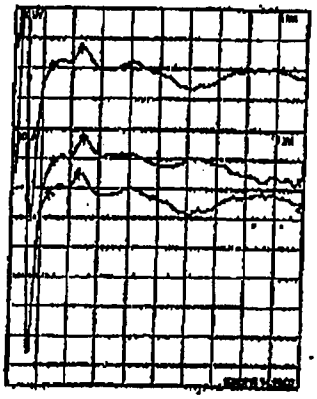

R. Radial SNC

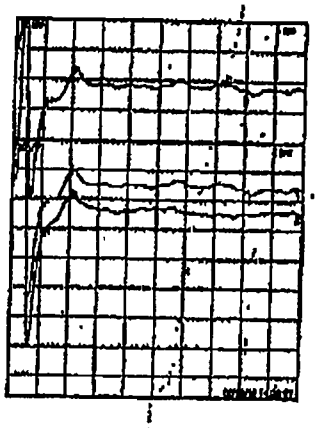

R. Median F-wave

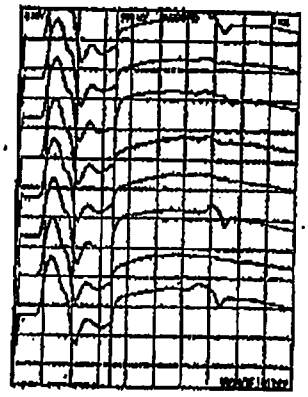

R. Ulnar F-wave

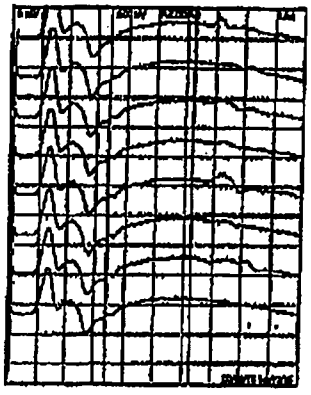

Grand Strand Spine & Neuro Ctr.
8170 Rourke Street
Myrtle Beach, SC 29572
(843) 449-2336

Patient: Benjamin, Victor
Sex: Male
Age: [illegible]
I.D.#: [illegible]
Ref. M.D.:

Physician: Dr Sandoz
Test Date: 03/26/15

History/Comments:

DOB 04-19-62 Intervertebral disc disorder with myopathy

Evoked Potential Study
Left Median Nerve

| Set | Sweeps | Lat (ms) N7 | Lat (ms) N13 | Lat (ms) N17 | Lat (ms) N20 |
|---|---|---|---|---|---|
| | 504 | 8.0 | 16.5 | 18.1 | 23.1 |
| | 507 | | | | |

Evoked Potential Study
Right Median Nerve

| Set | Sweeps | Lat (ms) N7 | Lat (ms) N13 | Lat (ms) N17 | Lat (ms) N20 |
|---|---|---|---|---|---|
| | 503 | 11.8 | 14.5 | 20.4 | 25.8 |
| | 508 | | | | |

Evoked Potential Study
Left Tibial Nerve

| Set | Sweeps | Lat (ms) N7 | Lat (ms) N17 | Lat (ms) N20 | Lat (ms) P42 | Lat (ms) N50 | IPI1 (ms) N7-P42 | Amp1 (uV) P42-N50 | Amp2 (uV) N7-N17 |
|---|---|---|---|---|---|---|---|---|---|
| | 500 | 3.5 | 18.5 | 23.7 | 44.0 | 53.8 | 40.5 | 0.5 | |
| | 500 | | | | | | | | |

Patient: Benjamin, Victor
I.D.#: Test Date: 03/26/15

L. Median EP



R. Median EP

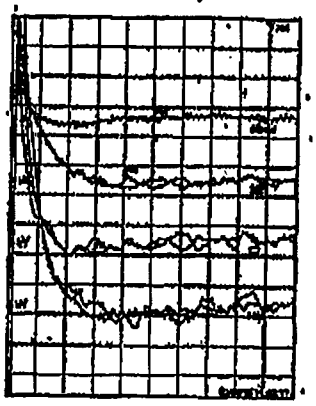

L. Tibial EP

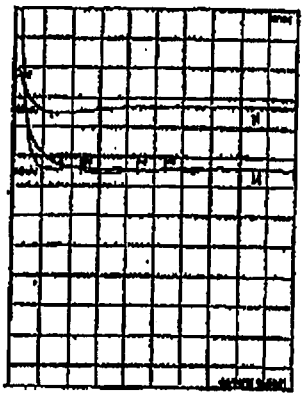

R. Tibial EP

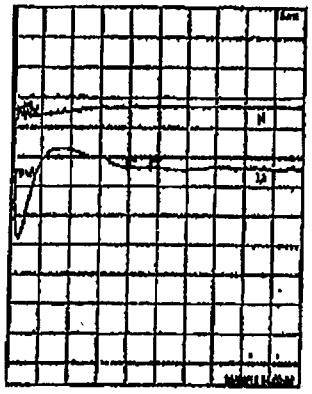

Patient: Benjamin Victor Test Date: 03/26/15
I.D.#:

Evoked Potential Study
Right Tibial Nerve

| Set | Sweeps | Lat (ms) N7 | Lat (ms) N17 | Lat (ms) N20 | Lat (ms) P42 | Lat (ms) N50 | IPI (ms) N7-P42 | Amp1 (uV) P42-N50 | Amp2 (uV) N7-N17 |
|---|---|---|---|---|---|---|---|---|---|
| | 500 | 3.8 | | | 39.2 | 47.5 | 35.3 | 0.9 | |

Summary/Interpretation:
The Upper/Lower Extremity Somatosensory Evoked Response Tests are within normal limits. Clinical correlation is recommended.

George Sandoz, M.D.

# Grand Strand HEALTH SYSTEM

## Spine & Neuro Center

PATIENT: Victor Benjamin
DATE OF BIRTH:
DATE: 04/14/2015 10:15 AM
VISIT TYPE: Office Visit

This 52 year old male presents for neck pain.

### History of Present Illness:

1. neck pain
   Onset: sudden. The problem is severe. Duration: year. The problem has not changed. The frequency of pain is constant. Location of pain is bilateral posterior neck. There is radiation of pain to the bilateral upper arm. The patient describes the pain as aching and burning. The event(s) surrounding the occurrence of the symptom include injury. Aggravating factors include driving, exertion, flexion, prolonged sitting, pushing, standing, stooping, walking and working. Relieving factors include injection, muscle relaxation techniques, narcotic analgesics and NSAIDs. Associated symptoms include difficulty sleeping, dysphagia, joint pain, muscle atrophy, muscle spasm, numbness, sexual dysfunction, tenderness, tingling and weakness. Pertinent negatives include bladder dysfunction not spinal related, bladder incontinence, bladder retention, bowel dysfunction not spinal related, bowel incontinence, bowel retention, decreased mobility, dermatomic rash, incoordination, loss of balance, rash, sexual dysfunction (not spinal related) and weight loss.

PAST SYSTEMIC HISTORY
Patient reported no relevant past medical/surgical history.

### Medications (active prior to today)

| Medication Name | Sig.Desc | Start Date | Stop Date | Refilled | Elsewhere |
|---|---|---|---|---|---|
| Lidoderm 5 % (700 mg/patch) Adhesive Patch | apply 1 patch by transdermal route every day (May wear up to 12hours.) | 04/25/2013 | | | N |
| Vimpat 100 mg tablet | take 1 tablet (100MG) by oral route 2 times every day | 10/28/2014 | | 10/28/2014 | N |
| hydrocodone 10 mg-acetaminophen 325 mg tablet | take 1 Tablet by oral route every 6 hours as needed for pain | 01/13/2015 | 04/14/2015 | 04/14/2015 | N |
| hydrocodone 10 mg-acetaminophen 325 mg tablet | take 1 Tablet by oral route every 12 hours as needed for pain | 01/13/2015 | 04/14/2015 | 04/14/2015 | N |
| hydrocodone 10 mg-acetaminophen 325 | take 1 Tablet by oral route every 12 hours as needed | 01/13/2015 | 04/14/2015 | 04/14/2015 | N |

| | | | | | |
|---|---|---|---|---|---|
| mg tablet | for pain | | | | |
| Valium 10 mg tablet | take 1 tablet by oral route every 8 hours | 01/13/2015 | | 01/13/2015 | N |
| clonazepam 2 mg tablet | take 1 tablet by oral route 2 times every evening | 01/13/2015 | 04/14/2015 | 04/14/2015 | N |
| Butrans 10 mcg/hour transdermal patch | apply 1 patch by transdermal route every 7 days | 02/13/2015 | 04/14/2015 | | N |
| promethazine 25 mg tablet | take 1 tablet by oral route every 8 hours prn nausea | 02/18/2015 | | | N |

Allergies:

| Ingredient | Reaction | Medication Name | Comment |
|---|---|---|---|
| MEPERIDINE HCL | | Demerol | |

REVIEW OF SYSTEMS

| System | Neg/Pos | Details |
|---|---|---|
| Constitutional | Negative | Weight loss. |
| ENMT | Positive | Dysphagia. |
| GI | Negative | Bowel dysfunction not spinal related, fecal incontinence and fecal retention. |
| GU | Negative | Bladder dysfunction not spinal related, sexual dysfunction not spinal related, urinary incontinence and urinary retention. |
| Neuro | Positive | Numbness, Tingling. |
| Neuro | Negative | Incoordination and loss of balance. |
| Psych | Positive | Difficulty sleeping. |
| Integumentary | Negative | Dermatomic rash and rash. |
| MS | Positive | Joint pain, Muscle spasms, Muscular atrophy, Musculoskeletal tenderness, Weakness. |
| MS | Negative | Decreased mobility. |
| Reproductive | Positive | Sexual dysfunction. |

VITAL SIGNS

| Time | BP mm/Hg | Pulse /min | Resp /min | Temp F | Ht ft | Ht in | Ht cm | Wt lb | Wt kg | BMI kg/m2 | BSA m2 | O2 Sat% |
|---|---|---|---|---|---|---|---|---|---|---|---|---|
| 10:20 AM | 139/88 | 73 | | 98.70 | 6.0 | | 182.88 | 163.00 | 73.936 | 22.10 | 1.94 | |

MEASURED BY

| Time | Measured by |
|---|---|
| 10:20 AM | Barbara Browning |

## Physical Exam

| Exam | Findings | Details |
|---|---|---|
| Constitutional | * | Level of distress - moderate distress. |
| Constitutional | Normal | Well nourished. Well developed. |
| Eyes | Normal | Fundus - Right: Normal, Left: Normal. |
| Cardiovascular | Normal | Heart rate - Regular rate. Rhythm - Regular. Extremities - No edema. |
| Musculoskeletal | * | Cervical spine - muscle spasm, Range of motion: severaly reduced ROM. Lumbar spine - muscle spasm, Range of motion: mild pain w/ motion. |
| Neurological | * | Motor - Quadriparesis. Balance & gait - using a cane/ unsteady gait. Fine motor skills - past pointing. DTRs - symmetrically increased. |
| Neurological | Normal | Level of consciousness - Normal. Orientation - Normal. Memory - Normal. Cranial nerves - Cranial nerves II through XII grossly intact. Sensory - Normal. Coordination - Normal. Hand dominance - Right-handed. |

## Assessment/Plan

| # | Detail Type | Description |
|---|---|---|
| 1. | Assessment Impression | Displacement of cervical intervertebral disc without myelopathy (722.0). Causing pain mri review by my shows surgical changes spondylosis and cervical DD noted on L c-7 which might require surgery in the future, ED from cervical injury radiculitis might benefit from RF continue with meds stressed compliance for his back pain will set for ESI with Dr Sarb.. |

## Medications *(added, continued or stopped this visit)*:

| Started | Medication | Directions | Instruction | Stopped |
|---|---|---|---|---|
| 02/13/2015 | Butrans 10 mcg/hour transdermal patch | apply 1 patch by transdermal route every 7 days | | 04/14/2015 |
| 01/13/2015 | clonazepam 2 mg tablet | take 1 tablet by oral route 2 times every evening | | 04/14/2015 |
| 04/14/2015 | clonazepam 2 mg tablet | take 1 tablet by oral route 2 times every evening | | |
| 04/14/2015 | hydrocodone 10 mg-acetaminophen 325 mg tablet | take 1 Tablet by oral route every 12 hours as needed for pain | | |
| 04/14/2015 | hydrocodone 10 mg-acetaminophen 325 mg tablet | take 1 Tablet by oral route every 12 hours as needed for pain | Do not fill until 5-13-15 | |
| 04/14/2015 | hydrocodone 10 mg-acetaminophen 325 mg tablet | take 1 Tablet by oral route every 6 hours as needed for pain | Do not fill until 2-12-15 | 04/14/2015 |
| 04/14/2015 | hydrocodone 10 | take 1 Tablet by oral route | Do not fill until | |

| | | | | |
|---|---|---|---|---|
| | mg-acetaminophen 325 mg tablet | every 6 hours as needed for pain | 6-12-15 | |
| 01/13/2015 | hydrocodone 10 mg-acetaminophen 325 mg tablet | take 1 Tablet by oral route every 6 hours as needed for pain | Do not fill until 2-12-15 | 04/14/2015 |
| 01/13/2015 | hydrocodone 10 mg-acetaminophen 325 mg tablet | take 1 Tablet by oral route every 12 hours as needed for pain | Do not fill until 3-12-15 | 04/14/2015 |
| 01/13/2015 | hydrocodone 10 mg-acetaminophen 325 mg tablet | take 1 Tablet by oral route every 12 hours as needed for pain | | 04/14/2015 |
| 04/25/2013 | Lidoderm 5 % (700 mg/patch) Adhesive Patch | apply 1 patch by transdermal route every day (May wear up to 12hours.) | | |
| 02/18/2015 | promethazine 25 mg tablet | take 1 tablet by oral route every 8 hours prn nausea | | |
| 01/13/2015 | Valium 10 mg tablet | take 1 tablet by oral route every 8 hours | | |
| 10/28/2014 | Vimpat 100 mg tablet | take 1 tablet (100MG) by oral route 2 times every day | | |

*Provider: George M. Sandoz MD 04/14/2015 11:01 AM*
*Document generated by:* George Sandoz 04/14/2015 11:01 AM

**Grand Strand Spine and Neuro**
8170 Rourk Street
Myrtle Beach, SC 29572
Ph: (843) 449-2936
Fax: (843) 497-2505

Patient MRN: ----

Date: 05/15/2015

Category: Dictation

Description: Sarb dictation

Provider ID:C706AC9B-07A5-4436-9BD0-99AC04AF5CE2

Transcription Date: May 15, 2015

Victor Benjamin
DOB:
Chart:
Date: 5/15/2015
Neurology New Patient Evaluation

**HISTORY OF PRESENT ILLNESS:** Mr. Benjamin is seen in evaluation at the request of Dr. Sandoz. He has had epidurals back in November and did really well. He has a back injury related to work injury four years ago. He states a steel guard 35 feet and hit him on his head and he fell backward injuring his back. He fell on to his right side. He has disc L4-L5 with moderate facet disease, disc protrusion with moderate-to-severe recess stenosis. He did really well with his epidural for about three to four months. He has return of low back pain radiating down the right buttock on lateral aspect right to the foot with numbness. He has tried physical therapy in the past with little relief. He is using a cane. Pain is worst on the right. He does not reflex his activities of daily living. He describes it is moderately severe and did waxes and wanes depending on his activity. He still to continue his leakage worse. He would like to proceed with epidural for pain management.

**MEDICATIONS:** He is on citalopram, Vimpat, clonazepam, hydrocodone, Diovan, Norvasc.

**ALLERGIES:** Unchanged DEMEROL.

Victor Benjamin
DOB:
Chart:
Date: 5/15/2015
Page 2

PHYSICAL EXAM:
VITAL SIGNS: Blood pressure 130/74, pulse 68, temperature 98.3, and weight 167 pounds.
HEENT: Patient is normocephalic.
LUNGS: Clear.
HEART: Regular rate and rhythm. No carotid, orbital or cranial bruits.
ABDOMEN: Soft.
EXTREMITIES: Without clubbing, cyanosis or edema.

NEUROLOGICAL EXAMINATION:
MENTAL STATUS: Patient is awake, alert and oriented to person, place, and time. Speech is clear and fluent. Mentation is appropriate for age. Conversation is fluent.
CN II-XII: PERRLA. EOMI. Full visual fields with confrontation. Funduscopic exam is normal with no evidence of papilledema or hemorrhage. Spontaneous venous pulsations are seen. Facial sensation is intact to pinprick. Muscle of mastication are strong with symmetrical facial expressions. Hearing is intact to conversation. Soft palate elevated symmetrically with midline protrusion of the tongue. Gag is intact. Sternocleidomastoid and trapezius strength is symmetric.
MOTOR: Strength is 5/5 in the upper and lower extremities with normal muscle bulk and tone. There is no evidence of tremor or abnormal involuntary movement.
SENSORY: Sensation is intact to temperature, vibration and position sense. There is no truncal sensory level. The patient has decreased sensation pinprick diffusely over right leg. SLR testing mildly positive with complaint of pain in the right leg down the lateral aspect of the leg.
DTRs: 2/4 in the upper and lower extremities with downgoing plantar response.
CEREBELLAR: There is an intact finger-nose-finger, rapid alternating movements and heel-to-shin testing.
MECHANICAL SPINE: Spine is normal, no evidence of curvatures or tenderness to palpation. Negative straight leg, cross straight leg, popliteal compression, and femoral stretch.
GAIT: Antalgic.

MEDICAL DECISION MAKING: The patient with right L4-L5 radiculopathy. I recommend repeat lumbar epidural injection for pain management. He responded well to it in the past. He is on pain medicines and he has tried physical therapy in the past without relief. Risks and benefits were discussed. The patient will need transportation home and limited activity 48 hours postinjection.

Victor Benjamin
DOB:
Chart:
Date: 5/15/2015
Page 3

Barbara L. Sarb, DO

BS/fsh

Electronically Signed on 05/21/2015 10:54 AM

The End.

Barbara Sarb

# Grand Strand
HEALTH SYSTEM

## Spine & Neuro Center

PATIENT: Victor Benjamin
DATE OF BIRTH:
DATE: 07/16/2015 11:00 AM
VISIT TYPE: Office Visit
Historian: self

This 53 year old male presents for neck pain and back pain.

### History of Present Illness:

1. neck pain
   Onset: sudden. The problem is severe. The problem has worsened. The frequency of pain is daily. Location of pain is bilateral posterior neck. There is radiation of pain to the bilateral upper arm. The patient describes the pain as aching and burning. The event(s) surrounding the occurrence of the symptom include injury. Aggravating factors include exertion, hyperextension, pushing, straining, walking and working. Relieving factors include ice, injection, massage, narcotic analgesics, NSAIDs, physical therapy and standing. Associated symptoms include bladder incontinence, decreased mobility, difficulty sleeping, incoordination, loss of balance, muscle atrophy, muscle spasm, numbness, sexual dysfunction, tenderness, tingling and weakness. Pertinent negatives include bladder dysfunction not spinal related, bladder retention, bowel dysfunction not spinal related, bowel incontinence, bowel retention, dermatomic rash, dysphagia, joint pain, rash, sexual dysfunction (not spinal related) and weight loss. Additional information: feels worse unable to ambulate forlon distance causing decrease on ADL's, in bed until 3 back in bed after few hours and no relief with hydrocodone.
2. back pain
   Onset: sudden with injury. Duration: year. The problem is worsening. It occurs persistently. Location of pain is lower back. Pain is radiated to the dermatome anteriorly.The patient describes the pain as an ache, burning and throbbing. Context: trauma. Symptoms are aggravated by daily activities. Symptoms are relieved by pain meds/drugs.

### Medications (active prior to today)

| Medication Name | Sig Desc | Start Date | Stop Date | Refill | Generic |
|---|---|---|---|---|---|
| Lidoderm 5 % (700 mg/patch) Adhesive Patch | apply 1 patch by transdermal route every day (May wear up to 12hours) | 04/25/2013 | | | N |
| Valium 10 mg tablet | take 1 tablet by oral route every 8 hours | 01/13/2015 | 01/13/2015 | | N |
| promethazine 25 mg | take 1 tablet by oral route | 02/16/2015 | | | N |

| | | | | |
|---|---|---|---|---|
| tablet | every 8 hours prn nausea | | | |
| hydrocodone 10 mg-acetaminophen 325 mg tablet | take 1 Tablet by oral route every 12 hours as needed for pain | 04/14/2015 | 04/14/2015 | N |
| hydrocodone 10 mg-acetaminophen 325 mg tablet | take 1 Tablet by oral route every 12 hours as needed for pain | 04/14/2015 | 04/14/2015 | N |
| hydrocodone 10 mg-acetaminophen 325 mg tablet | take 1 Tablet by oral route every 6 hours as needed for pain | 04/14/2015 | 04/14/2015 | N |
| clonazepam 2 mg tablet | take 1 tablet by oral route 2 times every evening | 04/14/2015 | 04/14/2015 | N |
| Vimpat 100 mg tablet | take 1 tablet (100MG) by oral route 2 times every day | 04/22/2015 | 04/22/2015 | N |

## Allergies:

| Ingredient | Reaction | Medication Name | Comments |
|---|---|---|---|
| MEPERIDINE HCL | | Demerol | |

## REVIEW OF SYSTEMS

| System | Negative | Details |
|---|---|---|
| Constitutional | Negative | Weight loss. |
| ENMT | Negative | Dysphagia. |
| GI | Negative | Bowel dysfunction not spinal related, fecal incontinence and fecal retention. |
| GU | Positive | Urinary incontinence. |
| GU | Negative | Bladder dysfunction not spinal related, sexual dysfunction not spinal related and urinary retention. |
| Neuro | Positive | Incoordination, Loss of balance, Numbness, Tingling. |
| Psych | Positive | Difficulty sleeping. |
| Integumentary | Negative | Dermatomic rash and rash. |
| MS | Positive | Decreased mobility, Muscle spasms, Muscular atrophy, Musculoskeletal tenderness, Weakness. |
| MS | Negative | Joint pain. |
| Reproductive | Positive | Sexual dysfunction. |

## Physical Exam

| Exam | Findings | Details |
|---|---|---|
| Constitutional | * | Level of distress - moderate distress. |
| Constitutional | Normal | Well nourished. Well developed. |
| Cardiovascular | Normal | Heart rate - Regular rate. Rhythm - Regular. Extremities - No edema. |
| Musculoskeletal | * | Cervical spine - muscle spasm, Range of motion: severe pain w/ motion. Lumbar spine - muscle spasm, Range of motion: severely reduced ROM. |
| Neurological | * | Motor - spastic Quadriparesis. Balance & gait - spastic hemiparesis. DTRs - symmetrically increased. |
| Neurological | Comments | fluent speech |
| Neurological | Normal | Level of consciousness - Normal. Orientation - Normal. Memory - Normal. II. Optic - PERRL. III. Oculomotor - Grossly intact. IV. Trochlear - Grossly intact. V. Trigeminal - Grossly intact, Motor and reflexes: Grossly |

| | | |
|---|---|---|
| | | Intact, Sensation; Grossly Intact. VI. Abducens - Grossly Intact. VII. Facial - Grossly Intact. VIII. Acoustic - Grossly Intact. IX. Glossopharyngeal - Grossly Intact. X. Vagus - Grossly Intact. XI. Spinal accessory - Grossly Intact. XII. Hypoglossal - Grossly Intact. Sensory - Normal. Coordination - Normal. Fine motor skills - Normal. Hand dominance - Right-handed. |
| Psychiatric | * | Anhedonia. Inappropriate mood and affect - severely depressed. |
| Psychiatric | Normal | Orientation - Oriented to time, place, person & situation. Normal Insight. Normal judgment. |

## Assessment/Plan

[redacted]

1. Assessment Lumbago (724.2).

[redacted]

2. Assessment [redacted]
   Impression Causing seizure and migraine controled with meds.

[redacted]

3. Assessment Chronic pain syndrome (338.4).

[redacted]

Medications *(added, continued or stopped this visit)*:

| Started | Medication | Directions | Refill on | Stopped |
|---|---|---|---|---|
| 07/16/2015 | Cialis 10 mg tablet | take 1 tablet by oral route every day as needed | | |
| 04/14/2015 | clonazepam 2 mg tablet | take 1 tablet by oral route 2 times every evening | | |
| 04/14/2015 | hydrocodone 10 mg-acetaminophen 325 mg tablet | take 1 Tablet by oral route every 12 hours as needed for pain | | |
| 04/14/2015 | hydrocodone 10 mg-acetaminophen 325 mg tablet | take 1 Tablet by oral route every 12 hours as needed for pain | Do not fill until 5-13-15 | |
| 04/14/2015 | hydrocodone 10 mg-acetaminophen 325 mg tablet | take 1 Tablet by oral route every 8 hours as needed for pain | Do not fill until 6-12-15 | |
| 07/16/2015 | hydromorphone 4 mg tablet | take 1 tablet by oral route every 8 hours | | |
| 07/16/2015 | Lexapro 10 mg tablet | take 1 tablet by oral route every day | | |
| 04/25/2013 | Lidoderm 5 % (700 mg/patch) Adhesive Patch | apply 1 patch by transdermal route every day (May wear up to 12hours) | | |
| 07/16/2015 | oxycodone-acetaminophen 10 mg-325 mg tablet | take 1 tablet by oral route every 8 hours as needed | | |
| 02/16/2015 | promethazine 25 mg tablet | take 1 tablet by oral route every 8 hours prn nausea | | |

| | | |
|---|---|---|
| 01/13/2015 | Valium 10 mg tablet | take 1 tablet by oral route every 8 hours |
| 04/22/2015 | Vimpat 100 mg tablet | take 1 tablet (100MG) by oral route 2 times every day |

*Provider: George M. Sandoz MD 07/16/2015 12:36 PM*
*Document generated by:* George Sandoz 07/16/2015 12:36 PM

Grand Strand
HEALTH SYSTEM
Spine & Neuro Center

PATIENT: Victor Benjamin
DATE OF BIRTH:
DATE: 10/01/2015 9:00 AM
VISIT TYPE: Office Visit
Historian: self

This 53 year old male presents for neck pain.

## History of Present Illness:

1. neck pain
   Onset: sudden. The problem is severe. Duration: year. The problem has worsened. The frequency of pain is constant. Location of pain is bilateral posterior neck. There is radiation of pain to the bilateral head and bilateral upper arm. The patient describes the pain as aching and burning. The event(s) surrounding the occurrence of the symptom include injury. Aggravating factors include driving, flexion, pushing, straining, walking and working. Relieving factors include narcotic analgesics. Associated symptoms include decreased mobility, difficulty sleeping, numbness and weakness. Pertinent negatives include bladder dysfunction not spinal related, bladder incontinence, bladder retention, bowel dysfunction not spinal related, bowel incontinence, bowel retention, dermatomic rash, dysphagia, incoordination, joint pain, loss of balance, muscle atrophy, muscle spasm, rash, sexual dysfunction, sexual dysfunction (not spinal related), tenderness, tingling and weight loss.

## Medications (active prior to today)

| Medication Name | Sig/Dose | Start Date | Stop Date | Refilled | Elsewhere |
|---|---|---|---|---|---|
| Lidoderm 5 % (700 mg/patch) Adhesive Patch | apply 1 patch by transdermal route every day (May wear up to 12hours) | 04/25/2013 | | | N |
| promethazine 25 mg tablet | take 1 tablet by oral route every 8 hours prn nausea | 02/18/2015 | | | N |
| clonazepam 2 mg tablet | take 1 tablet by oral route 2 times every evening | 04/14/2015 | | 04/14/2015 | N |
| Vimpat 100 mg tablet | take 1 tablet (100MG) by oral route 2 times every day | 04/22/2015 | | 04/22/2015 | N |
| Lexapro 10 mg tablet | take 1 tablet by oral route every day | 07/16/2015 | | | N |
| oxycodone-acetaminophen 10 mg-325 mg tablet | take 1 tablet by oral route every 8 hours as needed | 07/28/2015 | 10/01/2015 | 10/01/2015 | N |

| | | | | |
|---|---|---|---|---|
| Valium 10 mg tablet | take 1 tablet by oral route every 8 hours | 07/28/2015 | 07/28/2015 | N |
| Cialis 10 mg tablet | take 1 tablet by oral route every day as needed | 07/28/2015 | 07/28/2015 | N |
| oxycodone-acetaminophen 10 mg-325 mg tablet | take 1 tablet by oral route every 8 hours as needed | 07/28/2015 | | N |
| oxycodone-acetaminophen 10 mg-325 mg tablet | take 1 tablet by oral route every 6 hours as needed | 07/28/2015 | | N |

## Medication Reconciliation

Medications reconciled today.

Allergies:

| Ingredients | Reaction | Medication Name/Comment |
|---|---|---|
| MEPERIDINE HCL | | Demerol |

REVIEW OF SYSTEMS

| System | Response | Details |
|---|---|---|
| Constitutional | Negative | Weight loss. |
| ENMT | Negative | Dysphagia. |
| GI | Negative | Bowel dysfunction not spinal related, fecal incontinence and fecal retention. |
| GU | Negative | Bladder dysfunction not spinal related, sexual dysfunction not spinal related, urinary incontinence and urinary retention. |
| Neuro | Positive | Numbness. |
| Neuro | Negative | Incoordination, loss of balance and tingling. |
| Psych | Positive | Difficulty sleeping. |
| Integumentary | Negative | Dermatomic rash and rash. |
| MS | Positive | Decreased mobility, Weakness. |
| MS | Negative | Joint pain, muscle spasms, muscular atrophy and musculoskeletal tenderness. |
| Reproductive | Negative | Sexual dysfunction. |

VITAL SIGNS

| Time | BP | Pulse | Resp | Temperature | Ht in cm | Wt in kg | Wt in lb | BMI | O2 Sat Pulse Ox |
|---|---|---|---|---|---|---|---|---|---|
| 9:17 AM | 128/87 | 61 | | 98.90 | 6.0 | 0.00 | 182.88 | 171.00 | 77.564 | 23.19 |

MEASURED BY

| Time | Measured by |
|---|---|
| 9:17 AM | Heather Small |

## Physical Exam

| Exam | Findings | Details |
|---|---|---|
| Constitutional | * | Level of distress - moderate distress. |
| Constitutional | Normal | Well nourished. Well developed. |
| Eyes | Normal | General - Right: Normal, Left: Normal. |
| Cardiovascular | Normal | Heart rate - Regular rate. Rhythm - Regular. Extremities - No edema. |
| Musculoskeletal | Normal | Cervical spine - Normal. Lumber spine - Normal. |
| Neurological | * | VIII. Acoustic - Findings: Weber test abnormal, lateralizes to the right. Motor - spastic quadriparesis. DTRs - symmetrically increased. |
| Neurological | Comments | fluent speech |
| Neurological | Normal | Level of consciousness - Normal. Orientation - Normal. Memory - Normal. II. Optic - PERRL. III. Oculomotor - Grossly intact. IV. Trochlear - Grossly intact. V. Trigeminal - Grossly intact. Motor and reflexes: Grossly intact, Sensation: Grossly intact. VI. Abducens - Grossly intact. VII. Facial - Grossly intact. IX. Glossopharyngeal - Grossly intact. X. Vagus - Grossly intact. XI. Spinal accessory - Grossly intact. XII. Hypoglossal - Grossly intact. Sensory - Normal. Balance & gait - Normal. Coordination - Normal. Fine motor skills - Normal. Hand dominance - Right-handed. |
| Psychiatric | * | Inappropriate mood and affect - depressed. |
| Psychiatric | Normal | Orientation - Oriented to time, place, person & situation. Normal insight. Normal judgment. |

## Assessment/Plan

| | | |
|---|---|---|
| 1. | Assessment | Cervical disc disorder with myelopathy of cervicothoracic region (M50.03). |
| | Impression | [illegible] |
| 2. | Assessment | [illegible] |
| | Impression | Causing dizziness seizure headache and TBI stressed compliance with meds and therapy. |

## Medications *(added, continued or stopped this visit)*:

| Added | Medication | Directions | Prescribed by | Stopped |
|---|---|---|---|---|
| 07/28/2015 | Cialis 10 mg tablet | take 1 tablet by oral route every day as needed | | |
| 04/14/2016 | clonazepam 2 mg | take 1 tablet by oral route 2 | | |

sedgwick®

# surveillance report

| | |
|---|---|
| Claim # | YYC C 51304 |
| subject | Victor G Benjamin |
| Address | 1841 Holman Road<br>Sumter, SC 29153 |
| Insured | Rexam Inc. (Rexam Beverage Can) |
| Injury | CERVICAL; HEAD INJURY; PSYCH |
| DOL | 6/15/2011 |
| DOB | |

*This assignment was worked by COVENTBRIDGE GROUP, a Sedgwick-approved vendor.*

special investigation unit

1230 E. Diehl Road • Suite 300 • Naperville IL 60563
PHONE: 630.718.6200 • FAX: 630.718.6262
Sedgwick Claims Management Services, Inc.
State license information available upon request

sedgwick.

## Assignment:

We received this assignment on June 16, 2016 to conduct three days of surveillance including one day over the July 4th holiday along with surveillance on two appointment dates. Information was supplied regarding two appointments: 6/29 at 11am at Post Trauma Resources in Columbia, SC 29201 and 7/22/16 at 10:00 am at Midlands Orthopedics & Neurosurgery in Columbia, SC 29201.

## Summary of Efforts

On Wednesday, June 29, 2016, from 6:24 am to 2:24 pm, initial surveillance was conducted at the subject's provided address located at 1841Holman Road, Sumter, SC 29153. The residence was observed as a standalone single story home with a brick exterior and a shingled roof. The residence had a large porch on the front of the residence and a deck going over and above ground pool in the back yard. Multiple vehicles were observed at the residence. A white Nissan Sport Utility vehicle, a red Chevrolet pickup truck, a white flatbed truck, and multiple older model vehicles were observed at the residence. A large green tractor was observed at the residence. The residence was located on a large corner lot. A surveillance position was established to view one of the egress/ingress routes and spot checks were conducted of the residence. The investigator later established surveillance at the subject's scheduled appointment at 1709 Hampton Street, Columbia, SC 29201. The subject arrived at the appointment in a 2005 Gray Honda van SC # 4844FV and was documented as he exited the passenger side wearing a neck brace and walking with a cane into the building. Video was also obtained as he exited the building and entered the driver's seat of the vehicle and was seen operating the vehicle and moving his head. The vehicle was followed to the residence where the subject exited the driver's door and entered the residence. No further activity was observed and surveillance for this day was discontinued.

On Sunday, July 3, 2016, from 7:38 am to 3:38 pm, initial surveillance was conducted at the subject's provided address located at 1841Holman Road, Sumter, SC 29153. The residence was observed as a standalone single story home with a brick exterior and a shingled roof. The residence had a large porch on the front of the residence and a deck going over and above ground pool in the back yard. Multiple vehicles were observed at the residence. A white Nissan Sport Utility vehicle, a red Chevrolet pickup truck, a white flatbed truck, and multiple older model vehicles were observed at the residence. A large green tractor was observed at the residence. The residence was located on a large corner lot. A surveillance position was established to view one of the egress/ingress routes and spot checks were conducted of the residence. No activity of the subject was observed.

On Friday, July 22, 2016, from 8:56 am to 4:57 pm, initial surveillance was conducted at the subject's provided appointment: 1710 Blanding Street, Columbia, SC 29201, Midlands Orthopedic. The investigator ascertained where the scheduled appointment was located and a surveillance position was established to view the Gregg Street entrance to the building, a two story brick building. At 9:45 am, the subject was observed as a passenger in the 2005 Gray Honda van SC # 4844FV. It was later observed to be parked on the opposite side of the building. The subject exited the building at 10:59 am and entered the vehicle as a passenger. Mobile surveillance was initiated and the vehicle was followed to the residence, 1841Holman Road, Sumter, SC 29153, where it parked out of sight and the subject was not observed. A surveillance

special investigation unit

sedgwick.

position was established to view one of the egress/ingress routes and spot checks were conducted. No further activity was viewed of the subject and surveillance was discontinued.

No red flag indicators were identified during this investigation

## Photos



## Preliminary Investigation

### Vehicle Ownership

We conducted a search of motor vehicle ownership and registration records in South Carolina. Through our efforts, we found the following vehicles registered to

Description: 2005 HONDA ODYSSEY - SPORT VAN
State of Origin: SOUTH CAROLINA
VIN: 5FNRL38825B033391
Registrant(s): BENJAMIN LETIA ANDERSON
Address: 1841 HOLMAN RD, SUMTER SC 29153-8387
Tag Number: 4844FV
Issue State: SOUTH CAROLINA
Latest Registration Date: 06/26/2015

special investigation unit

sedgwick.

## Property Ownership

Referencing the addresses found listed to your subject we conducted a check of property ownership records in Lee County, South Carolina. Upon contacting the Recorder of Deeds and Assessor's offices, we obtained the following information:

State: South Carolina
County: Lee
Parcel ID: 050-00-00-127-000
Property Type: Residential
Site Address: 1841 HOLMAN RD, SUMTER SC 29153-8387, LEE COUNTY

Owner Name: VICTOR G BENJAMIN
Owner Name 2: JEAN LETIA
Mailing Address: 1841 HOLMAN RD, SUMTER SC 29153-8387, LEE COUNTY
Land Value: $15,000
Building Value: $131,660

## Telephone

The provided number of (803) 428-3352 is a Farmers Tel. Co. number out of Bishopville, SC.

## General Online Inquiry

None Found

## Residential Assessment



special investigation unit

sedgwick.

# Detailed Investigation

## Physical Description

The subject is 6'00" and 165 pounds according to driver's license data. He is an African American male with very short black hair whose date of birth is April 19, 1962.

## Wednesday, June 29, 2016

*Investigator: Earl Reese*

6:24 am (Video)

Initial surveillance was conducted at the subject's provided address located at 1841Holman Road, Sumter, SC 29153. The residence was observed as a standalone single story home with a brick exterior and a shingled roof. The residence had a large porch on the front of the residence and a deck going over and above ground pool in the back yard. Multiple vehicles were observed at the residence. A white Nissan Sport Utility vehicle, a red Chevrolet pickup truck, a white flatbed truck, and multiple older model vehicles were observed at the residence. A large green tractor was observed at the residence. The residence was located on a large corner lot. A surveillance position was established to view one of the egress/ingress routes and spot checks were conducted of the residence.

## Residence Description

The residence was observed as a standalone single story home with a brick exterior and a shingled roof. The residence had a large porch on the front of the residence and a deck going over and above ground pool in the back yard.



## Directions

From Lexington, SC, head southeast on E Main St toward N Lake Dr. Continue onto US-1 N/Augusta Rd. Merge onto I-20 E via the ramp to Florence. Merge onto I-20 E. Take exit 108 toward Jamestown Rd/Manville. Turn right toward Jamestown Rd (signs for Jamestown Rd/Manville). Turn left onto Jamestown Rd. Slight right onto US-15 S. Turn left onto SC-196. Turn right onto Holman Rd. Arrive at 1841 Holman Road, Sumter, SC 29153.

special investigation unit

7:26 am (Video)
No activity was observed by the subject. Video was obtained of the area and efforts were continued.

8:24 am (Video)
No activity was observed by the subject. Video was obtained of the area and efforts were continued.

8:59 am
A phone conversation was conducted with the client who verified the appointment.

9:21 am (Video)
A spot check of the rear of the residence was conducted with no activity was observed by the subject, video was obtained of the area and efforts were continued.

9:30 am
The investigator proceeded to 1709 Hampton Street, Columbia, SC 29201, the scheduled appointment place.

10:31 am (Video)
Surveillance was established at the scheduled appointment.

10:57 am (Video)
The subject arrived at the appointment in a Gray Honda van SC # 4844FV and was videoed as he exited the passenger side wearing a neck brace and walking with a cane into the building.

11:57 am (Video)
Video was obtained as he exited the building and entered the driver's seat of the vehicle. He was wearing the neck brace and walking with the cane. He lifted the cane into the vehicle and twisted to place it in the back seat. He was seen operating the vehicle and moving his head.

1:07 pm
The vehicle was followed to the residence where the subject was observed as he exited the driver's door and entered the residence.

1:08 pm (Video)
No activity was observed by the subject. Video was obtained of the area and efforts were continued.

2:24 pm (Video)
No activity was observed by the subject. Video was obtained of the area and efforts were discontinued.

## Sunday, July 3, 2016

7:38 am (Video)
Initial surveillance was conducted at the subject's provided address located at 1841Holman Road, Sumter, SC 29153. The residence was observed as a standalone single story home with a brick exterior and a shingled roof. The residence had a large porch on the front of the residence and a deck going over and above ground pool in the back yard. Multiple vehicles were observed at the residence. A white Nissan Sport Utility vehicle, a

red Chevrolet pickup truck, a white flatbed truck, and multiple older model vehicles were observed at the residence. A large green tractor was observed at the residence. The residence was located on a large corner lot. A surveillance position was established to view one of the egress/ingress routes and spot checks were conducted of the residence.

8:38 am (Video)
No activity was observed by the subject. Video was obtained of the area and efforts were continued.

9:38 am (Video)
No activity was observed by the subject. Video was obtained of the area and efforts were continued.

10:38 am (Video)
A spot check of the residence was conducted and no activity was observed by the subject, video was obtained of the area and efforts were continued.

11:37 am (Video)
No activity was observed by the subject. Video was obtained of the area and efforts were continued.

12:38 pm (Video)
No activity was observed by the subject. Video was obtained of the area and efforts were continued.

1:38 pm (Video)
A spot check of the residence was conducted and no activity was observed by the subject, video was obtained of the area and efforts were continued.

2:38 pm (Video)
No activity was observed by the subject. Video was obtained of the area and efforts were continued.

3:38 pm (Video)
No activity was observed by the subject. Video was obtained of the area and efforts were discontinued.

## Friday, July 22, 2016

8:56 am (Video)
Initial surveillance was conducted at the subject's provided appointment: 1710 Blanding Street, Columbia, SC 29201, Midlands Orthopedic. The investigator ascertained where the scheduled appointment was located and a surveillance position was established to view the Gregg Street entrance to the building, a two story brick building.

9:45 am
The subject was observed as a passenger in the silver Honda van SC # 4844FV as he arrived at the scheduled appointment.

sedgwick.

10:01 am (Video)
No activity was observed by the subject. Video was obtained of the area and efforts were continued.

10:04 am (Video)
The vehicle was located on the opposite side of the building and a new surveillance position was established.

10:57 am (Video)
No activity was observed by the subject. Video was obtained of the area and efforts were continued.

10:59 am (Intermittent Video)
The subject exited the building, entered the vehicle as a passenger and the vehicle departed the area and mobile surveillance was initiated.

12:12 pm (Video)
The vehicle arrived at the residence, 1841Holman Road, Sumter, SC 29153 and parked out of sight and the subject was not observed. A surveillance position to vie an egress/ingress route was established.

1:12 pm (Video)
No activity was observed by the subject. Video was obtained of the area and efforts were continued.

2:13 pm (Video)
No activity was observed by the subject. Video was obtained of the area and efforts were continued.

3:12 pm (Video)
No activity was observed by the subject. Video was obtained of the area and efforts were continued.

4:12 pm (Video)
No activity was observed by the subject. Video was obtained of the area and efforts were continued.

4:57 pm (Video)
No activity was observed by the subject. Video was obtained of the area and efforts were discontinued.

*Sedgwick SIU investigators make reasonable efforts to positively identify the Subject without compromising the confidential nature of the investigation. We certify that any surveillance video and report are a true and accurate representation of the details of the investigation. Notwithstanding Sedgwick SIU's best efforts, there may be occasions where someone other than the intended Subject is documented. It is important that you review any video to ensure the subject depicted is in fact the intended Subject.*

special investigation unit

South Carolina Workers' Compensation Commission
1333 Main Street, Suite 500 • Post Office Box 1715
Columbia, South Carolina 29202-1715
(803) 737-5723 www.wcc.sc.gov

| | |
|---|---|
| WCC File #: | 1106789 |
| Carrier File #: | YYC51304 |
| Carrier Code #: | |
| Employer FEIN #: | |

Claimant's Name: Victor Benjamin SSN: - -
Address: 1841 Holman Road
City: Sumter State: SC Zip: 29153
Home Phone: (803) 428-3352 Work Phone: ( ) -
Preparer's Name: Jeff Chandler Law Firm: Chandler Law Firm

Employer's Name: Rexam Beverage Can Company D/B/A Rexam Beverages
Address: 609 Ceasar Street
City: Bishopville State: SC Zip: 29010
Insurance Carrier:
Preparer's Phone #: (843) 448-4357

## REQUEST FOR COMMISSION REVIEW

Request for Commission Review by ☒ claimant ☐ employer (check one) Date of injury: 06/15/11

The undersigned makes application for review of the findings of the Commissioner in the above-captioned case. The request for review is based on the following grounds: (State the grounds of your appeal in the form of questions presented. Each question presented must contain a concise statement of one proposition of law or fact. Refer to evidence by title and exhibit number. Use additional pages if necessary).

**See Attached Grounds For Review**

(Check one) Oral argument ☒ is ☐ is not requested. Appellant's request for oral argument is waived if not indicated on this form.

I certify that I have served this document pursuant to R.67-211 by delivering a copy to Jason Lockhart, Esq.

Name

PO Box 12519, Columbia, SC 29211

Address

on the 3rd day of August, 2017 by ☒ first class mail ☐ personal service ☐ certified mail.

Jeff C. Chandler

Preparer's Signature Attorney For Claimant Title August 3, 2017 Date

Check this box if you are not represented by an attorney. ☐

If the claimant appeals and is representing himself or herself, the Judicial Department will prepare the additional copies of this form and serve this form on the opposing party. R.67-701B. Otherwise, file the original and four copies of this form with the Judicial Department. The appeal must be postmarked no later than 14 days from the date of service of the Hearing Commissioner's decision. R.67-701 and R.67-205. Attach the filing fee to this form. Attach a Form 32 if you are unable to pay the filing fee. Refer to R.67-701 through R.67-711 for additional information.

Victor Benjamin
WCC File No: 1106789

Date of Accident 6/15/11

(Continuation from Form 30)

**GROUNDS FOR REVIEW**

1.) Did the Hearing Commissioner err in her Finding of Fact #5 when she determined that the Claimant failed to meet his burden of proving entitlement to lifetime benefits on the basis of "incomplete paraplegia"; said error being that the greater weight of the evidence supports a finding of fact and conclusion of law that the Claimant does meet the definition of having suffered an incomplete spinal cord injury and thus incomplete paraplegia/quadriplegia which would entitle him to lifetime benefits and to not find otherwise was an abuse of discretion.

2.) Did the Hearing Commissioner err in her Finding of Fact #8 when she determined that the opinion of Dr. Lozanne should be afforded greater weight than that of the other authorized medical experts and other duly qualified medical experts; said error being that the greater weight of the evidence supports a finding of fact and conclusion of law that (3) board certified physicians opined that the Claimant DOES SUFFER from INCOMPLETE QUADRIPLEGIA and to not find otherwise was an abuse of discretion.

3.) Did the Hearing Commissioner err in her Finding of Fact #13 when she determined that the Claimant failed to meet his burden of proving entitlement to lifetime benefits on the basis of having sustained permanent and severe physical brain damage; said error being that the greater weight of the evidence supports a finding of fact and conclusion of law that the only authorized neurologist, Dr. George Sandoz, did in fact opine that the Claimant had suffered permanent physical brain damage; the severity of which rendered the Claimant incapable of returning to any form of gainful employment and suffering with chronic headaches, Epilepsy, PTSD and Dementia for which he was issued a 54% whole person permanent impairment rating and to not find otherwise was an abuse of discretion.

4.) Did the Hearing Commissioner err in her Finding of Fact #14 when she determined the Claimant failed to meet his burden of proving a compensable lower back injury with resulting radiculopathy; said error being that the greater weight of the evidence supports a finding of fact and conclusion of law that the Claimant did sustain an injury to his lower back and to not find otherwise was an abuse of discretion.

5.) Did the Hearing Commissioner err in her Finding of Fact #19 and Finding of Fact #20 when she determined that the Claimant was not entitled to the mobility scooter ordered by Dr. Sandoz; said error being that the greater weight of the evidence supports a finding of fact and conclusion of law that the need for the mobility scooter was directly correlated to the spinal cord injury for which all doctors acknowledged contributed to the gait and balance disorders of the Claimant and to not find otherwise was an abuse of discretion.

6. Did the Hearing Commissioner err in her Conclusion of Law #10 when she determined that the Claimant failed to meet his burden of proving entitlement to lifetime benefits on the basis of "incomplete paraplegia"; said error being that the greater weight of the evidence supports a finding of fact and conclusion of law that the Claimant does meet the definition of having suffered an incomplete spinal cord injury and thus incomplete paraplegia/quadriplegia which would entitle him to lifetime benefits and to not find otherwise was an abuse of discretion.

7. Did the Hearing Commissioner err in her Concusion of Law # 14 when she determined that the opinion of Dr. Lozanne should be afforded greater weight than that of the other authorized medical experts and other duly qualified medical experts; said error being that the greater weight of the evidence supports a finding of fact and conclusion of law that (3) board certified physicians opined that the Claimant DOES SUFFER from INCOMPLETE QUADRIPLEGIA and to not find otherwise was an abuse of discretion.

8. Did the Hearing Commissioner err in her Conclusion of Law #15 when she determined that the Claimant failed to meet his burden of proving entitlement to lifetime benefits on the basis of having sustained permanent and severe physical brain damage; said error being that the greater weight of the evidence supports a finding of fact and conclusion of law that the only authorized neurologist, Dr. George Sandoz, did in fact opine that the Claimant had suffered permanent physical brain damage; the severity of which rendered the Claimant incapable of returning to any form of gainful employment and suffering with chronic headaches, Epilepsy, PTSD and Dementia for which he was issued a 54% whole person permanent impairment rating and to not find otherwise was an abuse of discretion.

9. Did the Hearing Commissioner err in her Conclusion of Law #18 when she determined the Claimant failed to meet his burden of proving a compensable lower back injury with resulting radiculopathy; said error being that the greater weight of the evidence supports a finding of fact and conclusion of law that the Claimant did sustain an injury to his lower back and to not find otherwise was an abuse of discretion.

10. Did the Hearing Commissioner err in her Conclusion of Law #23 and # 24 when she determined that the Claimant was not entitled to the mobility scooter ordered by Dr. Sandoz; said error being that the greater weight of the evidence supports a finding of fact and conclusion of law that the need for the mobility scooter was directly correlated to the spinal cord injury for which all doctors acknowledged contributed to the gait and balance disorders of the Claimant and to not find otherwise was an abuse of discretion.

SOUTH CAROLINA WORKERS' COMPENSATION COMMISSION

W.C.C. FILE NO: 1106789

| | |
|---|---|
| VICTOR G. BENJAMIN,<br><br>Employee,<br><br>Claimant,<br><br>vs.<br><br>REXAM, INC.,<br><br>Employer,<br><br>AND<br><br>SEDGWICK CLAIMS MANAGEMENT SERVICES, INC.,<br><br>Carrier,<br><br>Defendants. | **CLAIMANTS/APPELLANTS' BRIEF TO FULL COMMISSION** |

## BACKGROUND

The Claimant began his employment with the Defendant as an equipment operator in 1982 and was still an equipment operator when he sustained injuries to his brain, spine, right shoulder, right upper extremity, left shoulder and psychological overlay in a compensable on the job accident on June 15, 2011.

The Claimant was injured when a piece of equipment broke causing a metal object to dislodge and struck the Claimant in his skull and other parts of his body. The Claimant was diagnosed initially with a comminuted skull fracture in the left parietal covexity with minimal depressed bone with some bone projecting toward the soft tissue. He was further diagnosed in

the emergency room with right forearm tendon lacerations that required surgical repair. Following his discharge from the initial hospitalization, Mr. Benjamin was diagnosed with a host of other injuries and conditions causally related to his June 2011 work injury. Of particular importance to the matter before the Full Commission is the injury to the cervical spine and brain. Mr. Benjamin was initially being treated for his cervical spine and brain injuries by Neurologist, Dr. George Sandoz. This authorized treating physician directed all of the initial medical management and diagnostic care of the Claimant and presently is still the authorized physician treating the claimant for his brain injury and chronic pain. Dr. Sandoz wrote a referral for the Claimant to be evaluated by Southeastern Spine Institute in October 2012. Instead of honoring this referral, the Defendants sent the Claimant to be evaluated by Dr. Eugene Giddens. The Claimant paid for an IME with Dr. Steven Poletti which was performed on November 5, 2012. Dr. Poletti opined that the Claimant sustained a C3-4 spinal cord contusion with resulting myelomalacia, necessitating a posterior cervical decompression with fusion at C3-4. The Defendants refused to agree to allow Dr. Poletti to treat the Claimant and the Claimant was evaluated by Dr. Eugene Giddens on November 21, 2012. Dr. Giddens also noted signal change in the cord at C3-4 but determined that the Claimant would require a C3-C6 anterior cervical discectomy and fusion. The Claimant didn't feel comfortable with Dr. Giddens performing a surgery on him and the Defendants selected Dr. Karl Lozanne to evaluate and treat the Claimant. Dr. Lozanne first evaluated the Claimant on January 22, 2013, and noted that the Claimant sustained injury to his spinal cord at C3-4 from the trauma at work but believed that the levels C4-C7 would benefit from an anterior cervical discectomy and fusion. The Claimant agreed to receive the surgery suggested by Dr. Lozanne and it was performed on February 18, 2013. The Claimant continued to complain of worsening neck and extremity symptoms following this surgery and the authorized neurologist, Dr. George Sandoz ordered a repeat cervical spine MRI which was denied by the Defendants. The Claimant sent a letter to Dr. Lozanne requesting that he order an MRI of the Claimants cervical spine which he declined to do. In November

of 2013, Dr. Lozanne indicated that he believed the Claimant would benefit from takeover of care by a pain management specialist and recommended an FCE for February 2014 which would coincide with his likely MMI designation at the one year surgery follow up. The Claimant returned to Dr. Poletti on January 20, 2014. Dr. Poletti ordered an immediate cervical MRI scan and determined that it revealed edema changes in the spinal canal at the C3-4 level and progressive stenosis at the C3-4 level. Dr. Poletti indicated that an FCE would be absolutely contraindicated and that posterior decompression, laminectomy and fusion at the C3-4 level was indicated. The Claimant sent a written request to Defendants counsel requesting authorization of surgery and on February 3, 2014, Defense counsel responded in writing indicating that the Defendants would not agree to a transfer of care to Dr. Poletti as Dr. Lozanne had yet to place the Claimant at MMI.

The Claimant underwent surgery by Dr. Poletti on February 14, 2014, and filed a Form 50 on February 19, 2014, requesting reimbursement of the medical care performed and transfer of care to Dr. Poletti. A hearing was scheduled before Commissioner Barden on June 23, 2014. In an Order filed September 17, 2014, the Commissioner issued 34 Findings of Fact and found that the Claimant was not entitled to the relief he requested on his Form 50. The Claimant timely filed an appeal of the Commissioner's Order. An Appellate Panel Review was held on February 24, 2015 and the Full Commission affirmed the Decision and Order on April 23, 2015.

A Form 50 was filed on May 9, 2016 wherein the Claimant sought lifetime compensation on the basis that he suffered both physical brain damage and incomplete quadriplegia. A hearing was scheduled before Commissioner Taylor on August 18, 2016 and she filed her Order on July 21, 2017 in which she issued (27) Findings of Fact ultimately determining that the Claimant failed to meet his burden of proving lifetime benefits under the Act pursuant to Section 42-9-10(C).

## ISSUES ON APPEAL

1. Was it factual and legal error for the Commissioner to find that the Claimant failed to

prove that he is entitled to lifetime benefits related to his spinal cord injury for which he was diagnosed with suffering from incomplete quadriplegia, pursuant to §42-9-10 (C) and Reed- Richards v. Clemson University, 37 S.C. 304, 638 S.E. 2D 77 (S.C. App. 2007) ?

2. Was it factual and legal error for the Commissioner to find that the Claimant failed to prove that he suffered permanent and severe physical brain damage as contemplated by §42-9-10 (C) ?

3. Was it factual and legal error for the Commissioner to deny the Claimant his entitlement to a mobility scooter when it was prescribed by the authorized treating physician for his spinal cord injury?

## DISCUSSION

1. THE COMISSIONER COMMITTED ERROR IN FINDING THAT THE CLAIMANT FAILED TO PROVE THAT HE IS ENTITLED TO LIFETIME BENEFITS RELATED TO HIS SPINAL CORD INJURY DESPITE HIS DIAGNOSIS OF INCOMPLETE QUADRIPLEGIA, PURSUANT TO §42-9-10 (C) AND REED- RICHARDS V. CLEMSON UNIVERSITY, 37 S.C. 304, 638 S.E. 2D 77 (S.C. App. 2007)

The Claimant suffered a severe spinal cord injury. This spinal cord injury was documented on multiple MRI studies and will continue to be seen on imaging studies in the future (Deposition of Dr. Karl Lozanne Defendants APA #34 p. 939) This spinal cord injury has resulted in edema changes in the cord itself otherwise referred to as spinal cord signal change. This spinal cord signal change according to Dr. Lozanne is also referred to as myelomalacia. This is a process upon which the spinal cord sustains an injury and atrophy or shrinking of the spinal cord occurs and is visible on diagnostic studies. Dr. Lozanne further describes that when you conduct a physical examination on someone and you determine that abnormal function of the spinal cord exists, that this condition is known as myelopathy. (Deposition of Dr. Karl Lozanne Defendants APA#34 p. 935) Dr. Lozanne has testified that Victor Benjamin has myelomalacia and suffers from myelopathy. A central issue in dispute in this case stems from the description of the Claimants' spinal cord injury. Two orthopedic spine surgeons and a neurologist have opined that the Claimant suffers from a condition known as "incomplete

quadriplegia". Dr. Steven Poletti has authored an opinion which describes the Claimant as having sustained a "catastrophic neurological injury" and that he suffers from "incomplete quadriplegia". He documents that the Claimant has signs and symptoms of upper and lower extremity weakness and that this neurological injury prevents the Claimant from walking normally due his altered gait and imbalance and that he has lost the digital dexterity in his hands. Dr. Poletti issued a permanent medical impairment rating of 67% to the whole person of which 39% was attributed to the injury to the spinal cord itself and 28% attributed to his 4 level fusion. He further opines that the Claimant is obviously permanently disabled from returning to any type of employment due to his injuries. (Claimant APA #10 p.564-565) Dr. George Sandoz, a neurologist, has been the authorized treating physician of the Claimant since 2011. He authored an opinion which labeled the Claimant as suffering from "incomplete quadriplegia" as evidenced by the injury to his spinal cord and the supporting symptoms of progressive loss of use of his upper extremities and the inability to ambulate normally requiring use of a four prong cane for stabilization and balance. (APA #12 p.612) His physical examination of the Claimant routinely charts the deficits in reflexes in both the upper and lower extremities. From the condition of incomplete quadriplegia, Dr. Sandoz has determined that the Claimant is incapable of returning to any form gainful employment. Dr. Sandoz has repeatedly issued an order for a mobility scooter specifically due to the spinal cord injury. (APA #5 p.182) (APA #12 p. 614, 616, 619, 622, 626) Additionally, Dr. Sandoz has charted the Claimant reported symptoms of urinary dsyfunction and erectile dysfunction and provided medication management for the symptoms. Dr. William Mills, a board certified orthopedic spine surgeon, saw the Claimant for an IME and reviewed all of the available medical records and diagnostic testing. In addition, he performed a physical examination of the Claimant. He authored an opinion that he agreed with the determination held by both Dr. Poletti and Dr. Sandoz in that he too believed that the Claimant suffered from "incomplete quadriplegia" and that he agreed with the medical impairment ratings issued by both doctors. (APA #14 p.636-637) The only

doctor to take exception to the description or diagnosis of "incomplete quadriplegia" is Dr. Karl Lozanne. He testified that he wasn't trained to use the phrase "incomplete quadriplegia" in his neurosurgery training and he believed that this is all a matter of semantics regarding use of that phrase to describe the diagnosis. He testified that the Claimant "most definitely sustained a spinal cord injury" and that he sustained an "incomplete spinal cord injury". (Defendants APA #35 p.947) However, in spite of the testimony of Dr. Lozanne, it is well known in the medical community that the term "incomplete paraplegia/quadriplegia" is utilized. In 1994, the American Spinal Cord Injury Association, Standards of Neurological Classifications of Spinal Injury began using "Incomplete paraplegia" as a term. This term was derived from the classifications of spinal cord injuries which were complete or partial. However, in describing partial spinal cord injuries, the term incomplete paraplegia was used. At that point, a correlation between incomplete paraplegia and the ASIA scale was made in the medical literature. The fact that Dr. Lozanne doesn't use or refuses to use the words "incomplete quadriplegia" should not be the focus of this Commission. The focus should be on what he acknowledges to agree with. He agrees that the Claimant has a spinal cord injury as evidenced by the signal change in the spinal cord known as myelomalacia. He acknowledges that this injury to the cord is something you will continue to see diagnostically indefinitely. He agrees the dysfunction to the spinal cord known as myelopathy is present in the Claimant and manifested by a constellation of symptoms to include the loss of normal function of both his upper and lower extremities. This is just a " matter of semantics". (Deposition of Dr. Karl Lozanne APA #35 p.947) In Reed-Richards, the Court held, "the commission and the circuit court correctly interpreted the term "paraplegic" to include a diagnosis of "incomplete paraplegia". This interpretation, though consistent with the legislative purpose of construing workers' compensation laws in favor of claimants, does not rise to the level of judicial legislation. There was no need for the legislature to specify that a claimant can recover lifetime benefits based on a diagnosis of incomplete paraplegia if the claimant is totally and permanently

disabled as a result of this condition." Reed- Richards v. Clemson University, 37 S.C. 304, 638 S.E. 2D 77 (S.C. App. 2007) Unlike the Claimant in Reed-Richards, the Claimant in the instant case had full use and function of his upper and lower extremities prior to his work injury. In Reed-Richards, the Claimant had a 27 year history of back, bladder and bowel problems to include (3) spinal surgeries which pre-dated her injury with Clemson University. Three months into her job, she tripped and sustained an aggravation of her long standing pre-existing conditions. Dr. David Shallcross, a pain management doctor, utimately concluded that the Claimant had a diagnosis of "incomplete paraplegia" due to T-12 fracture. Interesting to point out, she suffered from a T-11/T-12 fracture dating back to 1973 which was a result of a motor vehicle accident which set her poor health history into motion. The Claimant in the instant case, was frankly the picture of health at the time of his work injury. He had worked for the Defendant for approximately 28 years and had no physical impediment. He was a fit and strapping man that was a primary wage earner for his family and even had a tow truck business that he worked during his time away from his primary job. He now has physical limitations which impact the use and function of his upper and lower extremities. He has chronic pain. He has balance and mobility issues that require the use of cane. Due to ongoing falls and difficulty with his upper extremities and continued difficulties with his legs a motorized scooter or wheelchair has been prescribed. He continues to suffer from loss of bladder function and erectile dysfunction. Victor Benjamin is a man that deserves an award for lifetime benefits due to his spinal cord injury. The medical evidence supports his entitlement to this award and the law supports his award. This is not a "substantial evidence case". This is a case of a Commissioner misinterpreting the testimony of Dr. Lozanne and/or misapplying the standard for the award of lifetime benefits in a spinal cord injury case. Dr. Lozanne has acknowledged that the Claimant has sustained a spinal cord injury that is permanent and that he has dysfunction of his spinal cord due to the injury. He only disagrees with the term used by all of the doctors involved, when the condition is referred to as "incomplete quadriplegia". Just because

he doesn't use the term in his clinical practice and because he was never trained to use it doesn't make the diagnosis any less valid or real. It is a real diagnosis with the ASIA having used it in their medical literature since at least 1994. Three (3) board certified physicians who are well known to this Commission have concluded that Victor Benjamin has "incomplete quadriplegia".

The Claimant requests that the Full Commission reverse the Commissioner's findings of fact and conclusions of law which indicate that he failed to meet his burden of proof under §42-9-10 (C) and award him lifetime benefits.

2. THE COMMISSIONER COMMITTED ERROR WHEN SHE DETERMINED THAT THE CLAIMANT FAILED TO SUSTAIN HIS BURDEN OF PROVING THAT HE SUFFERED FROM PERMANENT AND SEVERE PHYSICAL BRAIN DAMAGE CONSISTENT WITH §42-9-10 (C).

The Claimant was injured June 15, 2011 at Rexam Beverage Can Company when a machine malfunctioned and a metal object became dislodged violently striking the Claimant in his skull and other body parts. The Claimant lost consciousness and was taken to the Emergency Room in Florence, SC. A CT scan of his brain revealed that he had a comminuted fracture of his skull in the left parietal convexity with minimal depressed bone with additional bone projected toward the soft tissue. (APA #18 p. 660) He was anesthetic to the events of the accident, he had a headache and he was experiencing dizziness. Following discharge from the hospital he was followed by Dr. William Naso for two office visits. Due to his ongoing postconcussive symptoms, an MRI of the brain was ordered. The MRI of 6/27/11 revealed what the radiologist revealed to be evidence of prior left parietal craniotomy. Dr. Naso saw the Claimant for his final outpatient visit on 8/3/11 wherein he documented the continued complaints of headaches and short-term memory issues. At this point, the workers' compensation carrier elected to have the Claimant evaluated and treated by Dr. George Sandoz, a neurologist, in Myrtle Beach, SC. Dr. Sandoz first encountered the Claimant on 9/16/11 and charted symptoms of confusion, headache, incoordination, irritability, loss of consciousness, memory difficulty, personality

change, restlessness, speech difficulty, stiff neck, unusual behavior, visual disturbance and weakness. Dr. Sandoz ordered a brain MRI; neuropsych testing and a trial of Lamictal for a moodstabilizer. He also ordered a nystagmogram due to symptoms of inner ear damage. An MRI of the brain dated 10/10/11 revealed that there was metal artifact in the left parietal skull secondary to craniotomy. (APA #5 p.91) Concurrently, the Claimant was evaluated and treated by Dr. Leonard Goldschmidt, a neuropsychologist. Dr. Goldschmidt diagnosed the Claimant with Dementia and closed head traumatic brain injury. Psychological counseling sessions were provided under the guidance of Dr. Goldschmidt and Dr. Nick Spring from October 2011 until June of 2012 at which time the Defendants unilaterally decided to remove the Claimant from the care of these treating doctors and authorized Dr. Roger Deal and Dr. Lawrence Bergmann of Post Trauma Resources in Columbia, SC. Meanwhile, Dr. Sandoz continued to document and manage all of the signs and symptoms of the Claimant's brain injury. On 2/2/12, Dr. Sandoz documented that the Claimant presented with dizziness and loss of consciousness. The dizziness was described as a severe imbalance that included a feeling of spinning. Due to a description of "jerking movements" and possible alteration of consciousness, an EEG was ordered to evaluate possible seizure activity. An EEG of 2/22/12 revealed that the Claimant was suffering from focal seizures with secondary generalization. The context of the seizure includes traumatic brain injury. (APA #5 p. 112) As a result of the diagnosis of epilepsy which the doctor directly related to the TBI, the Claimant was started on Keppra 500mg 2x daily. Additionally, he was prescribed Fioricet and Ultracet for his migraine headaches and neck pain. He has been taking Clonazepam under the direction of Dr. Sandoz and Dr. Deal for unrelenting insomnia and anxiety. He suffers with PTSD related to the accident and has been on various medications over the years in an attempt to control his symptoms.

Dr. Sandoz in a letter dated 6/19/15, issued the Claimant a 4% impairment of the whole person for his chronic headaches, for his traumatic brain injury a 29% whole person impairment rating and for seizures a 34% whole person impairment for a combined 54% whole person impairment rating. (APA

#5 p.173) On 12/16/15, Dr. Sandoz authored a letter indicating that "after careful review of all of the relevant diagnostic imaging and testing as well as physical examination of Mr. Benjamin, I hold the opinion that he has suffered physical brain damage the severity of which renders him incapable of returning to any form of gainful employment. The physical brain damage has left Mr. Benjamin with chronic headaches, Epilepsy, PTSD and Dementia." This opinion was given to a reasonable degree of medical certainty. (APA #12 p.612)

Dr. Robert Brabham, a licensed psychologist and former director of the brain injury division of South Carolina Department of Disability and Special Needs indicates that he holds the opinion that the evidence in this case supports the contention that there is physical brain damage in this case. It is evidenced by the well documented symptoms of headache, confusion, dizziness, blurred vision, ringing in the ears, ease of fatigue, change in sleep patterns, behavioral or mood changes, memory problems, trouble with concentration and attention, onset of seizures, and numbness and loss of physical coordination. He believes that cognitive problems, emotional problems and sensory problems are all present and well documented in the case of the Claimant. Dr. Brabham holds the opinion that the Claimant is vocationally disabled.

In 2013, the South Carolina Supreme Court issued two landmark opinions addressing "physical brain damage" in workers' compensation cases. In Sparks , the Court held "we conclude that 'physical brain damage' as used in §42-9-10 (C ) is physical brain damage that is both permanent and severe." Sparks v. Palmetto Hardwood, Inc. 406 S.C. 124, 750 S.E. 2D 61 (S.C. 2013). In Crisp , the Court further explained that entitlement to lifetime compensation was predicated on "brain damage so severe that the person could not subsequently return to suitable gainful employment." Crisp v. SouthCo., Inc. , 401 S.C. 627, 738 S.E.2d 835 (S.C. 2013)

Under the Crisp and Sparks standard, it is clear that the evidence at maximum medical improvement supports that the Claimant has suffered physical brain damage that is both permanent and

severe. Victor Benjamin was hit in the head by a steel piece of machinery that fractured his skull. This was confirmed by both CT scans and MRI. Since then, he has suffered from proven cognitive deficits, balance problems, dizziness, seizures, mood disorders, and difficulty with complex tasks - resulting in permanent and total disability. Dr. Sandoz (treating neurologist); Dr. Goldschmidt (treating neuropsychologist); Dr. Bergmann ( licensed professional counselor) and Dr. Brabham (psychologist and certified brain injury specialist) confirm the presence of the cognitive deficits. Dr. Sandoz has repeatedly and explicitly stated to a reasonable degree of medical certainty that the Claimant is permanently disabled due to traumatic brain injury resulting in physical brain damage. The evidence of physical brain damage is overwhelming.

The Hearing Commissioner cited (5) primary reasons as the basis for her denial of life-time benefits. First, she cites the three brain scans as support for her decision. She doesn't tell us specifically what it is about the scans that weigh into her decision making. However, we know from the evidence cited throughout the APA record that the Claimant had verifiable findings of a skull fracture and craniotomy shown on both CT scans and an MRI and that he had seizures as verified by EEG testing. Even had the Claimant not had a verifiable skull fracture visible on imaging studies or seizures as proven by EEG testing, that should not be persuasive evidence to disprove a brain damage case. In fact this has been addressed by our Courts. In Sparks , the court held, "The Supreme Court would decline to impose a requirement that physical damage, as required to award life-time benefits for totally disabled claimants suffering physical brain damage, must be proved through an "objective diagnostic medium", since some indisputably physical brain damage may not be revealed by diagnostic instruments that can detect only relatively gross physical abnormalities." It would be an error of law for the Hearing Commissioner to impose a requirement that Mr. Benjamins' physical brain damage be proven by "objective diagnostic medium". Further, this is akin to what happened in the case of Burnette. The court indicated that "particularly disturbing is the finding that the 2008 MRI showed

"only a 'minimal' protrusion with no nerve root displacement or impingement, and comparatively, no greater pathology of any significance (if any) than the MRI of 2004." Because no evidence indicates this opinion originated from a medical provider, yet it appears in the single commissioner's order, we are forced to conclude it is the medical opinion of the single commissioner, adopted by the Commission." Burnette v. City of Greenville , 401 S.C. 417, 737 S.E.2d 200 (Ct. App. 2012). Based upon this decision, to satisfy the "substantial evidence" standard the Defendants have an affirmative obligation to address the evidence submitted by the Claimant, especially when the medical evidence comes from a medical expert. Accordingly, the Defendants should have either (1) deposed the claimant's medical experts, or (2) obtained an Independent Medical Exam to ensure that substantial evidence exists to support the Defendants position. The Defendants did neither in the instant case. The opinion of Dr. Sandoz is unrefuted. It is the only medical opinion in the record regarding physical brain damage. Although medical evidence "is entitled to great respect", the Commission is not bound by the opinions of medical experts and may disregard medical evidence in favor of other competent evidence in the record. Potter v. Spartanburg Sch. Dist. 7 , 395 S.C. 17, S.E.2d 123 (Ct. App. 2011) However, " while a finding of fact of the Commission will normally be upheld, such a finding may not be based upon surmise, conjecture, or speculation, but must be founded on evidence of sufficient substance to afford a reasonable basis for it." Edwards v. Pettit Constr. Co., Inc. , 273 S.C. 576, 257 S.E.2d 754 (1979); see also Grayson v. Carter Rhoad Furniture 317 S.C. 306, 454 S.E.2d 320 (1995) (affirming reversal of Commission's decision, which was supported by no evidence in the record). As to the Hearing Commissioners 2nd, 3rd and 4th contention to support her denial of life-time benefits, they simply have no bearing on whether the Claimant can prove his case of permanent physical brain damage. Appearing and participating in a deposition or a hearing does not negate the permanency or severity of his injury. Our Courts do not suggest that a person suffering from physical brain damage only be represented by a Guardian ad Litem at a Hearing. Nor does the law require that the individual

be bedridden 24 hours a day or drooling from their mouth wearing a helmet. Is that the standard this Commission wishes to impose? The Claimant attends the great majority of all medical appointments with his spouse by his side and has occasionally gone to counseling sessions without her attendance due to her work schedule. However, this is not indicative in any way as to whether one has physical brain damage. No doctor has opined that the fact that the Claimant attended an appointment by himself had any bearing on the diagnosis rendered or their conclusion that he was incapable of returning to the workplace. Finally, the Commissioner indicated that she based her decision on the "lack of any medical evidence stated to a reasonable degree of medical certainty that the Claimant sustained brain damage that was permanent and severe. Again, this is refuted by the following: Dr. Sandoz in a letter dated 6/19/15, issued the Claimant a 4% impairment of the whole person for his chronic headaches, for his traumatic brain injury a 29% whole person impairment rating and for seizures a 34% whole person impairment for a combined 54% whole person impairment rating. (APA #5 p.173) On 12/16/15, Dr. Sandoz authored a letter indicating that "after careful review of all of the relevant diagnostic imaging and testing as well as physical examination of Mr. Benjamin, I hold the opinion that he has suffered physical brain damage the severity of which renders him incapable of returning to any form of gainful employment. The physical brain damage has left Mr. Benjamin with chronic headaches, Epilepsy, PTSD and Dementia." This opinion was given to a reasonable degree of medical certainty. (APA #12 p.612)

Again, the Claimant has permanent physical brain damage as indicated by the authorized treating neurologist. His diagnosis of epilepsy and dementia both attributed to the brain damage are permanent conditions. You can't wave a magic wand and make them go away. While his epileptic seizures are presently controlled by medication, it doesn't negate the permanent nature of the underlying condition. Likewise, dementia has no cure. No medications have been shown to prevent or cure dementia. (Rafii, M.S. Aisen, P.S. (2009) "Recent developments in Alzheimer's disease

therapeutics". (BMC medicine 7:1-4). Medications may be used to treat the behavioural and cognitive symptoms but have no effect on the underlying disease process. (Lleo A, Greenberg SM, Growdon JH (2006). "Current pharmacotherapy for Alzheimer's disease". Annu. Rev. Med. 57 (1):513-33. Dementia is a progressive and terminal illness. (Mitchell, Susan L. (2009) " The Clinical Course of Advanced Dementia." (N Engl J Med) and (Sachs, Greg A. (2009) "Dying from Dementia" (N Engl J Med). Additionally, the 54% whole person impairment rating attributed to the brain injury is a significant permanent impairment. " A permanent impairment, by definition, lasts for a lifetime." James v. Anne's Inc. 390 S.C. 188, 701 S.E.2d 730 (2010).

The Claimant has met his burden under Crisp and Sparks and pursuant to §42-9-10 (C) and requests that the Full Commission reverse the Single Commissioner and award him lifetime benefits for permanent physical brain damage.

3. THE COMMISSIONER COMMITTED ERROR WHEN SHE DETERMINED THAT THE CLAIMANT FAILED TO MEET HIS BURDEN OF PROVING THE MOBILITY SCOOTER ORDERED BY DR. SANDOZ WAS CAUSALLY RELATED TO HIS SPINAL CORD INJURY.

There is overwhelming evidence in the record to support causation of the Claimants' need and entitlement to the mobility scooter ordered by the authorized treating doctor. No credible or reliable evidence suggests otherwise. The Claimant has had documented issues with difficulty with ambulation and imbalance dating back to his first office visit with Dr. Sandoz in September 2011. There is a consistent papertrail of these complaints for 6 solid years. Dr. Sandoz clearly indicates in his medical records that the reason for the referral is tied to the cervical spine injury. It is not vague or ambiguous. Dr. Sandoz has repeatedly issued an order for a mobility scooter specifically due to the spinal cord injury. (APA #5 p.182) (APA #12 p. 614, 616, 619, 622, 626) The Commissioner is speculating as to the reason for why the mobility scooter was ordered for the Claimant and again running afoul of the decision set forth in Burnette. In fact, the doctor whom she gives the greatest weight to, concerning

medical opinions, has documented the Claimant's gait disorder and imbalance since his first encounter with the Claimant. (APA #11, p.586) Further, following his cervical spine fusion of the Claimant, he ordered the Claimant be sent home with a four wheel walker, associated with his persistant imbalance. (APA #11 p.596) Again, in May of 2013 due to the Claimant reporting episodes of feeling that his legs are going to give out, for which the doctor attributes to elevated reflexes as a manifestation of his myelopathy, a 4-point cane was prescribed. (APA #11 p. 598) Further, Dr. Lozanne makes it crystal clear from his perspective that the persistance of generalized imbalance suffered by the Claimant is a direct manifestation of his spinal cord injury. (APA #11 p. 610) Additional evidence supporting the complaints of the Claimant are recorded in the physical therapy records and detailed throughout the records of Dr. Poletti.

The Claimant has met his burden under §42-15-60 and request that the Hearing Commissioner be reversed and that he be provided with the mobility scooter to assist with his ambulation.

## CONCLUSION

The Claimant believes he has met his burden of proof under §42-9-10 (C) for both his claim of incomplete quadriplegia and permanent physical brain damage. In addition pursuant to §42-15-60, the Claimant believes the evidence is without refute that his need for the mobility scooter is directly and causally related to his spinal cord injury and should be awarded as a medical benefit accordingly. As such, the Claimant request that the Full Commission issue an Order finding the Claimant is entitled to the relief he requested on his Form 50 for lifetime benefits due to suffering from "incomplete quadriplegia" and for suffering from permanent physical brain damage for which each condition has rendered him incapable of returning to gainful employment and reversing the Commissioner in Full.

Respectfully submitted,



Jeff C. Chandler
Chandler Law Firm
Bank of America Building
2501 Oak Street
Myrtle Beach, SC 29578
(843)448-4357
Attorney for the Claimant/Appellant

September 20, 2017

**In The Matter Of:**

*Victor G. Benjamin*

*Rexam, Inc.*

RECEIVED
APR 0 2 2012
Per_____

---

Victor G. Benjamin
March 02, 2012



---

*Ryan P. Alderman, Alderman Court Reporting*
*T: 843-254-2675 E: RPA1277@AOL.COM*
*500 Oak Pond Court, Conway, SC 29526*
*Working in association with Milligan Court Reporting*
*T: 843-971-5867 E: Milligansc@comcast.net*

COPY

Original File Benjamin-3-2-2012.prn
**Min-U-Script® with Word Index**

SOUTH CAROLINA
WORKERS' COMPENSATION COMMISSION
W.C.C. #1106789

VICTOR G. BENJAMIN,

Claimant,

vs.

REXAM, INC.,

Employer-Insurer.

DEPOSITION OF VICTOR G. BENJAMIN

DATE TAKEN: March 2, 2012

TIME BEGAN: 11:09 a.m.

TIME ENDED: 12:18 p.m.

LOCATION: Chandler Law Firm
2501 Oak Street
Myrtle Beach, SC 29578-1889

REPORTED BY: Ryan P. Alderman
Court Reporter
Notary Public for South Carolina

RYAN P. ALDERMAN
Independent Court Reporter working in association with
Milligan Court Reporting
Telephone: 843-971-5867 Fax: 843-917-6509
E-mail: Milliganscc@comcast.net



INDEX

PAGE
Examination by Ms. Hyatt.....04
Examination by Mr. Chandler.....56
Reexamination by Ms. Hyatt.....60
Certificate.....62
Exhibits:
(No exhibits introduced.)



*Any court, party, or person who has purchased a transcript may, without paying a further fee to the reporter, reproduce a copy or portion thereof as an exhibit pursuant to court order or rule or for internal use, but shall NOT otherwise provide or sell a copy or copies to any other party or person.

APPEARANCES:

Jeff C. Chandler, Esquire
Chandler Law Firm
2501 Oak Street
Myrtle Beach, SC 29578-1889

.....On behalf of the Claimant

Mary Margaret S. Hyatt, Esquire
McAngus Goudelock & Courie, LLC
2411 North Oak Street
Myrtle Beach, SC 29577-3173

.....On behalf of the Defendant

ALSO ATTENDING: Shayna Rasmussen

STIPULATIONS: The within deposition was taken pursuant to the South Carolina Rules of Civil Procedure.

WAIVER: Examination and reading of the deposition are waived by the witness and by the parties.



Victor G. Benjamin, being duly sworn, testified as follows:

EXAMINATION BY MS. HYATT:

Q. Will you please state your full name for the record.

A. Victor Benjamin.

Q. Do you have a middle name?

A. Yes.

Q. What is that?

A. Gleen.

Q. Is that G-L-E- -- E-N-N or just --

A. They spell it G-L-E-E-N, Gleen, for some reason. That's the way it is on my birth cert -- but I always spell it G-L-E-N.

Q. Okay. I'm Mary Margaret Hyatt. I represent Rexam Beverage Can Company and their insurance carrier in your workers' compensation claim. I'm going to ask you a series of questions today. If you don't understand my question, will you please ask me to rephrase it?

A. Okay.

Q. Otherwise, if you answer my questions as I ask them, we'll assume that you understood it; is that okay?

A. Okay.

Page 13

1 Q. And what do they do there?
2 A. They make yarn as well -- I mean, cloth. I'm
3 sorry, cloth.
4 Q. What was your job there?
5 A. I was a pin draft operator, a pin frame operator.
6 Q. And how long did you work with Reed's Brothers?
7 A. I'm thinking about a year, and I got laid off.
8 Q. Did you work anywhere before that?
9 A. I worked during the summer, a place called
10 Springs.
11 Q. Springs?
12 A. Yeah, Springs. And that's in, let me see, in
13 Lancaster.
14 Q. And what did you do there?
15 A. Oh, boy, I, I was dealing with yarn. I can't
16 remember exactly what it was.
17 Q. And how long did you work there?
18 A. It was less than a year I'm thinking.
19 Q. Did you work anywhere before Springs?
20 A. No.
21 Q. Did you ever work in the welding industry?
22 A. No, I didn't.
23 Q. So you never used that certificate?
24 A. No, I didn't.
25 Q. Any other types of work that you've performed?

Page 14

1 A. I, I have a towing -- excuse me. I have a towing
2 business.
3 Q. Is that your own business?
4 A. Yes, ma'am.
5 Q. Is that located in Bishopville -- I mean, in
6 Sumter? Sorry.
7 A. Yeah.
8 Q. And what's the name of your business?
9 A. Benjamin and Son Towing.
10 Q. And how long have you had that business?
11 A. Eight to ten years.
12 Q. Do you still own that business?
13 A. Yes.
14 Q. Are you still towing cars --
15 A. No, I --
16 Q. -- or vehicles?
17 A. No, I don't.
18 Q. Why not?
19 A. Well, it was a part-time job. I just got my own
20 truck and all that. And my son basically -- if
21 anything had to be done, my son would do it.
22 Q. Has it always been like that?
23 A. My son and I together when he became of age to
24 drive. I couldn't do it because it's, it's not a
25 full -- because I work a full-time job.

Page 15

1 Q. Okay. When's the last time you towed a vehicle
2 through that business?
3 A. I think my son towed one a couple of weeks ago.
4 Q. You did?
5 A. My son.
6 Q. Your son. What about you personally?
7 A. My personal self?
8 Q. Yes, sir.
9 A. Sometime the early part of last year.
10 Q. Early part of 2011?
11 A. Yes.
12 Q. And you -- were you with your son a couple weeks
13 ago when he towed a car?
14 A. Was I with him?
15 Q. Yes, sir.
16 A. Yes, I was just sitting in the truck.
17 Q. Do y'all tow for like repo businesses or --
18 A. No, if someone call, like a friend or something
19 want to move a car, something like that. But not
20 every day, no.
21 Q. All right. Any other types of work?
22 A. No.
23 Q. What was your job at Rexam?
24 A. I was a cupper operator, cupper operator.
25 Q. Copper operator?

Page 16

1 A. Yes.
2 Q. And what did you do as a copper operator?
3 A. What, what they call as a front-end maintainer,
4 but I operate the cupper, and my job was to load
5 coils on a -- on a coil -- on a coil cot. And we
6 have bricks, what they call aluminum bricks, yay
7 long, yay wide, and we, we have to lift them and
8 put them on a pallet. That was the scrap that
9 coming off the -- from the front end there. That
10 will constantly make scraps.
11 And that machine, what they call a baler
12 room, would constantly make bricks. We have to go
13 in there and stack those bricks on a pallet about
14 four high. And when that pallet get full, we have
15 to bring that pallet up, and then we take it and
16 put it in the storage area there where it's
17 supposed to be at.
18 And with the cupper, I would have to check
19 cups, have to maintain the machine, make sure it
20 stays running at all time, look at the cups, make
21 sure it's not making bad cups, have to do checks
22 on the cups, have to do computer checks, and stuff
23 like that.
24 Q. And the coils were -- those were aluminum coils?
25 A. Aluminum coils, yes.

Page 17

1 Q. And when do you – how much did the coils weigh?
2 A. Nineteen thousand pounds.
3 Q. Did you use some sort of crane or something to – .
4 A. Yeah, you use a forklift, use a forklift, to
5 drive – to lift the coils with.
6 Q. Okay. And when they were on the pallet, was that
7 the – all the coils together on the pallet that
8 weighed 19,000 pounds?
9 A. No, it's just one coil.
10 Q. Okay. What about when you put them on the pallet?
11 A. We don't put them on a pallet, put them on a coil
12 cot, –
13 Q. Oh, okay.
14 A. – coil cot. You load it on the coil cot and get
15 it ready, prep it, so when the coil chains come up
16 that coil be ready to go on the end of
17 the – the end of the uncoiler and be – once I
18 put it on the uncoiler, then I prep and get it
19 ready. So whenever we do the coil chains, be
20 ready to run back through the machine, have to
21 turn the coil around.
22 Q. And when you put that, all the coil – when you
23 put it in the machine, is that when you use the
24 forklift, to put it in?
25 A. No, we use the forklift to lift it on the coil

Page 18

1 cot; and then once it go from the coil cot, we
2 lift it up on what they call the uncoiler, and
3 then it runs through the machine. We have to –
4 two guys will be in the back back there, run it
5 through a lubricator, one be on each side to run
6 it through the lubricator.
7 And then they – then I be at the – at the
8 control panel there. And once they push it
9 through, get so much fed through the machine, then
10 we jog it 'til we get all the – all of the, the
11 scrap, excess scrap, out the way. And then we
12 stop running the machine.
13 Q. And how many pounds did your job require you to
14 lift?
15 A. By hand?
16 Q. Yes, sir.
17 A. To be honest with you, ma'am, I never weigh one of
18 those bricks. Sometimes, sometimes we have a
19 problem with the baler. A brick might come out
20 that long, and then we have to get – I have to
21 get someone to help me lift it because then I'm
22 putting that hoist in there where you can lift the
23 bricks.
24 But it's – but you're doing your job, and
25 your production – it's so aggravating lifting

Page 19

1 with the hoist because – it's kind of aggravating
2 lifting with the hoist because it kind of puts you
3 behind really, –
4 Q. With a –
5 A. – trying to keep up with your job.
6 Q. That's with a hoist?
7 A. An, an electric hoist and control it by hand, with
8 two button operation.
9. Q. All right. Did you always have that same job at
10 Rexam?
11 A. No, I didn't.
12 Q. That was the job that you were working –
13 A. Yeah.
14 Q. – on June 15th of 2011?
15 A. Yes, ma'am.
16 Q. What other jobs have you had there?
17 A. Before I went to that job, I had a job – what
18 they call a printer. I was a printer operator,
19 print the labels on the can. I did that. And
20 before that, I was the inspector.
21 Q. And just for the record, what does Rexam make?
22 A. We make aluminum cans, soda cans.
23 Q. And are those for Pepsi and Coke?
24 A. Pepsi, Coke, all different kind.
25 Q. Okay. Any other jobs other than the three you've

Page 20

1 just told us about –
2 A. No, ma'am.
3 Q. – while at Rexam?
4 A. No, ma'am.
5 Q. And we're here about an accident that occurred on
6 June 15th of 2011. Will you describe what
7 happened?
8 A. I don't know what happened.
9 Q. You don't –
10 A. All I was going, what, what was told to me.
11 Q. What's the last thing you remember from that day?
12 A. The last thing I remember, me and my son walked
13 into work together that day because he was working
14 out there for summer, for the summer. And we
15 talked to the secretary. He was talking with the
16 sec – secretary on the way in. And that was
17 pretty much it.
18 Q. So you – the last thing you remember is walking
19 into –
20 A. Walking in –
21 Q. – the plant?
22 A. – the plant, talking to the secretary. I spoke
23 to her, and then she talked to him for a few
24 minutes, and I went on in and clocked in.
25 Q. And do you recall going to the machine that you

Page 21

1 worked that day?
2 A. I recall running the machine, but what happened I
3 don't remember.
4 Q. Do you recall how long -- excuse me, how long you
5 had been working when the accident occurred?
6 A. Do I recall how long it was --
7 Q. How long you had been working that day when the
8 accident occurred.
9 A. No, I don't recall. The only thing I know, it was
10 late at night when this accident happened.
11 Because when I came back through, I remember this
12 young lady being over me telling me it's going to
13 be okay, and I didn't know what she was talking
14 about. And I noticed a lot -- our job have a lot
15 of noise in there.
16 The next thing I know I must have went back
17 out again, and I was in, in the back of the
18 ambulance on a stretcher, and I remember my son
19 being at the back of the ambulance. And I asked
20 him -- I said son, what are you doing here. What
21 are you doing at this time of night. And he said
22 daddy, we came to work together. And that's what
23 helped me remember that, you know, we was working
24 there together.
25 Then I remember seeing the plant manager, and

Page 22

1 I asked him what are you doing at this time of
2 night because I know it was dark. I said what are
3 you doing at this time of night, and I forgot
4 exactly what he said. He said I cut some kind of
5 joke to him or something. Then the next thing I
6 know I was in the back of the ambulance. Like I
7 say, I was in the back of the ambulance. They was
8 rolling me in the ambulance.
9 And it seemed like they asked me where I want
10 to go to. For some reason I told them McLeods,
11 but I normally go to Carolina Hospital. You know,
12 that's where I was always go if anything happen.
13 And it seemed like we backed up all the way to
14 Florence. I don't know.
15 Q. Is your son that was working there -- is that the
16 19 year old?
17 A. Yes, ma'am.
18 Q. And what's his name?
19 A. His name is Leman Benjamin.
20 Q. Spell his first name for me.
21 A. L-E-M-A-N.
22 Q. Does he still work there?
23 A. No, he doesn't.
24 Q. What was your normal shift?
25 A. 7:00 to 7:00 at night, 4 days on and 4 days off.

Page 23

1 Q. Okay. 7:00 --
2 A. 7:00 p.m. to 7:00 a.m., at night, 12 hour shifts.
3 Q. And that was the shift you were working on July
4 15th of 2011?
5 A. Excuse me?
6 Q. That was the shift that you were working on
7 July -- I'm sorry, June 15th, 2011?
8 A. Yes, ma'am.
9 Q. And did the -- you said the ambulance took you to
10 McLeod?
11 A. Yes, ma'am.
12 Q. And do you recall arriving at McLeod?
13 A. Yes, ma'am.
14 Q. And what happened there?
15 A. They took me to the -- to the back and did some
16 work on me.
17 Q. Do you recall what kind of problems you were
18 having when you got to McLeod?
19 A. I know my arm was cut open real bad.
20 Q. That's your right arm?
21 A. My right arm was cut open real bad.
22 Q. And what else?
23 A. Then they stitched -- they gave me a needle and
24 stitched it up.
25 Q. Was that on your forearm?

Page 24

1 A. No, right through here.
2 Q. Right there, okay. That looks like -- is that a
3 scar right there?
4 A. Yes, it was -- it was cut through here. I think
5 when they did the surgery on me, I think they went
6 up there and cut there, and they cut back here.
7 Q. Okay. That one --
8 MS. HYATT: Does that look like about five
9 inches --
10 MS. RASMUSSEN: Uh-huh.
11 MS. HYATT: -- going across the arm?
12 BY MS. HYATT:
13 Q. And then this one down the arm is the surgical
14 scar you think? And it kind of looks --
15 A. Yeah.
16 Q. -- like it goes over there, too.
17 A. Yes, the surgical scar thing.
18 Q. Okay.
19 A. And they -- I know they cut me there because I
20 don't think that was there. The only thing I --
21 the only thing that was there was this right here.
22 Q. Okay.
23 A. Thank you.
24 Q. The surgical scar, --
25 A. Excuse me. Oh, okay, we got a picture --

Page 29

1 Q. Is somebody treating you for the neck?
2 A. Dr. Sandoz.
3 Q. Okay. How did you end up getting to Dr. Sandoz?
4 A. My wife brings me every time I have to come.
5 Q. Well, I mean, did you get referred to him by
6 someone?
7 A. Yes.
8 Q. Who referred you to Dr. Sandoz?
9 A. I think my caseworker.
10 Q. And were you referred to him for the neck pain
11 that you were having?
12 A. Neck and head.
13 Q. Okay. You said you were having headaches?
14 A. Yes.
15 Q. Tell me, how often do you have headaches?
16 A. The headaches probably -- I'm having headaches
17 every day, and they goes and come. They may last
18 30 minutes to an hour.
19 Q. Do you take anything for them?
20 A. I'm taking the Vicodin.
21 Q. Anything else?
22 A. Not for headaches, no. They had me on some more
23 medicine; and when they first gave me that
24 medicine, it, it had me out. It was -- because
25 I'm not used to taking medicine. I mean, it made

Page 30

1 me sick as a dog, and so I called them back.
2 Q. Where do you experience the headaches? What part
3 of your head do you have them in?
4 A. I have them over here. I have them down --
5 Q. That was the right temple area?
6 A. Yes, ma'am.
7 Q. And where else?
8 A. On the left side sometimes, right down through
9 here.
10 Q. Okay. Sort of the left side?
11 A. Yeah, right there where, where I got the lick in
12 my head. Yeah.
13 Q. Okay. And Dr. Sandoz is providing treatment for
14 the headaches?
15 A. Yes, ma'am.
16 Q. Have you been experiencing the headaches the whole
17 time?
18 A. Headaches and ringing in my ears.
19 Q. Since the accident occurred?
20 A. Yes, ma'am.
21 Q. And what about the ringing in your ears? Do
22 you -- do you experience that all the time?
23 A. Constantly, all the time.
24 Q. Have you ever had any prior problems with ringing
25 in your ears?

Page 31

1 A. No, ma'am.
2 Q. What about headaches; have you ever had prior
3 problems with those?
4 A. No, ma'am.
5 Q. And the neck pain that you're experiencing, you
6 described it as running down the right side?
7 A. Yes, ma'am.
8 Q. And down the shoulder and into the right arm?
9 A. Yes, ma'am.
10 Q. Have you ever had problems with that before?
11 A. No, ma'am.
12 Q. What about neck pain in general; any prior
13 problems with neck pain?
14 A. No, ma'am.
15 Q. What other problems are you having as a result of
16 this accident?
17 A. My wife tells me that I shakes at night while we
18 in bed, having bad dreams and stuff.
19 Q. And do you recall having bad dreams?
20 A. Do I recall it? Yes, ma'am.
21 Q. You do?
22 A. Yes, ma'am.
23 Q. Do you have problems during the day?
24 A. I be depressed sometimes during the day.
25 Q. And describe for me what you mean by being

Page 32

1 depressed.
2 A. You know, when you're used to doing for yourself
3 and you got to get someone else to do something
4 for you or you got to wait for somebody to do
5 something for you when you always don't have to
6 depend on no one, an independent person, and --
7 you got to wait for someone to do something for
8 you, it's very depressing, very depressing. I
9 mean, I be sad sometime because whatever happened
10 to me. Sometimes I'm having the pain, having
11 these pains, and it just go -- I just go to
12 thinking about whatever happened to me with me
13 going through this.
14 Financial burdens because my bills and
15 stuff. I've been thinking my check going to come
16 one day. It may come two or three days later
17 and -- because I like to try to pay my bills on
18 time, and it gets stressful.
19 Q. And is that why you're seeing Dr. Goldschmidt?
20 A. For depression?
21 Q. Yes, sir.
22 A. Yes, ma'am.
23 Q. How did you end up --
24 A. Dr. Springs.
25 Q. I'm sorry?

Page 45

1 A. Yes, ma'am.
2 Q. Are you still on medication for that?
3 A. Yes, ma'am.
4 Q. Were you taking medication for high blood pressure
5 when this accident occurred?
6 A. Yes, ma'am.
7 Q. Any other health problems that you've had?
8 A. I have taken cholesterol medicine as well.
9 Q. Are you still taking that medication?
10 A. Yes, ma'am, I'm taking blood pressure and
11 cholesterol.
12 Q. And are -- is the cholesterol medicine also
13 prescribed by Dr. Daniels?
14 A. It's through his office because Dr. Daniel is not
15 there a lot. It's through his office, yes, ma'am.
16 Q. Okay. Any other problems you're having as a
17 result of this accident?
18 A. Not that I can think of.
19 Q. To your knowledge, are you having any problems
20 with your brain?
21 A. To my knowledge?
22 Q. Yes, sir.
23 A. Yes, ma'am.
24 Q. And tell me about that.
25 A. Sometimes -- I get loss of thought sometimes in a

Page 46

1 conversation.
2 Q. Can you give me an example?
3 A. If I'm maybe -- let's see, if I'm in a -- let's
4 say if I'm talking to you let's say about a house,
5 whatever, I might lose my train of thought and,
6 and forget what I'm talking about; and then I
7 might ask you the question what was I saying,
8 something like that, lose my train of thought.
9 Q. How often does that happen?
10 A. It's hard to say.
11 Q. Any other problems?
12 A. I think -- at this time, I think that's it.
13 Q. And are the right arm problems that were put on
14 the Form 50 -- are that -- are those the problems
15 you've already told me about?
16 A. Say that again.
17 Q. The right -- your right arm problems, have we
18 already covered all of those?
19 A. Yes, ma'am.
20 Q. What about your right shoulder; have we covered
21 that already, the problems you're having with it?
22 A. Have we cover it?
23 Q. Have we talked about it?
24 A. I thought we did.
25 Q. And that's the pain that comes from the neck --

Page 47

1 A. Yes, ma'am.
2 Q. -- through the right shoulder? Is there anything
3 else other than that?
4 A. No, ma'am.
5 Q. Are you having any problems with your left
6 shoulder?
7 A. I'm having problem with -- they told me I got
8 carpal tunnel in my -- in my left arm as well, my
9 left wrist, whatever. They gave me brace for
10 that.
11 Q. And is that Dr. Sandoz?
12 A. Yes.
13 Q. But are you having any problems with your left
14 shoulder?
15 A. I'm not having problems in my left shoulder, no,
16 ma'am.
17 Q. What about any problems other than the neck, like
18 the lower back or anything like that?
19 A. It hurts sometime but nothing out of the ordinary
20 I wouldn't think.
21 Q. And have you ever had any prior problems with your
22 left arm?
23 A. No, ma'am.
24 Q. Have you ever had any prior problems with your low
25 back?

Page 48

1 A. Yes, I have.
2 Q. When was that?
3 A. That's probably back in the '80s or '90s.
4 Q. And what was that related to?
5 A. They told me I had a deteriorating disc back
6 there.
7 Q. But you're not having anything other than
8 occasional pains since this accident?
9 A. No, ma'am.
10 Q. Were you having occasional pains before this
11 accident in your low back?
12 A. Repeat that one.
13 Q. Were you having occasional pains in your low back
14 before this accident?
15 A. Occasionally, yes, ma'am.
16 Q. Is anything different since this accident with
17 respect to the low back?
18 A. No, ma'am.
19 Q. I can't remember if I asked you this or not: Any
20 prior problems with your right arm before this
21 accident?
22 A. No, ma'am.
23 Q. Any prior problems with your right shoulder before
24 this accident?
25 A. I've had years ago -- I'm going to have to explain

Page 49

1 this to you, now. I had a -- I broke my left
2 ankle. I think that was in 2006. When I broke my
3 left ankle, they gave me crutches to use; and
4 after I got my ankle straightened out, I had a
5 problem with my right shoulder then.
6 And the doctor that -- whoever took Dr.
7 Welsch -- I mean, the doctor before Dr. Welsch --
8 I was seeing an orth -- orthopedic doctor there.
9 Whoever Dr. Welsch -- Dr. Welsch took another
10 doctor place that was there. Anyway, I forgot the
11 doctor name. He gave me a shot in that shoulder;
12 and after he gave me a shot in the shoulder right
13 between -- it was two bones there. He gave me a
14 shot right between the two bones.
15 And from that day, it might would hurt just a
16 little bit, but I didn't have any problems prior
17 to the accident up until I had the accident.
18 Q. Okay.
19 A. But up until then, I was good.
20 Q. Have you ever had any prior problems with
21 depression or any kind of psychological problems?
22 A. No, ma'am.
23 Q. Have you ever had any problems in the past with
24 drug abuse or, or use of drugs?
25 A. No, ma'am.

Page 50

1 Q. What about any prior problems with pain medication
2 abuse or addictions?
3 A. No, ma'am. Excuse me.
4 Q. Are you having any problems performing your daily
5 activities since this accident?
6 A. Daily activity?
7 Q. Yes, sir.
8 A. As whatcha mean?
9 Q. You know, what you did before during the day that
10 you're not able to do now or you're having trouble
11 to do now.
12 A. I mean, I don't work. That was part of my daily
13 activity.
14 Q. Any other problems?
15 A. I mean, I just sit around -- basically just sit
16 around the house.
17 Q. That's what you do now or before?
18 A. No, now. No, before I worked.
19 Q. Did you have any hobbies before?
20 A. Racing, watching races, racetrack --
21 Q. Watching racing?
22 A. Yes, ma'am.
23 Q. Did you actually race cars?
24 A. No, ma'am.
25 Q. So do you still watch races now?

Page 51

1 A. I haven't been to a race in awhile, no, ma'am.
2 Q. You actually went to the races?
3 A. I used to, yes.
4 Q. Any other hobbies?
5 A. No.
6 Q. Do you feel like you're capable of returning to
7 work?
8 A. Well, at this time I don't.
9 Q. Why is that?
10 A. Because I'm not healthy enough. I feel like I'm
11 not healthy enough. I, I know I can't lift like I
12 used to. I don't have the strength that I used to
13 have. And being around people and -- I don't know
14 how I would act -- how I would react going back to
15 my job as far as around that machine again that --
16 where I had the accident from. I don't know if
17 I'd go into a panic attack or, or what.
18 Because it -- just thinking about the
19 accident, what happened to me and, and seeing the
20 situation that I went through, it really took a
21 lot out of me. I mean, I don't know.
22 Q. Do you have some sort of like disfigurement on
23 your head or --
24 A. Yes, ma'am.
25 Q. Show me where.

Page 52

1 A. It's right there.
2 Q. Along --
3 A. It, it --
4 Q. -- the left top side of your head?
5 A. Yes, ma'am. You can see a line that runs right
6 through there. And if my hair was cut, it'd look
7 normal; but when you feel it, you can feel a knot.
8 It's still there.
9 Q. Okay.
10 A. Yes, ma'am.
11 Q. I don't really see one --
12 A. Well, you don't see the -- you don't see the line
13 there?
14 Q. No, I can see the line.
15 A. You can see the line. But I'm saying you -- no,
16 you can't see the knot.
17 Q. I can't see the bumps, I guess.
18 A. No, you can't see the bump; but if you run your
19 hand across it, --
20 Q. Uh-huh.
21 A. -- you can feel the bump is there. Yeah.
22 Q. Did they tell you what that was the result of?
23 A. From the accident. That's, that's all I know. It
24 was worse than that. It went down some. But I
25 don't know -- I don't know if it ever -- it been

BEFORE THE SOUTH CAROLINA
WORKERS' COMPENSATION COMMISSION
W.C.C. FILE NO. 1106789

Victor G. Benjamin,

Employee,
Claimant,

vs.

Rexam, Inc.,

Employer,

and

Sedgwick Claims Management Services, Inc.,

Carrier,
Defendants.

# THE DEPOSITION OF VICTOR G. BENJAMIN

Monday, March 31, 2014
11:04 a.m. – 12:00 p.m.

The deposition of VICTOR G. BENJAMIN, taken on behalf of the Employer/Carrier, was taken before Sharon B. Brock at the Chandler Law Firm, located at 2501 Oak Street, Bank of America Building, Myrtle Beach, South Carolina, on Monday, March 31, 2014.





## APPEARANCES:

FOR THE EMPLOYEE/CLAIMANT:
Jeff C. Chandler, Esquire
CHANDLER LAW FIRM
2501 Oak Street, Bank of America Building
Post Office Drawer 1889
Myrtle Beach, South Carolina 29577

FOR THE EMPLOYER/CARRIER:
Jason W. Lookhart, Esquire
MCANGUS, GOODELOCK & COURIE, LLC
1320 Main Street, 10th Floor
Post Office Box 12519, Capitol Station
Columbia, South Carolina 29211

COURT REPORTER:
Sharon B. Brock





## INDEX

EXAMINATION OF WITNESS: PAGE

VICTOR G. BENJAMIN

Examination by Mr. Lookhart..... 5
Certificate of Court Reporter..... 57

## EXHIBITS

(No exhibits were marked during this proceeding.)





## STIPULATIONS

Pursuant to the Notice and/or consent of the parties, the deposition herein captioned was conducted at the time and place mentioned before Sharon B. Brock, a Notary Public and Verbatim Court Reporter in and for the State of South Carolina.

The deposition was taken for use in accordance to the South Carolina Rules of Civil Procedure unless herein stipulated and agreed to by the parties.

The reading and signing of the deposition by the deponent was waived by the deponent.

asked me the medicine?

Q: Yes, sir. What was he doing to try to help you with your problems? He gave you medicine, did he do anything else?

A: He gave -- I'm trying to think. He gave me medicine. At one time he, he put something on my head to check my head, to check my brain, and he updated the Hypercodone (phonetically spelled), and sometime when I go down to see him, he have a test for me to do to check my head and I don't know what the tests are for, but he would, he would check my head with some kind of -- put something on my head and check my head.

Q: Do you know when you're supposed to go back to see him again?

A: Sometime, I'm thinking sometime this month. I don't know exactly when. He gave me a card and the card is at the house. I don't know exactly when.

Q: Do you know if he has, within the last six months, sent you out or referred you to any other doctors at all, Dr. ---

A: The last -- in the last six months?





Q: Yes, sir.

A: Not as I can remember.

Q: And you're supposed to go back to see him soon, you think?

A: Yes, sir.

Q: Who else are you seeing right now besides Dr. Sandoz for your work-related injuries?

A: I am seeing Dr. Bergman out of Columbia and also Dr. Dasl.

Q: They both are at the same place, correct?

A: Yes, they are.

Q: How frequently are you seeing the two of them?

A: I see Dr. Bergman every week.

Q: When you go and see Dr. Bergman, and I've got a copy of your records from there, so I'm not going to ask you about every visit, but when you go to see him, does he sit down with you, like we're talking, and give you counseling; is that what he does for you?

A: Yes, he does.

Q: How have you found that to be? Have you found it to be helpful? Have you found





it to have had any impact on your condition?

A: Yes, I have. He, he, he said I'm doing a whole lot better than I was when I first came there.

Q: Do you feel as though Dr. Bergman is being receptive to your concerns in trying to help you with your condition?

A: Very much.

Q: When did you last see him?

A: I can't remember was it last Tuesday or last Wednesday. I can't remember. It was one of those days, because I have to see him every week.

Q: When you saw him last week, what type of problems, what type of complaints did you provide to him as far as your condition was concerned?

A: I was complaining about these panics attack. On my way over there, I had a panic attack, so he asked me, "Do you know what caused the panic attack, what, what happened?"

I said, "Doc, I was just riding along, and all of a sudden, I just had a





panic attack." I say, "Nothing triggered it."

He say, "Ain't nothing triggered it?"

I said, "Doc, there was nothing triggered it, I was just doing my normal routine, just driving." Because my wife, she have to work, and so right there to Columbia, you know, I make that trip myself, unless she's off from work.

Q: So you were driving to see Dr. Bergman when you had the panic attack?

A: Yes, I did, and it was like my heart was right -- it, it scared me to death.

Q: When you go and see him, do y'all spend an hour together, two hours together? How long do y'all typically spend with one another?

A: Basically, a hour.

Q: I assume that when he saw you last week, you had your neck brace on, so he was aware that you had surgery ---

A: Yes, sir.

Q: --- last month?

A: Yes, sir.

Q: Now, Dr. Deal is in the same office?
A: Yes, sir.
Q: Correct?
A: Yes, sir.
Q: How often do you see Dr. Deal?
A: I see Dr. Deal probably once to twice a month.
Q: When was the last time you would've seen Dr. Deal?
A: I can't remember. It was some, it was sometime last month. I can't remember when it was.
Q: Is he prescribing medication to you to help you with your condition?
A: Yes, he is.
Q: Does he provide you with counseling as well or is that more something that Dr. Deal does?
A: Both of them provide me with counseling.
Q: The medications that Dr. Deal is giving to you, have you found those to be helpful to your condition?
A: Well, sometime it does and sometime it doesn't, but basically, it does. It works, it works both ways.





Q: Are the medications that Dr. Deal prescribes to you, are those medications that you take every day or do you only take them when you have ---
A: No, sir. Those, those medications, if I don't take that medication, I can sit up for twenty-four hours, seven days a week. That's no lie.
Q: If you don't ---
A: If I don't -- if I do not take that medication, I will stay up for twenty-four hours, seven days a week. That's no lie. I would not get no sleep at all. He tried and tried 'til he finally got something to work.
Q: So overtime, Dr. Deal has changed your medicine, tried different medications to help you?
A: Until he finally found one that will work the best for me so far.
Q: As far as Dr. Deal is concerned, do you think like he's trying to help you?
A: Ain't no doubt, he's very concerned about me.
Q: Do you feel like that he listens to you





when you go there?
A: Yes, sir, he definitely, he definitely listen.
Q: You mentioned a few moments ago that when you last saw Dr. Bergman you had a panic attack while you were driving to see him, and then you mentioned that sometimes your wife goes with you. How often do you drive to Dr. Bergman's appointments alone and how often do you go with your wife?
A: If my wife is off that day, she drives me. It's hard for me to keep up with her schedule, because if she work a Saturday, if my appointment is on a Tuesday, if she's off that day, so I can't say exactly what day she goes and what day she don't go. If she's off that day, she definitely going to go -- she's definitely going with me, if she's off.
Q: The drive from your home to see Dr. Bergman and Dr. Deal, how long does that typically take you?
A: Well, it depends on the traffic, because they doing a lot of road work out there,





and traffic is wild out there.
Q: You're talking about on Interstate 20?
A: On Interstate 20, yes, sir.
Q: Does it normally take you an hour or less than an hour or how long ---
A: It take, it take over an hour.
Q: And is that due, in large part, to the construction that's going on out there?
A: I guess that's what it is, but I take my time. I leave in enough time to make sure that I make it on time, so, I don't be in a rush, so I don't have to rush in, and I just take my time and just cruise down the road.
Q: When you drive from Sumter to see Dr. Bergman and Dr. Deal, do you have any difficulty finding their office or driving from your home to there?
A: Not yet, I haven't.
Q: Do you use a GPS or do you know where you're going well enough now that you don't need a map or anything?
A: I know where I'm going, pretty much, now that I don't need a map.
Q: I presume you've got a visit with Dr.

Bergman one day this week?
A: Yes, I do. I have one, I think, tomorrow. I have to check my schedule.
Q: Are you going to that appointment alone or do you know if your wife is going to be going with you or do you know?
A: I will be going alone tomorrow, 'cause she have to work tomorrow.
Q: Other than Dr. Bergman and Dr. Deal and Dr. Sandor, are you seeing anyone else at all right now for your work-related injuries?
A: Other than Dr. Poletti.
Q: Anyone else besides those four doctors?
A: No, not now I'm not. I was seeing Dr. Lozanne.
Q: How long ago has it been since you last saw Dr. Lozanne?
A: I'm thinking it was sometime this month, sometime in March. I'm not exactly sure. I think it was sometime in March.
Q: So you would've seen him within the last month or so?
A: Yes, I think I have.
Q: Do you know if you were at that visit





alone or if your wife would've been with you?
A: Well, I just want you to understand one thing, not trying to be smart or funny or anything.
Q: No, sir.
A: Every medical visit I go to, my wife is there, she takes me, every one, I mean, every one, but when I go to see Dr. Deal and Dr. Bergman, she's there sometime.
Q: Okay, I got you.
A: So like I say, I'm not trying to be funny or anything.
Q: No, sir. No, no, no, that helps answer my question.
A: Yeah. Yeah, every, every medical visit I see a medical doctor as in dealing with, with medicine and stuff like that, she's always there at every one.
Q: When you last saw Dr. Lozanne, was this after you had had surgery on your neck?
A: Yes, sir.
Q: What type of conversation did you all have or did you talk about your surgery and how that came about or kind of tell





me what went on during your visit with Dr. Lozanne?
A: Well, with Dr. Lozanne, I would call Dr. Lozanne and tell Dr. Lozanne that I'm having problems, that I'm hurting, and his nurse or secretary will answer the phone and say, "I promise that I'll have him to call you back." He have a certain day to have, that he will have me to come in to see him, and he have never yet to tell me, when I call him and let him know that I'm in so much pain, that I really need to see him, he have never told me, say, "Well, let's cancel that day and come on into my office so I can see what's going on." To me, he act like he was a perfect person, that whatever he was doing it was all right and nothing was ever wrong. That's how it seemed to me, and he would never let me come in early, and when I went to see him the last time after I had my surgery, his words to me was, "I am sorry about whatever happened, I see you had surgery on your neck." I can't remember if he





already told me that he know who did the surgery, but he said, he start talking real easy and real soft and said, "I'm sorry about what happened, you know, I didn't — I wasn't" -- how did he say the thing? "I was not able to do what needed to been done." I complained to him about the pain in my arm and I was having pains in my neck, so he did a MRI on me, and so when he, when he got ready to do the MRI, I asked him, I said, "Dr. Lozanne, are you going to check my neck while you doing the MRI?"

His words to me was, "I don't think the problem is coming from your neck, the problem is coming from your shoulder down." So I was in the MRI machine, right there at my neck, and he still refused to do the MRI on my neck, and it got so bad in, in, in December, like I said, I could barely get out the bed and my wife could not let me lay there and suffer the way I was, and we beg and plead with him and he would not do nothing about it.

house and the hall, the hall can catch me or whatever, other than that, no, I don't.

Q: And how long do you think you've been using that cane?

A: This cane, after they finally sent it to me, I don't know. They sent it to me last year sometime, but I was using another cane before they sent me this one, because it got four posts on the bottom and it help me balance myself better, but I've been using the cane for a long time. I can't say exactly how long.

Q: Your home, is it a one-story home or a two-story?

A: Yes, it is, one-story.

Q: You mentioned that you sleep during the day.

A: Yes.

Q: Is your wife at work? Does she work during the day?

A: Yes, she does.

Q: Take me through, Mr. Benjamin, what you generally do on a day to day basis. What





time do you normally wake up in the mornings?

A: Well, it depends whether I got a doctor appointment in Columbia with Dr. ---

Q: Bergman?

A: --- Bergman, yes. If I got a doctor appointment with Dr. Bergman, either way, I normally wakes up about five o'clock in the morning, whether I got a appointment with him or not, because the medicine could be done wore off of me, and so Dr. Deal told me I could take another pill to kind of help me go back to sleep. I don't take that medicine, because I don't want to run the risk, chance of driving and dropping to sleep, so I, I be, I be laying in the bed, awake, about five in the morning time.

Q: What do you do when you get out of bed?

A: Get up and get a shower, go get something to eat from the house there, because my wife, she will get up before she go to work and fix me breakfast every morning. I just stay around the house.

Q: What do you generally do around your





home?

A: Nothing.

Q: Do you and your wife have a computer in your home?

A: Yes, I do.

Q: Do you ever go onto the computer and use it for any reason?

A: No, I don't.

Q: Do you ever surf the Internet or read the news or anything like that on the computer?

A: No, I don't, look at it on TV.

Q: With the exception of when you go to your doctors' appointments, do you ever leave your home for any reason?

A: I may go down and visit Dad, Mom and Dad.

Q: And you say they live in Bishopville?

A: Well, they don't stay far. The deal is, I stay in Bishopville as well, but I got a, I got a Sumter address, so they don't stay far away from me, so I go down and visit them sometime.

Q: Do you ever go and do anything else other than visiting your folks? Do you ever go anywhere else at all?





A: No, I don't, because I found out who my friends are. I don't have any. So when I go visit them, they can't come visit me when I'm down.

Q: When you drive to Columbia for your visits with Dr. Bergman, do you ever stop along the way and do anything in the Columbia area or in Sumter?

A: No, I don't.

Q: As far as driving is concerned, do you feel as though you can safely drive from Sumter/Bishopville, your home, to your visits in Columbia to see Dr. Bergman?

A: Evidently, I guess so. I hadn't had a accident, yet, so I've been doing, doing pretty good, yes, sir.

Q: Do you have any difficulty at all operating the car, driving?

A: No.

Q: Any problems from a, not only just a physical standpoint, but mentally as far as being aware of what's going on on the road and reacting to other drivers and doing those sorts of things, any issue with that?

A: I react to what's going on, because I take my time, I mean, if I — if I'm going — it's like I told Dr. Deal one day, no, Dr. Bergman one day. I said one day I was trying to pass this truck and it was a tow truck, the tow truck seemed like it was a mile long, I couldn't never get around this truck, and I said I don't know what in the world had me so sleepy that day. I was so sleepy and — but I was almost about to get off the interstate, and when I got home, I was in the bed the rest of the day. I don't know what in the world caused that, all of a sudden, just like something just came over me.

Q: Mr. Benjamin, as far as your treatment and your surgery in particular with Dr. Poletti, is that being paid for by your health insurance or by your wife's insurance? Who's responsible for the charges associated with that surgery or do you know?

A: Well, I'm thinking at this time my insurance is taking care of it.





Q: And this would be your health insurance —

A: Yes.

Q: — through Raxam?

A: Yes.

Q: Are you having to, and again, I don't know the answer to this question, which is why I'm asking you, are you having to continue to pay for your health insurance through Raxam out of pocket; in other words, do you have a premium you have to pay for that?

A: Not as of yet, I don't.

Q: But you still have your health insurance through them?

A: Yes, the reason because of that, we have a Union out there and they, they make sure that everything is taken care of, 'cause most jobs aren't going to be that nice and do that for you on your own.

Q: Mr. Benjamin, if you give me just a second, I think I've asked you all the questions I need to.

A: Okay.

Q: And I thank you for your time this





morning.

A: Okay.

Q: Just one final question. I think I know the answer to this, but let me just ask you to make sure. Other than your neck surgery that you had in February, —

A: Yes, sir.

Q: —.have you had any other surgeries at all since March the 2nd of 2012?

A: March 2nd, 2012?

Q: Yes, sir. You had your surgery with Dr. Poletti in March, and I believe Dr. Lozanne did surgery on your neck in February of 2013. Other than those two surgeries, have you had any other surgeries at all since March 2nd, 2012?

A: No, sir.

Q: Other than the hospitalizations associated with those two surgeries, have you been in the hospital for any reason at all —

A: No.

Q: — since March of 2012?

A: Not since March 2012.

Q: Mr. Benjamin, those are all the questions





I have. Thank you, sir. Thank you for your time this morning.

A: Okay. Thank you.

(The deposition concluded at 12:00 p.m.)

BEFORE THE SOUTH CAROLINA
WORKERS' COMPENSATION COMMISSION
WCC FILE NO. 1106789

| | | |
|---|---|---|
| Victor G. Benjamin, | ) | |
| Claimant, | ) | Deposition |
| vs. | ) | of |
| Rexam, Inc., | ) | Karl Lozanne, M.D. |
| Employer, | ) | |
| Sedgwick Claims Management Services, Inc., | ) | |
| Carrier. | ) | |

Deposition of Karl Lozanne, M.D., pursuant to the Rules of the South Carolina Workers' Compensation Commission, commencing at 2:51 p.m., Wednesday, May 21st, 2014, at the office of Columbia Neurological Associates, P.A., 132 Sunset Court, West Columbia, South Carolina.

Reported by:
Cheri B. Williams, CVR-M

Appearances

For the Claimant (via telephone):

Jeffrey C. Chandler, Esquire
Chandler Law Firm
Post Office Drawer 1889
Myrtle Beach, SC 29578

For the Employer/ Carrier:

Jason W. Lockhart, Esquire
McAngus, Goudelock & Courie, LLC
1320 Main Street, 10th Floor
Post Office Box 12519
Columbia, SC 29211

Reported by: Cheri B. Williams, CVR-M

Also Present: Victor G. Benjamin
Letia Benjamin

Index

Stipulations . . . . . 3
Examination by Mr. Lockhart . . . . . 3
Cross-examination by Mr. Chandler . . . . . 25
Re-examination by Mr. Lockhart . . . . . 49
Certificate . . . . . 51

Exhibits

Defendants' Exhibit No. 1, Southeastern Spine Institute Records; eight pages.
Plaintiff's Exhibit No. 1, Grand Strand Records; five pages.

Plaintiff's Exhibit No. 2, Chandler Law Firm Letter dated 8/19/13; one page.
Plaintiff's Exhibit No. 3, Southeastern Spine Institute Records; 17 pages.

Court Reporter's Note: This transcript may contain quoted material. Such material is reproduced as read or quoted by the speaker. Double hyphens (--) denote interruption of speech, incomplete sentence/phrase, or trailing off. [ph] denotes phonetically written. [sic] denotes written as spoken.

1 record, Jeff and I agreed that you are a physician
2 who treats primarily -- you're a neurosurgeon
3 practicing here in Columbia. You treat spinal
4 injuries, is that correct?
5 A That's correct.
6 Q And it's my understanding that you are a board
7 eligible neurosurgeon as well, is that correct?
8 A That's correct.
9 Q Okay. All right.
10 Mr. Lockhart: Jeff, I would offer Dr.
11 Lozanne up as an expert in the area of
12 neurosurgery.
13 Mr. Chandler: No objection.
14 Q Dr. Lozanne, let me talk to you for a moment about
15 your treatment of Mr. Benjamin, and I want to start
16 with you -- with talking with you about your
17 initial visit with him, which according to your
18 records took place on or about January 22nd of
19 2013, is that correct?
20 A That's correct.
21 Q When Mr. Benjamin was initially examined in your
22 office he provided you with a history of a work-
23 related accident, correct?
24 A That's correct.
25 Q And what were the subjective complaints that he

1 seeing.
2 Q With regards to Mr. Benjamin's cervical spine as of
3 the date of your August 20, 2013 examination, was
4 Mr. Benjamin in any need of emergency medical
5 treatment with regards to his cervical spine?
6 A No. There was nothing in need of emergency
7 treatment, no.
8 Q Okay. Dr. Lozanne, I want to talk to you now --
9 we're going to come back in a moment to your most
10 recent visit with Mr. Benjamin, which I believe
11 took place in March, but I want to talk to you now
12 about a period of time between your August visit
13 and your March visit when Mr. Benjamin was seen by
14 Steven Poletti and his staff down at the
15 Southeastern Spine Institute. I have marked as
16 exhibit a collection of medical records from the
17 Southeastern Spine Institute that I want to have
18 you take a look at. I have some questions and I
19 want your thoughts on some of the information
20 that's contained within these records.
21 A Sure.
22 Q If you could turn with me to the second and third
23 page of the exhibit that I had marked. This is a
24 radiology report from an entity called -- I believe
25 they're called DiscRad, which is perhaps a part of

1 the Southeastern Spine Institute.
2 A Uh-huh.
3 Q Does this appear to be a radiology report from a
4 cervical MRI of Mr. Benjamin that was done on or
5 about January 20th of 2014?
6 A That's correct.
7 Q All right. Based on your review of this report,
8 can you tell us, again in layman's terms and
9 specifically with regards to the C3-4 level, what
10 this particular report reveals about what was the
11 state of Mr. Benjamin's cervical spine as of the
12 date of this particular test?
13 A Okay. In particular at the C 3-4 level it noted
14 osteophytes with several bilateral foraminal
15 stenosis.
16 Q And in the remaining levels, particularly those on
17 which you performed surgery, it appeared -- what
18 are the findings as far as those levels are
19 concerned?
20 A Those findings, fusion at C4-5 with hardware and
21 moderate bilateral foraminal stenosis. Fusion with
22 hardware and moderate severe right and moderate
23 left foraminal stenosis at C5-6. C6-7 fusion with
24 hardware and severe left and moderate to moderately
25 severe right foraminal stenosis.

1 Q Are those -- are the findings of the radiologist as
2 noted in this particular report consistent with the
3 subjective complaints that were provided to Mr. --
4 to you by Mr. Benjamin when you last saw him in
5 August of 2013?
6 A You say the findings from the MRI, they're
7 consistent with his --
8 Q Subjective complaints.
9 A With his subjective complaints? Yes, they're
10 consistent with the subjective complaints.
11 Q With regards to the pathology noted at C3-4, is
12 that consistent with the pathology that you
13 originally noted when you saw him back in January
14 of 2013 or was there anything different about these
15 particular findings compared to the ones that you
16 had made originally?
17 A Yeah. I did not see severe bilateral foraminal
18 stenosis at C3-4 level, and in particular at that
19 level there was the issue with the spinal
20 abnormality and signal change which is more
21 manifestation of a central canal stenosis if it is
22 present.
23 Q Are any of the findings that are noted in the
24 radiology report that I just showed to you
25 suggestive of a cervical pathology that would

1 necessitate emergency surgery?
2 A No.
3 Q Let me have you just turn back to the first page of
4 the exhibit that I showed you. This is a
5 diagnostic report from Southeastern Spine Institute
6 dated January 20th of 2014. Have you ever seen
7 this report before?
8 A When Mr. Benjamin came back, I want to say that --
9 I want to say that he may have brought the report
10 because he wanted to discuss the findings with me.
11 I don't remember if it was him, but I remember
12 seeing something from Southeastern Spine when he
13 came back in in March in particular. And it may
14 have been provided by my staff. I remember seeing
15 something from Southeastern Spine and discussing
16 with him that he had gone to see Dr. Poletti and
17 had actually had surgery at that time.
18 Q Yes. Sure.
19 A But I don't remember who actually provided it for
20 me.
21 Q Okay. Would you mind just taking a brief moment to
22 look at this note and then I just wanted to ask you
23 a couple questions about it.
24 A Okay.
25 Q Based on your review of the diagnostic report of

1 the Southeastern Spine Institute dated January the
2 20th of 2014, how do the complaints that Mr.
3 Benjamin provided to that practice compare to the
4 complaints he provided you when you last saw him
5 prior to that date in August of 2013?
6 A They're consistent.
7 Q Okay. All right. Based on your review of the
8 diagnostic report of the Southeastern Spine
9 Institute dated January 20, 2014, are there any
10 findings in this report that, in your opinion,
11 would support the need for emergency medical
12 treatment?
13 A No, nothing emergent.
14 Q And that's something, I guess, that we need to, I
15 guess, talk about for just a moment. I've used
16 that term twice now and I'm going to use it again
17 in just a moment, but is there a standard that you
18 utilize in order to determine if someone is in need
19 of emergency medical treatment? And particularly
20 with regards to the cervical spine, for example.
21 A Yeah. Yeah. There's certain things in the
22 cervical spine that require emergent treatment, and
23 everything that's been described and everything
24 that I evaluated was not anything that required any
25 emergent treatment.

1 Q. Okay. All right. Turn with me, if you would, to
2 the fourth page of the exhibit that I presented to
3 you. This is a diagnostic report from the
4 Southeastern Spine Institute. It's dated one day
5 later. It's January 21st of 2014. If you could
6 just take a moment and review this record. I just
7 had a couple of questions I wanted to ask you about
8 it.
9 A Uh-huh. Okay.
10 Q Based on your review of the diagnostic report of
11 Southeastern Spine Institute dated January 21st of
12 2014, does that report indicate that Mr. Benjamin
13 was in need of emergency medical treatment?
14 A No.
15 Q With regards to the conclusions reached by Dr.
16 Poletti in this report -- and you've obviously had
17 an opportunity to review it. With regards to the
18 conclusions reached by Dr. Poletti, does the
19 diagnosis he provided -- is it one that
20 necessitates the performing -- the performance of
21 an emergency cervical procedure?
22 A Yeah. It's not something that's done emergent.
23 You know, I'm going to define emergency here for
24 you. Emergency in the neurosurgical or even in a
25 medical environment is something that tells me hey,

1 we got to get this patient to the hospital and get
2 this procedure done here within the next couple of
3 days. The condition that is being diagnosed here
4 and described by Dr. Poletti is not even something
5 that I would say requires an urgent treatment,
6 meaning that it needs to be done within this first
7 week. He is manifesting symptoms that have
8 persisted and continued for some degree of time. I
9 do not have the benefit of having reviewed the
10 imaging studies that were done at Southeastern
11 Spine Institute. And I discussed this previously
12 with the patient and his wife. I would have loved
13 to have reviewed what he was seeing that I simply
14 did not see on the imaging studies that we reviewed
15 when he first came in to see me. But nonetheless,
16 it's not something that requires an emergent
17 surgical procedure, all right? He's had symptoms
18 that have been consistent. They've been long
19 standing. He has some myelopathy, for which we had
20 a reason that he had a myelopathy. We saw spinal
21 cord signal change previously. He had an
22 examination that was consistent with the
23 examination that I had when I originally saw him.
24 So in terms of requiring an emergent procedure, I
25 do not see the need for an emergent procedure at

1 that particular point.
2 Q And Mr. Benjamin returned to your office and was
3 seen on or about March the 11th of 2014. Let me
4 ask you for a moment about that visit. Is it my
5 understanding that by the time -- I believe the
6 records reflect this, but by the time that you had
7 the opportunity to see Mr. Benjamin again in March
8 he had already undergone an additional cervical
9 surgery performed by Dr. Poletti, is that correct?
10 A That's correct.
11 Q All right. How is your ability to complete a
12 treatment plan, particularly in this case, impacted
13 by the patient's decision to seek treatment
14 somewhere else?
15 A Ask that question again.
16 Q Sure. You had diagnosed Mr. Benjamin with a
17 particular pathology and you had provided him with
18 a surgical procedure and you were treating him
19 postoperatively.
20 A Uh-huh.
21 Q Presuming that the ultimate endpoint would be a
22 determination of maximum medical improvement, how
23 was his decision or Dr. Poletti's decision to
24 perform an additional surgical procedure, how did
25 that impact your ability to complete the treatment

1 plan that you had in place with regards to the
2 pathology that you had been treating him for?
3 A I understand. From my perspective, once -- you
4 know, once there's been an additional surgery for a
5 cervical spine, then additional follow up in
6 regards to the condition does need -- I always
7 recommend that it needs to be continued, managed,
8 by the surgeon who performed that surgery. So it -
9 - it does affect, you know, my ability to continue
10 to manage it from that perspective. The patient
11 has had a more recent surgery. I want to say it
12 was within a few weeks from when I saw him. And I
13 think it's more than appropriate, both from a
14 medical perspective and also from the patient's
15 perspective, to continue to have additional follow
16 up from the more recent surgery with the surgeon
17 who operated.
18 Q With regards to the pathology that you diagnosed
19 and treated with the fusion that you performed, are
20 you able to speak as to whether Mr. Benjamin had
21 reached maximum medical improvement with regards to
22 that problem, the problem for which you provided
23 him with medical care?
24 A You know, we had planned on actually bringing him
25 back at about a year's time after the surgical

1 at C3-4 as Dr. Poletti performed?
2 A Yeah. And that is something that I wish that you
3 would ask Dr. Poletti. If there's an indication,
4 if there's progression of stenosis at an adjacent
5 level for you to perform a surgical intervention,
6 so I think that is an appropriate plan of care.
7 Mr. Chandler: Okay. Please answer any
8 other questions Mr. Lockhart has of you.
9 Re-examination
10 By Mr. Lockhart:
11 Q Dr. Lozanne, just a couple. While Dr. -- in your
12 opinion, I think you just said that Dr. Poletti's
13 provision of surgery was an appropriate plan of
14 care, correct?
15 A Right. If there's significant progressing
16 stenosis.
17 Q You've had an opportunity to review both of his
18 reports from January and you also had an
19 opportunity to review the MRI that was performed in
20 conjunction with his two visits with Mr. Benjamin.
21 Based on what you've seen in those reports, in your
22 expert opinion and to a reasonable degree of
23 medical certainty, was Mr. Benjamin in need of an
24 emergency cervical procedure?
25 A No. I don't think he needed an emergency surgical

1 procedure.

2 Mr. Lockhart: Those are all the questions

3 I have.

4 Mr. Chandler: Thank you, Doctor.

5 (Whereupon the deposition was concluded at

6 3:57 p.m.)

7

8

9

10

11

12

13

14

15

16

17

18

19

20

21

22

23

24

25

SOUTH CAROLINA WORKERS' COMPENSATION COMMISSION
COLUMBIA, SOUTH CAROLINA
WCC FILE NO. 1106789

COPY

**EMPLOYEE/CLAIMANT:** VICTOR G. BENJAMIN

**EMPLOYER:** REXAM, INC.

**CARRIER:** HARTFORD CASUALTY INSURANCE COMPANY

---

**SOUTH CAROLINA WORKERS' COMPENSATION HEARING**

---

PURSUANT TO NOTICE OF WORKERS' COMPENSATION HEARING, THE WITHIN HEARING WAS TAKEN ON THE 23RD DAY OF JUNE, 2014, COMMENCING AT THE HOUR OF 1:37 P.M., IN SUMTER, SOUTH CAROLINA, BEFORE THE HONORABLE SUSAN S. BARDEN, ATTENDED BY COUNSEL AS FOLLOWS:

**TIMMI A. PARRISH**
**VERBATIM REPORTER**

---

*TIMMI A. PARRISH*
**COURT REPORTING SERVICES**
**POST OFFICE BOX 551**
**ROEBUCK, SC 29376**
**864-921-8743**

## APPEARANCES

**JEFFREY C. CHANDLER**, ESQUIRE, OF THE
CHANDLER LAW FIRM
2501 OAK STREET
MYRTLE BEACH, SOUTH CAROLINA 29578

ATTORNEY FOR THE CLAIMANT,

**JASON W. LOCKHART**, ESQUIRE, OF THE FIRM
McANGUS GOUDELOCK & COURIE, LLC
POST OFFICE BOX 12519
COLUMBIA, SOUTH CAROLINA 29211

ATTORNEY FOR THE EMPLOYER/CARRIER.

**ALSO ATTENDING:** MRS. LETIA BENJAMIN

# I N D E X


PAGE

VICTOR G. BENJAMIN:

DIRECT EXAMINATION BY MR. CHANDLER..... 16
CROSS EXAMINATION BY MR. LOCKHART..... 43
REDIRECT EXAMINATION BY MR. CHANDLER..... 51

CERTIFICATE OF NOTARY PUBLIC..... 56

1 IDEA OF HOW IT OCCURRED. SO I'M GOING TO OVERRULE
2 YOUR OBJECTION, AND I WOULD LIKE TO HEAR JUST
3 BRIEFLY HOW IT HAPPENED. IT IS AN ADMITTED CLAIM;
4 YOU'RE ENTIRELY RIGHT.
5 **BY THE WITNESS:**
6 OKAY. SO I CAN GO AHEAD, YOUR HONOR?
7 **BY THE COMMISSIONER:**
8 YES, SIR.
9 **BY THE WITNESS:**
10 OKAY.
11 **BY THE COMMISSIONER:**
12 YOU DON'T HAVE TO GO INTO GREAT DETAIL. JUST
13 TELL ME HOW IT HAPPENED.
14 **WITNESS ANSWERS:**
15 A. WELL, THE ONLY THING I CAN TELL YOU, YOUR HONOR,
16 WHEN I WENT IN TO WORK THAT NIGHT, I RUN A MACHINE
17 WHAT THEY CALL A CUPPER. THAT'S WHY THEY MAKE CUPS.
18 AND THEY HAD A PROBLEM WITH THE MACHINE ALL DAY
19 LONG. AND SO WHEN I WENT IN THERE -- THEY RUN SIX
20 BELTS ON THIS MACHINE ABOUT FOUR INCHES WIDE. AND
21 SO WHEN I WENT IN THERE, BELTS WAS ALL OVER THE
22 FLOOR AND GREASE AND ALL THAT STUFF WAS ALL OVER THE
23 FLOOR, SO I ASKED THE GUY THAT I WAS RELIEVING WHAT
24 WAS GOING ON. HE SAID, "WELL, WE'VE GOT A PROBLEM
25 WITH THE BELTS UP TOP UP THERE." SO, I SAID, "WELL,

1 Y'ALL DIDN'T SHUT IT DOWN AND FIX IT?" HE SAID,
2 "WELL, WE'VE BEEN WORKING ON IT ALL DAY." BUT WHEN
3 I GOT THERE -- IT CARRIED SIX BELTS, LIKE I SAID
4 EARLIER -- THEY WAS RUNNING THE MACHINE WITH ONLY
5 TWO BELTS. I SAID, "Y'ALL STILL RUNNING THE
6 MACHINE?" HE SAID, 'WELL, YOU KNOW WE'VE GOT
7 MAINTENANCE IN THE MORNING, SO WE'RE GOING TO TRY
8 TO" -- THEY WAS TRYING TO MAKE IT TO MAINTENANCE IN
9 THE MORNING WHERE THEY SHUT THE WHOLE PLANT DOWN.
10 SO, THE ONLY THING I CAN REMEMBER -- I KNOW MY
11 DUTIES EVERY NIGHT AND WHAT I GOT TO DO. THE ONLY
12 THING I CAN REMEMBER, THE MACHINE, WHAT IT DOES
13 EVERY NIGHT ALL NIGHT LONG AND ALL DAY, 24 HOURS A
14 DAY, SET THERE AND GO BOOM, BOOM, BOOM. THAT'S WHAT
15 IT DOES, PUNCHES OUT CUPS, AND THE ONLY THING I CAN
16 REMEMBER AND WHAT WAS TOLD ME IS WHEN I GOT READY TO
17 SHUT THE MACHINE DOWN, I HAVE TO WRITE THE NUMBERS
18 DOWN. I WROTE THE NUMBERS DOWN, I GUESS. AND SO
19 WHEN THE MACHINE WENT DOWN, I HIT THE STOP BUTTON TO
20 SHUT THE MACHINE DOWN. AND SO WHAT THEY TOLD ME
21 WHAT THEY THINK WHAT HAPPENED, AFTER THEY WERE
22 WORKING ON THE MACHINE THAT DAY, THEY NEVER HAD
23 MOUNTED THE COVER BACK DOWN ON THE MACHINE LIKE IT
24 SHOULD'VE BEEN. SO EVIDENTLY WHEN THE MACHINE WENT
25 DOWN, YOU GOT A CLUTCH UP THERE, SO IT SHUTS

1 EVERYTHING OFF. SO, THEY TOLD ME THEY THINK WHAT
2 HAPPENED, THAT THE COVER WENT AGAINST THE CLUTCH.
3 SO WHEN IT WAS TIME AFTER THE GUYS IN THE BACK,
4 AFTER I DONE TURNED THE COIL -- AFTER THEY DONE
5 TURNED THE COIL AND GETTING READY TO START THE
6 MACHINE BACK UP, SO WHEN I GOT READY TO HIT THE
7 START BUTTON, I DON'T REMEMBER -- I DON'T REMEMBER
8 NONE OF THIS, BUT I KNOW THIS IS HOW IT NORMALLY
9 HAPPENS EVERY DAY AND EVERY NIGHT FOR 30 YEARS THAT
10 I'VE BEEN WORKING THERE, HIT THE START BUTTON. LIKE
11 I SAY, I DON'T REMEMBER -- I DON'T REMEMBER NOTHING.
12 I DON'T EVEN REMEMBER HITTING THE START BUTTON. I
13 DON'T REMEMBER SHUTTING THE BUTTON. I WAS JUST ---
14 **BY THE COMMISSIONER:**
15 YOU WERE WORKING AT THE MACHINE AND ---
16 **BY THE WITNESS:**
17 YEAH. I DON'T KNOW NOTHING.
18 **BY THE COMMISSIONER:**
19 THAT'S GOOD ENOUGH.
20 **WITNESS RESUMES:**
21 A. BUT THE GUYS TOLD ME THEY WAS WONDERING WHAT WAS
22 GOING ON, WHY IT WAS TAKING ME SO LONG TO START THE
23 MACHINE UP. I HAD ONE TO THE RIGHT AND ONE TO THE
24 LEFT. THE ONE FARTHEST TO THE LEFT COULD SEE MORE
25 OF ME THAN THE ONE TO THE RIGHT BECAUSE THE WAY THE

1 PALLET SETS AT THE MACHINE. THE ONE TO THE RIGHT
2 TOLD ME, SAID HE REMEMBERED OIL DROPPING OFF THE
3 MACHINE, BECAUSE HE THOUGHT MAYBE IT WAS JUST OIL
4 JUST DROPPING OFF THE MACHINE. HE DIDN'T KNOW THAT
5 THE COVER EJECTED OFF THE MACHINE. HOW HIGH THE
6 COVER EJECTED OFF, NOBODY KNOWS BECAUSE THE MACHINE
7 SETS LIKE 30 FOOTS UP IN THE AIR. BUT WE GOT A
8 FOUR-FOOT GUARD AROUND THE TOP OF THAT MACHINE, AND
9 AROUND THAT GUARD, THAT GUARD -- I MEAN, THAT FOUR-
10 FOOT RAILING, THAT GUARD CANNOT EJECT DIRECTLY
11 STRAIGHT OFF THAT MACHINE. SO THE GUARD HAD TO GO
12 UP, THEN COME DOWN. IT CANNOT GO DIRECTLY STRAIGHT
13 OFF THE MACHINE.
14 **DIRECT EXAMINATION RESUMED BY MR. CHANDLER:**
15 Q. SO YOU WERE INJURED WHEN THE GUARD STRUCK YOU; IS
16 THAT YOUR UNDERSTANDING?
17 A. THAT'S WHAT I WAS UNDERSTANDING. THE ONLY THING I
18 CAN REMEMBER, COMING BACK THROUGH ONE TIME, A LADY
19 LAYING ON ME CRYING, TELLING ME IT WAS GOING TO BE
20 OKAY. I HAD NOT A CLUE WHAT SHE WAS TALKING ABOUT
21 AND THE THINGS SHE TOLD ME. THE ONLY THING I KNOW,
22 THAT MY HEAD GOT CRACKED OPEN AND THERE WAS A BUNCH
23 OF BLOOD. BASICALLY BLOOD WAS EVERYWHERE. WHICH
24 THE OTHER GUYS WHEN THEY GOT THERE, 'CAUSE THEY WAS
25 WALKING ACROSS; THEY WAS DOING MAINTENANCE ON

1 ANOTHER MACHINE -- ON ANOTHER MACHINE, AND THEY WENT
2 AND PUT SOME RAGS BEHIND MY HEAD TO KEEP MY HEAD OFF
3 THE FLOOR, AND I STILL DIDN'T -- I DIDN'T REMEMBER
4 NONE OF THIS. THE ONLY THING I CAN REMEMBER IS
5 GETTING IN THE BACK OF THE AMBULANCE, AND THE PLANT
6 MANAGER WAS THERE, AND I ASKED HIM, I SAID ---
7 Q. VICTOR, LET ME STOOP YOU AND ASK YOU SOME MORE
8 SPECIFIC QUESTIONS.
9 A. OKAY.
10 Q. AND THE COMMISSIONER HAS ALMOST 500 PAGES OF MEDICAL
11 RECORDS, AND SHE'S GOING TO LOOK THROUGH THEM ALL,
12 OKAY?
13 A. OKAY.
14 Q. SO SHE'LL MAKE SURE THAT SHE UNDERSTANDS ALL THE
15 MEDICAL CHRONOLOGY. BUT INITIALLY I KNOW THAT YOU
16 GOT SOME TREATMENT FOR YOUR HEAD?
17 A. YES.
18 Q. YOU GOT SOME TREATMENT FOR YOUR RIGHT ARM, IS THAT
19 RIGHT?
20 A. YES.
21 Q. AND YOU HAD SURGERY BY DR. WELCH OVER IN FLORENCE?
22 A. YES.
23 Q. AND ULTIMATELY YOU STARTED SEEING SOME DOCTORS IN
24 THE MYRTLE BEACH AREA?
25 A. YES, I DID.

1 Q. AND YOU'VE SEEN -- HAVE BEEN AUTHORIZED TO SEE A
2 NEUROLOGIST IN MYRTLE BEACH NAMED GEORGE SANDOZ?
3 A. YES.
4 Q. AND YOU'VE ALSO SEEN SOME PHYSICIANS, A
5 NEUROPSYCHOLOGIST THERE, LEONARD GOLDSCHMIDT AND DR.
6 HARRY SPRINGS?
7 A. YES.
8 Q. OKAY. AND AT SOME POINT YOU'VE WERE GIVEN A
9 REFERRAL TO A EUGENE GIDDENS?
10 A. YES.
11 Q. AND THAT'S A NEUROSURGEON IN MYRTLE BEACH, IS THAT
12 RIGHT?
13 A. YES, IT IS.
14 Q. AND WHAT KIND OF COMPLAINTS WERE YOU HAVING WHEN YOU
15 SAW DR. GIDDENS, IF YOU REMEMBER?
16 A. WHEN I WAS SEEING DR. GIDDENS, I WAS HAVING BAD
17 HEADACHES. I WAS HAVING PAIN DOWN MY RIGHT SIDE,
18 DOWN MY RIGHT ARM. I WAS HAVING SHARP PAINS IN MY
19 HEAD AND HAD A LOT OF THINGS I COULDN'T REMEMBER,
20 AND I WAS BEING REAL ILL. I STILL HAVE A PROBLEM
21 WITH THAT TODAY. I'M STILL WORKING ON THAT.
22 Q. DR. GIDDENS MADE A RECOMMENDATION FOR SURGERY OF
23 YOUR SPINE, IS THAT RIGHT?
24 A. YES, HE DID.
25 Q. AND YOU DIDN'T GO FORWARD WITH THE SURGERY BY DR.

1 GIDDENS, CORRECT?
2 A. CORRECT.
3 **BY THE COMMISSIONER:**
4 WHAT HAPPENED? WHY DID YOU NOT GO FORWARD WITH
5 THE SURGERY WITH DR. GIDDENS?
6 **BY THE WITNESS:**
7 WELL, COMMISSIONER -- MS. COMMISSIONER, THE
8 REASON WHY I DIDN'T GO FORWARD WITH THE SURGERY WITH
9 HIM, 'CAUSE I WAS SITTING IN HIS OFFICE THAT DAY,
10 EVERYBODY IN THE OFFICE WAS IN THERE COMPLAINING A
11 LITTLE BIT ABOUT HIM.
12 **BY MR. LOCKHART:**
13 YOUR HONOR, I'M SORRY; I'M GOING TO HAVE TO
14 OBJECT.
15 **BY THE COMMISSIONER:**
16 SUSTAINED, BECAUSE THAT DOES REQUIRE A HEARSAY
17 ANSWER. YOU JUST DIDN'T GET A GOOD FEELING ABOUT
18 IT; WOULD THAT BE FAIR ENOUGH TO SAY?
19 **BY THE WITNESS:**
20 THAT WOULD BE FAIR ENOUGH TO SAY; I DIDN'T GET
21 A GOOD FEELING.
22 **BY THE COMMISSIONER:**
23 OKAY, ALL RIGHT.
24 **DIRECT EXAMINATION RESUMED BY MR. CHANDLER:**
25 Q. VICTOR, YOU REQUESTED THAT I SEND YOU TO A DOCTOR

1 **BY MR. LOCKHART:**

2 THIS IS AN ACCEPTED CLAIM IN WHICH DR. LOZANNE
3 WAS SELECTED BY THE CARRIER. THE CLAIMANT AND HIS
4 ATTORNEY WERE INFORMED OF THAT DECISION. I'M SORRY;
5 I JUST DON'T ---

6 **BY THE COMMISSIONER:**

7 WAS DR. LOZANNE MUTUALLY AGREED UPON BY CONSENT
8 ORDER, OR WAS THAT JUST YOU ALL WERE ASKED TO DO
9 ANOTHER OPINION AFTER ---

10 **BY MR. LOCKHART:**

11 IT WAS MUTUALLY AGREED UPON BY THE PARTIES. IT
12 WASN'T MEMORIALIZED IN A CONSENT ORDER.

13 **BY THE COMMISSIONER:**

14 OKAY. WELL, I AM GOING TO ALLOW HIM TO TELL
15 ME. WITHOUT GOING INTO ANYTHING THAT DR. LOZANNE
16 SAID, DID YOU HAVE A GOOD DOCTOR/PATIENT
17 RELATIONSHIP WITH DR. LOZANNE?

18 **BY THE WITNESS:**

19 YES, I DID.

20 **BY THE COMMISSIONER:**

21 OKAY, ALL RIGHT. GO AHEAD.

22 **DIRECT EXAMINATION RESUMED BY MR. CHANDLER:**

23 Q. WHAT RECOMMENDATIONS DID DR. LOZANNE HAVE FOR YOU?

24 A. THE RECOMMENDATION THAT HE HAD WAS -- I CAN TELL
25 WHAT THE DOCTOR SAID?

1 BALANCE.

2 **BY THE COMMISSIONER:**

3 OKAY, ALL RIGHT. THAT'S SOUNDS ---

4 **BY THE WITNESS:**

5 AND MY BALANCE, BECAUSE I WILL FROM TIME TO

6 TIME STUMBLE. THAT'S WHY I USE THE CANE.

7 **BY THE COMMISSIONER:**

8 OKAY, ALL RIGHT.

9 **DIRECT EXAMINATION RESUMED BY MR. CHANDLER:**

10 Q. YOU ELECTED TO HAVE THE SURGERY THAT DR. LOZANNE

11 RECOMMENDED AT C4 THROUGH C7; IS THAT CORRECT?

12 A. YES, I DID.

13 Q. HOW WERE YOU DOING AFTER THE SURGERY? DID IT MAKE

14 YOU BETTER FROM ALL THE SYMPTOMS THAT YOU HAD WHEN

15 YOU WENT THERE, OR DID THEY CONTINUE TO BE BAD?

16 A. I REALLY THOUGHT I WAS GOING TO DIE FOR SIX TO NINE

17 MONTHS, HONESTLY. I STARTED HAVING -- I STARTED

18 HAVING THESE NIGHTMARES, DAY MARES. I GOT TO THE

19 PLACE IT GOT SO BAD I WAS SCARED TO GO TO SLEEP. I

20 WAS VERY IRRITABLE TO EVERYBODY. I WOULD -- I WOULD

21 -- MY WIFE WOULD TELL ME HOW ILL I WAS, AND I DIDN'T

22 REALIZE IT, MY SON. I WAS VERY -- FOR SIX TO NINE

23 MONTHS I WAS REALLY, REALLY SICK. I DON'T KNOW WHAT

24 HAPPENED DURING THAT SURGERY, BUT FOR SIX TO NINE

25 MONTHS I WOULD HAVE TO CALL MY PSYCHIATRIST -- I

1 BECAUSE I WASN'T GETTING ANY BETTER, AND I TALKED TO
2 DR. LOZANNE ABOUT IT. WELL, I TRIED TO TALK TO HIM
3 ABOUT IT. IT'S LIKE HE WASN'T HEARING WHAT I WAS
4 SAYING, LIKE IF I WAS JUST TALKING TO THE WALL.
5 THAT'S HOW IT SEEMED TO ME.
6 **BY MR. CHANDLER:**
7 ANSWER ANY QUESTIONS THAT ATTORNEY LOCKHART
8 WOULD HAVE OF YOU.
9 **BY THE COMMISSIONER:**
10 MR. LOCKHART.
11 **CROSS EXAMINATION BY MR. LOCKHART:**
12 Q. MR. BENJAMIN, WHEN YOU WERE INITIALLY SEEN BY DR.
13 LOZANNE, YOUR FIRST VISIT THERE, WAS THAT
14 EXAMINATION SCHEDULED BY YOUR LAWYER'S OFFICE?
15 A. REPEAT THAT ONE MORE TIME, PLEASE.
16 Q. WHEN YOU WERE SEEN BY DR. POLETTI THE FIRST TIME,
17 ---
18 A. YES.
19 Q. --- WAS THAT EXAMINATION SCHEDULED BY YOUR
20 ATTORNEY'S OFFICE?
21 A. YES, IT WAS.
22 Q. WAS THAT EXAMINATION, TO YOUR KNOWLEDGE, PAID FOR BY
23 YOUR ATTORNEY'S OFFICE?
24 A. NO, IT WAS NOT.
25 Q. WHO PAID FOR THE EXAMINATION?

1 A. MY INSURANCE.
2 Q. YOUR HEALTH INSURANCE?
3 A. YES.
4 Q. YOUR HEALTH INSURANCE, HAS IT PAID FOR THE SURGERY
5 THAT YOU UNDERWENT WITH DR. POLETTI?
6 A. YES, IT HAS.
7 Q. HAS IT PAID FOR ANY FOLLOW-UP EXAMINATIONS THAT
8 YOU'VE HAD WITH HIM?
9 A. SOME OF THEM, YEAH.
10 Q. HAVE YOU SUBMITTED ANY EVIDENCE TODAY OF ANY OUT-OF-
11 POCKET MEDICAL EXPENSES OR MONIES THAT YOU'VE PAID
12 FOR THE TREATMENT YOU RECEIVED FROM DR. POLETTI?
13 A. I HAVE THE RECEIPTS FOR THEM.
14 Q. HAVE YOU PRESENTED ANY OF THOSE TODAY AS EVIDENCE?
15 A. NO, I HAVE NOT PRESENTED ANY.
16 Q. YOU SAW DR. POLETTI ON OR ABOUT JANUARY 21ST OF
17 2014; THAT'S WHAT YOUR RECORDS AT LEAST REFLECT.
18 THIS WOULD'VE BEEN, I THINK, YOUR VISIT WITH HIM
19 RIGHT BEFORE YOUR SURGERY. YOUR SURGERY WAS IN
20 FEBRUARY; IS THAT CORRECT?
21 A. CORRECT.
22 Q. AND THAT WAS DONE DOWN IN CHARLESTON?
23 A. YES, IT WAS; MOUNT PLEASANT.
24 Q. THIS JANUARY 21ST, 2014, VISIT, WHO SCHEDULED THAT
25 EXAMINATION?

1 A. JANUARY 21ST?
2 Q. THAT VISIT WITH DR. POLETTI WHICH TOOK PLACE BEFORE
3 YOU HAD SURGERY, WAS THAT SCHEDULED BY YOU OR BY
4 YOUR LAWYER'S OFFICE?
5 A. IT WAS SCHEDULED BY MY LAWYER'S OFFICE.
6 Q. AND WHO PAID FOR THAT EXAMINATION? WAS IT PAID FOR
7 BY YOUR ATTORNEY OR PAID FOR BY YOUR HEALTH
8 INSURANCE?
9 A. BY MY HEALTH -- WELL, I PAID PART OF IT, AND MY
10 HEALTH INSURANCE PAID FOR THE REST.
11 Q. SO, I JUST WANT TO MAKE SURE THAT I'M CLEAR. ALL OF
12 YOUR VISITS WITH DR. POLETTI BEFORE YOU ACTUALLY HAD
13 SURGERY WERE SCHEDULED BY YOUR LAWYER'S OFFICE,
14 CORRECT?
15 A. ALL OF MY -- BEFORE I HAD SURGERY?
16 Q. YES, SIR. EVERY VISIT WITH DR. POLETTI THAT TOOK
17 PLACE BEFORE YOU HAD SURGERY IN FEBRUARY OF 2014
18 WERE VISITS SCHEDULED BY YOUR ATTORNEY?
19 A. I HAVE A HARD TIME REMEMBERING SOMETIMES.
20 **BY THE COMMISSIONER:**
21 THERE HAVE BEEN TWO, RIGHT? JUST TWO?
22 **BY THE WITNESS:**
23 JUST TWO?
24 **BY THE COMMISSIONER:**
25 I DON'T KNOW. I'M ASKING THAT QUESTION, TOO.

1 **BY MR. LOCKHART:**

2 IT'S MY UNDERSTANDING THERE WERE ONLY TWO.

3 **BY THE COMMISSIONER:**

4 OKAY.

5 **BY THE WITNESS:**

6 YES.

7 **CROSS EXAMINATION RESUMED BY MR. LOCKHART:**

8 Q. BOTH WERE SCHEDULED BY YOUR LAWYER?

9 A. YES.

10 Q. WITH REGARDS TO YOUR TREATMENT WITH DR. LOZANNE, HAS

11 HE RELEASED YOU FROM HIS CARE?

12 A. ACCORDING TO WHAT HE SAID, HE HAS.

13 Q. WELL, YOU WERE AT HIS DEPOSITION, CORRECT?

14 A. YES.

15 Q. ALL RIGHT. AND HIS MEDICAL RECORDS, I'M

16 REPRESENTING TO YOU, DON'T INDICATE HE HAS RELEASED

17 YOU FROM HIS CARE, PUT YOU AT MAXIMUM MEDICAL

18 IMPROVEMENT.

19 **BY MR. CHANDLER:**

20 I OBJECT TO -- IS THAT A QUESTION? I DON'T

21 KNOW IF THAT'S A QUESTION OR IF HE'S TESTIFYING.

22 **BY THE COMMISSIONER:**

23 I DON'T KNOW WHETHER HE -- IF YOU'LL KIND OF

24 BREAK THAT QUESTION DOWN, AND HE MAY NOT KNOW WHAT

25 MAXIMUM MEDICAL IMPROVEMENT IS. MAYBE HE DOES, I

BEFORE THE SOUTH CAROLINA
WORKERS' COMPENSATION COMMISSION
WCC FILE NO.:1106789

| | | |
|---|---|---|
| Victor G. Benjamin,<br><br>Claimant,<br><br>vs.<br><br>Rexam, Inc.,<br><br>Employer,<br><br>Hartford Insurance Company of The Midwest c/o Sedgwick Claims Management Services, Inc.,<br><br>Carrier. | ) | Deposition<br><br>of<br><br>Karl Lozanne, M.D. |

Deposition of Karl Lozanne, M.D., pursuant to the Rules of the South Carolina Workers' Compensation Commission, commencing at 5:42 p.m., July 7th, 2016, at the office of Columbia Neurosurgical at Midlands Orthopaedics, 1910 BLanding Street, Columbia, South Carolina.

Reported by:
Cheri B. Williams, CVR-M

Appearances

For the Claimant
(via telephone):

Jeffrey C. Chandler, Esquire
Chandler Law Firm, P.A.
Post Office Drawer 1889
Myrtle Beach, SC 29578

For the Employer/
Carrier:

Jason W. Lockhart, Esquire
McAngus, Goudelock & Courie, LLC
1320 Main Street, 10th Floor
Post Office Box 12519
Columbia, SC 29211

Index

Stipulations . . . . . 3
Examination by Mr. Lockhart . . . . . 3
Cross-examination by Mr. Chandler . . . . . 18
Certificate . . . . . 27

Exhibits

Defendant's Exhibit No. 1, Medical Records; 26 pages.

Court Reporter's Note: This transcript may contain quoted material. Such material is reproduced as read or quoted by the speaker. Double hyphens (--) denote interruption of speech, incomplete sentence/phrase, or trailing off. [ph] denotes phonetically written. [sic] denotes written as spoken.

1 Stipulations

2 The reading and signing of this deposition is
3 waived by the deponent and counsel for the
4 respective parties.

5 Whereupon,

6 Karl Lozanne, M.D., being duly sworn and
7 cautioned to speak the truth, the whole truth,
8 and nothing but the truth, testified as
9 follows:

10 Direct Examination

11 By Mr. Lockhart:

12 Q Dr. Lozanne, good evening. My name is Jason
13 Lockhart. We met in the context of a case called
14 Victor Benjamin about two years ago, and I had the
15 opportunity to take your deposition across the
16 river in your former office in West Columbia. I'm
17 back here today to ask you some additional
18 questions regarding Mr. Benjamin. We have on the
19 line by phone Jeff Chandler, Mr. Benjamin's
20 attorney, up in Myrtle Beach. We had stipulated
21 previously that you're an expert in the area of
22 neurosurgery, and Jeff has agreed to stipulate to
23 that again here today. And, again, I just have a
24 few questions for you regarding a couple of issues
25 that have come up since your last deposition.

1 A **Sure.**
2 Q Let me get sort of, I guess, one thing out of the
3 way very briefly. It has been some time since
4 you've last seen Mr. Benjamin, is that correct?
5 A **Yes. That's correct.**
6 Q Okay. All right. And it's my understanding that
7 you're scheduled to see him again on or about July
8 22nd of 2016 pursuant to the request of my office.
9 I think you've got your computer here.
10 A **Uh-huh.**
11 Q And does it reflect that you're scheduled to see
12 him on that date?
13 A **What date did you say?**
14 Q I had July 22nd as his scheduled examination with
15 you.
16 A **Yep. Yep. I have a visit scheduled with Mr.**
17 **Benjamin on July 22nd of this year.**
18 Q Okay. And at that time when you examine him, would
19 you be in a position at that point to address
20 issues such as whether or not he's reached maximum
21 medical improvement for the injury that he received
22 treatment from you for?
23 A **Yes.**
24 Q Okay. And during that examination, would you also
25 be in a position, if you find him at maximum

1 medical improvement, to address things such as
2 impairment ratings under the AMA Guides?
3 A **Yes.**
4 Q Okay. All right. Now, let me ask you or talk to
5 you a little bit about what really the main purpose
6 of the deposition here today is. And I know Mr.
7 Chandler's going to have some questions for you as
8 well. But since the last time you were deposed and
9 throughout the course of some litigation in this
10 claim, it's now -- I've become aware, as my client
11 has, that there's an allegation that Mr. Benjamin
12 is suffering from quadriplegia. And I want to talk
13 to you a little bit about that condition generally
14 speaking, and then I want to talk to you
15 specifically about Mr. Benjamin and discuss with
16 you some of your records and some records from some
17 other physicians to get some clarification on that
18 issue. So let me just start by asking you in the
19 context of your area of expertise, if you could
20 define what paraplegia means from the context of a
21 neurosurgeon.
22 A **Yeah. So anytime we use the plegia as the suffix**
23 **in neurosurgical speak, that's complete lack of**
24 **movement. All right? So we use quadriplegia as**
25 **complete lack of movement in four extremities.**

1 Paraplegia is complete inability to move your legs.
2 Hemiplegia is complete inability to move one side
3 of your body.
4 Q Okay.
5 A So I am surprised that he actually has been -- has
6 become a paraplegic.
7 Q Well, that is -- that is the allegation. And Mr.
8 Chandler will touch on this. And obviously one of
9 the reasons that we're asking you to examine him in
10 a couple of weeks is to address this diagnosis
11 which has been given by a physician. And I'll
12 present his record to you in a just a moment. What
13 are the diagnostic criteria that you utilize in
14 order to make a decision or reach a determination
15 that someone is either paraplegic or quadriplegic?
16 A Physical examination.
17 Q Okay. Is that the exclusive criteria or do you use
18 diagnostic testing of any sort?
19 A You can add diagnostic testing, which can
20 potentially be helpful, whether it is you would
21 need to do EMG nerve conduction studies to
22 determine hey, is there no degree of function of
23 the spinal cord below a certain level. So it could
24 be -- it's an additional study that you can use to
25 determine that.

1 Q With regards -- and following up on that, if
2 someone has a plegia, whether it's paraplegia or
3 quadriplegia, what are you generally going to see
4 in an EMG or nerve conduction study with regards to
5 those two conditions?
6 A Yeah. You may see, you know, that the findings
7 will be inconsistent with spinal cord function.
8 And the specifics in terms of amplitudes and
9 things, I would have to leave that to the
10 electrophysiologist or the neurologist who actually
11 performed the EMG and nerve conduction studies.
12 But what you would experience physically, it's a
13 complete lack of movement of the muscles with
14 potentially what's called atrophy, which is
15 deterioration in muscular bulk as time progresses
16 as the muscles become deinnervated from its signals
17 from the spinal cord or the brain, if the brain is
18 what's creating the hemiplegia. The other findings
19 that you can have -- so there's a couple of
20 different types of plegias. One is a flaccid
21 plegia, which there is complete lack of tone. You
22 can also develop a different type of plegia in
23 which the patient actually becomes hypertonic,
24 meaning that their -- their arm or their leg or
25 whatever is plegic becomes stiff. So those are

1 things that you actually determine during your
2 examination.
3 Q Are diagnostic scans, and specifically MRIs, used
4 to diagnose either of the condition paraplegia or
5 quadriplegia, and, if so, what are you looking for
6 in an MRI?
7 A So when you do use an MRI to get to a reason as to
8 why somebody is plegic -- so plegia implies some
9 degree of injury, either to the brain or the spinal
10 cord. What I mean by that is paraplegia or
11 hemiplegia or quadriplegia. So on the MRIs that
12 you make of whichever region you're concerned
13 about, you would look for any signs of destruction
14 or significant compression of the structure that
15 you're concerned about, whether it is the brain or
16 the spinal cord.
17 Q In the course of your treatment of Mr. Benjamin,
18 have you had MRIs of his cervical spine to review
19 as part of your treatment of him?
20 A Yes. I've reviewed multiple.
21 Q And do you have access to those films in your
22 computer that you have?
23 A I do not have access to the direct films. I have
24 access to what I reported I was seeing on those
25 films.

1 Q Okay. Based -- well, if you would not -- if you
2 would mind, maybe, looking at perhaps your initial
3 report of 1/22 of '13, which I believe referenced
4 an MRI that you had available for your review. And
5 I guess my question would be would that MRI and the
6 findings contained therein reflect any form of
7 plegia, whether it be para-, hemi- or quadriplegia?
8 A **So the first thing, you know, in terms of**
9 **developing -- determining from my initial visit on**
10 **January 22nd of 2013 is the physical examination.**
11 **He is not plegic. Okay. And what I mean by that,**
12 **it is by definition somebody who has motor strength**
13 **is not plegic. That's by definition. He had motor**
14 **strength. He had some weakness in his right upper**
15 **extremity, but he walked. He could move. He can**
16 **actually directly be tested in terms of strength.**
17 **He actually had significant strength to even -- he**
18 **had resistance in strength. So by definition from**
19 **just my examination -- I don't need to look at any**
20 **imaging study, any EMG or nerve conduction study.**
21 **I can tell by definition by just examining him that**
22 **he is not plegic.**
23 Q And obviously throughout -- through that physical
24 exam you were able to address, I presume -- did you
25 address things like muscle strength and tone?

1 A That's right. So I documented his muscular
2 strength testing. The MRI of the cervical spine
3 also was documented in terms of the findings, and
4 what I found was what led to my recommendations for
5 surgical treatment.
6 Q Okay. It also appears when he saw you for the
7 first time on January 22nd, and according to your
8 note, you had available to you an EMG nerve
9 conduction study of his upper extremity.
10 A That's right.
11 Q And were there any findings contained within it
12 that were consistent or reflective of a plegia?
13 A No.
14 Q All right. So if I understood you correctly, the
15 neurosurgical community utilizes physical exam,
16 EMG, MRI. Any other diagnostic scan or diagnostic
17 criteria that would be utilized in order to address
18 the presence or absence of a plegia?
19 A Of a plegia, no. That's the majority. So plegia
20 is really initially an evaluation by your physical
21 examination and subsequently you do additional
22 studies to determine the potential cause for the
23 lack of motor function.
24 Q Okay. Doctor, I've marked a collection of records
25 as Defendant's Exhibit Number One. I've provided

1 those records to Mr. Chandler in anticipation of
2 your deposition. I just want to -- in follow up to
3 some of the things that we've talked about, I'm
4 going to show you another EMG nerve conduction
5 study that Mr. Benjamin underwent on March 26th of
6 2015. I just wanted to have you -- if you wouldn't
7 mind reviewing that for me and let me know when
8 you've had a chance to glance over it.
9 Mr. Lockhart: Jeff, these records I sent
10 to you, they were in chronological order so
11 I'm going to try to refer to them by --
12 Mr. Chandler: Yep. I've got them. I've
13 got them.
14 Mr. Lockhart: Yeah. I was going to refer
15 to them by the date so you could find them
16 easily.
17 Mr. Chandler: Yep. Thank you.
18 A **All right. So I'm reviewing an EMG and nerve**
19 **conduction study performed at Grand Strand Spine**
20 **and Neuro dated 3/26/2015 by Dr. Sandoz. And it**
21 **showed just borderline right carpal tunnel syndrome**
22 **and an ulnar -- a mild ulnar sensory neuropathy and**
23 **right cervical radiculopathy. I see no -- nothing**
24 **that would indicate a plegia.**
25 Q Dr. Lozanne, I want to show you -- and I'll take

1 that back. Thank you. I'm going to show you now a
2 -- this is an MRI of the cervical spine performed
3 on or about April 13th of 2015. I want to present
4 this to you and ask you if you just wouldn't mind
5 briefly looking at that as well.
6 Mr. Chandler: And you're just referring
7 to the radiologist's report?
8 Mr. Lockhart: That's correct. I'm sorry.
9 Yeah. I'm sorry, Jeff. Not the actual film.
10 Just the radiologist's report.
11 A **All right. So I'm reviewing the radiology report**
12 **on Victor Benjamin from Florence MRI and Imaging**
13 **dated 4/13/2015, and it shows postsurgical changes**
14 **from the previous anterior cervical discectomy and**
15 **plated fusion from C4 to C7 as well as the**
16 **posterior decompression from C3 to C4 and findings**
17 **that were consistent with MRIs that I had seen in**
18 **the past with some what we call myelomalacia or**
19 **spinal cord signal change of the C3-4 level. I see**
20 **nothing else that is -- that would be consistent**
21 **with a plegia.**
22 Q Doctor, I'm going to also show you -- Mr. Benjamin
23 has also undergone an MRI of his lumbar spine, and
24 I want to present to you a radiologist report from
25 October 19 of 2015. This was an MRI of the lumbar

1 spine recommended by Dr. Poletti. I just want to
2 ask if you could just review that radiology report
3 as well.
4 A **All right. I have a radiology report dated**
5 **10/19/2015, and the opinion of the radiologist at**
6 **the time stated that there is spinal stenosis at**
7 **the L4-5 level of moderate to severe degree.**
8 Q Based on your review of the radiologist's report,
9 are there any findings in that report that are
10 indicative of a plegia?
11 A **No. This is not something that tells us that there**
12 **is a plegia in the patient.**
13 Q You mentioned at the outset of your deposition the
14 relevance of the findings of the physical exam as
15 being one of the diagnostic criteria you use to
16 address the presence or absence of a plegia?
17 A **Right.**
18 Q I want to show you a copy of a report. This is
19 from Dr. Steven Poletti's office. This is from
20 October 2 of 2015 where Mr. Benjamin was seen by a
21 physician's assistant who conducted a physical exam
22 of Mr. Benjamin. I'd ask if you could just review
23 that note, if you would, and in particular the
24 portion of the report addressing the physical exam.
25 A **Okay. I've read the physical examination on this**

1 report.
2 Q Based on your review of the findings as noted by
3 Physician Assistant Anne E. Buck, do the findings
4 of the physical exam of Mr. Benjamin on or about
5 October 2, 2015, are those indicative of or
6 reflective of a plegia?
7 A No.
8 Mr. Chandler: I would object to the form
9 of the question.
10 Q You can answer the question anyway. What, in
11 particular, stands out in your opinion about the
12 portions of the physical exam with regards to the
13 issue of plegia?
14 A Yeah. So when we're discussing plegia, once again,
15 plegia is a lack of function in terms of motor
16 strength and potentially even sensation due to a
17 disconnection, if you want to name it so, from the
18 brain to the affected muscles, whether it's in the
19 spinal cord or the brain, of subsequence. And the
20 first thing you evaluate is the motor strength in
21 the patient. A patient who has strength by
22 definition cannot be plegic. This report states
23 that the strength of the lower extremity is five
24 out of five with hip flexion, dorsi -- and
25 dorsiflexion. It is four out of five in knee

1 flexion, extension and plantar flexion bilaterally.
2 And he has intact motor strength in the upper
3 extremities. This is inconsistent with plegia.
4 Q What would you see, hypothetically, if you were
5 looking at a patient? What would the physical
6 findings reflect, hypothetically, if a patient were
7 plegic?
8 A Lack of movement. So they cannot -- they cannot
9 move the extremities that are affected by the
10 plegia.
11 Q All right. Are bowel and/or bladder disturbance
12 symptoms or byproducts of plegia?
13 A Well, that is a symptom of spinal cord dysfunction.
14 All right. So spinal cord dysfunction can lead to
15 a plegia. So by definition, plegia is the lack of
16 motor or potentially sensory activity in a region
17 of the body. Okay. So that can be brought about
18 by either a brain injury or a spinal cord injury in
19 which all connection below that level has been lost
20 to the rest of the body. And that being the case,
21 because the spinal cord carries all the
22 information, it also goes down towards your bladder
23 and your bowels. Patients that have complete
24 spinal cord injury, -- example, Christopher Reeves
25 -- they will lose function in their bladder and

1 **their -- and their bowels because there's a**
2 **disconnection with the brain's control of those**
3 **regions.**
4 Q All right. During the course of your treatment of
5 Mr. Benjamin, has he ever provided you -- or had he
6 ever provided you with complaints regarding bowel
7 or bladder dysfunction that would be indicative of
8 a plegia?
9 **A No.**
10 Q We mentioned at the outset that you're going to
11 exam him in a couple of weeks. Would you be
12 prepared through the course of your examination to
13 address the issue of whether or not he is plegic by
14 virtue of your physical exam and review of his
15 diagnostic scans?
16 **A Yeah, I can do so. I can make that determination**
17 **from what he's had on his most recent visit. He is**
18 **not plegic on 10/2 of 2015 as he was examined at**
19 **Southeastern Spine Institute.**
20 Q Okay. Doctor, just give me just a few moments. I
21 think I've asked you all the questions I need to.
22 Let me look through my notes before I turn it over
23 to Mr. Chandler. One final question, Doctor. With
24 regards to plegia, whether, again, it being hemi-,
25 quadri-, para-, is that a condition that is

1 generally going to manifest itself rather quickly
2 following an acute injury?
3 A Typically it is. You know, there are other things
4 that can lead to plegia, which is, you know,
5 somebody has a tumor that has grown over time and
6 it's causing significant compression on their
7 spinal cord. The spinal cord itself, as time
8 progresses, as it gets more and more compressed,
9 can develop slow weakness and potentially lead to
10 paralysis. The most common reason why people
11 become paralyzed, plegic, is because of an acute
12 traumatic event that severs the spinal cord or you
13 can develop a hemiplegia from a stroke. That's an
14 acute event in which there's a portion of the brain
15 that was not appropriately given its nutrients,
16 whether it's because there was a bleed or lack of
17 blood flow going to that region of the brain. So
18 it's usually an acute event, but it's not outside
19 the realm of possibilities and it's not -- there
20 are some conditions that can be slow spinal -- an
21 intrinsic spinal cord tumor can lead to a plegia as
22 it grows and envelopes or completely creates
23 dysfunction in the spinal cord as it continues to
24 grow.
25 Q Okay. All right. Doctor, have all the answers

1 that you've given to my questions been in your
2 expert opinion to a reasonable degree of medical
3 certainty?
4 A Yes.
5 Mr. Lockhart: I don't have any further
6 questions. Please answer any Mr. Chandler may
7 have for you.
8 Cross-examination
9 By Mr. Chandler:
10 Q Thank you. Dr. Lozanne, have you ever given a
11 diagnosis to one of your patients or are you
12 familiar with the concept of incomplete
13 quadriparesis?
14 A Yep. Different -- different condition.
15 Q I'm sorry. Did you say that that is a different
16 condition?
17 A That is correct.
18 Q Okay. What is incomplete quadriparesis or
19 incomplete quadriplegia?
20 A All right. So it's an incomplete quadriplegia.
21 You know, if you talk about that with a
22 neurosurgeon, they'll -- it actually sounds like an
23 oxymoron. And what I mean by that is that a
24 quadriplegia by definition in terms of
25 neurosurgical and neurologic training is complete

1 lack of function. So a complete lack of function,
2 there is not -- you know, it's complete. So
3 there's not an incomplete. Now, there are
4 different conditions, and I don't know if you're
5 trying to make a reference to this. But there are
6 different conditions in terms of spinal cord
7 injuries. There are incomplete spinal cord
8 injuries and complete spinal cord injuries, which
9 is a different condition than what we call the
10 plegias. The use of the phrases that you just gave
11 me previously are really unusual. We don't usually
12 use those or those words combined in neurosurgery.
13 So ask me again. Give me the phrase and let me see
14 if I can explain what I think you're trying to get
15 at.
16 Q Well, -- and I'll just refer you. Jason, I think,
17 has that in his Defendant's Exhibit One.
18 A Uh-huh.
19 Mr. Chandler: Jason, it's the reference
20 to the doctor. It's dated 5/27/2015. Could
21 you share that with Dr. Lozanne?
22 Mr. Lockhart: And I'm sorry, Jeff.
23 Mr. Chandler: It's the letter. It's a
24 letter, Jason, --Mr. Lockhart: It's the letter
25 from --

1 Mr. Chandler: -- issued to me.
2 Mr. Lockhart: -- Dr. Poletti?
3 Mr. Chandler: From Dr. Poletti.
4 Mr. Lockhart: Hold on just a moment. I'm
5 getting it right now.
6 Mr. Chandler: Okay.
7 Q I'll show it to you, Doctor, within the context of
8 this letter, if you don't mind.
9 A Say that again.
10 Q I'm going to try to show this to you in the context
11 of the letter --
12 A Sure.
13 Q -- issued by Dr. Poletti.
14 A Sure.
15 Mr. Chandler: Jason, I was just going to
16 direct Dr. Lozanne to page two of that two
17 page letter.
18 A Yeah.
19 Mr. Chandler: And it would be paragraph
20 two on the second page.
21 A Got it.
22 Q Did you find it?
23 A I have the second paragraph. I'm about to read it
24 now.
25 Q Okay. Thanks.

1 A Okay. I see -- I see. I read the paragraph.
2 Q Okay. So you were asking for further clarity as to
3 the -- excuse me. The phraseology, I guess, of
4 incomplete quadriparesis.
5 A Yeah.
6 Q So that's -- that's the way I'm going to present it
7 to you is the way that Dr. Poletti described it --
8 A Yeah.
9 Q -- in his report.
10 A And I understand that so I figured that you've
11 heard it. And I would -- needless to say, this
12 needs to be addressed with Dr. Poletti. And, you
13 know, it's just in terms of the phrases that we're
14 using -- that he is using here, I think it has led
15 to the confusion that has led to all of this, in
16 particular. It's not an appropriate phrase to use
17 an incomplete quadriplegia and potentially in this
18 -- in this condition. Mr. Victor Benjamin has --
19 you know, he has a cervical myelopathy. So he has
20 spinal cord dysfunction that has led to some
21 symptoms, including some difficulties with -- with
22 his balance because he had a spinal cord injury.
23 He does not suffer from a quadriplegia. I've never
24 heard a neurosurgeon -- incomplete quadriplegia
25 used as a phrase in any of my education. And

1 that's -- that's a challenge. I don't know if it's
2 in our, you know, Guides to the Permanent
3 Impairment book, but in neurosurgical training
4 that's not a typical phrase. The diagnosis that
5 Mr. Victor Benjamin suffers from is a cervical
6 myelopathy. He has a spinal cord injury and he has
7 some weakness associated with that and he's not a
8 quadriparetic in the sense that he has normal motor
9 strength in multiple extremities, though he has
10 some decreased strength. At least when I
11 evaluated, he had some decreased strength in his
12 right upper extremity. I see that that apparently
13 has improved on the report from the most recent
14 evaluation, but he has now some -- the last report
15 from Southeastern Spine that I saw, he has a little
16 bit of weakness in his leg, which I didn't
17 appreciate on my evaluations previously. Now, that
18 being the case, he is not a quadriplegic and it
19 would be inappropriate for -- for me as a
20 neurosurgeon to describe him as an incomplete
21 quadriplegic. Paresis is a phrase that we use when
22 there is some weakness. So Dr. Poletti is trying
23 to convey that, you know, he is -- he has some
24 weakness and I'm in complete agreement with Dr.
25 Poletti in that regard. But I'm in disagreement in

1 labeling Mr. Victor Benjamin as an incomplete or
2 complete quadriplegic in any kind of way. And this
3 is just a matter of --
4 Q I think earlier -- go ahead.
5 A Yeah. This is -- this is semantics. Does that
6 make sense? I think this is -- it's just a phrase
7 that's being used here. This is literally
8 semantics.
9 Q Well, let's go into the -- I think what you were
10 alluding to early on in your testimony with me.
11 You said there were things such as complete spinal
12 cord injuries and incomplete spinal cord injuries,
13 is that right?
14 A That's right.
15 Q What would be an example of an incomplete spinal
16 cord injury?
17 A Incomplete spinal cord injury is one in which the
18 function below the level of injury is still
19 present, whether it is motor or sensory.
20 Q Okay.
21 A A complete --
22 Q Is that in play here if Mr. Benjamin continues to
23 have spasticity with his hand and abnormal gait?
24 A That's right. That's right. Okay.
25 Q Okay. So it's your opinion that he suffers from an

1 incomplete spinal cord injury?
2 A **Yeah. He had a spinal cord injury. Most**
3 **definitely. Oh, yeah. Yeah, he had a spinal cord**
4 **injury.**
5 Q So is it deemed an incomplete spinal cord injury as
6 opposed to a complete spinal cord injury?
7 A **By definition, you're correct. Yes, this is an**
8 **incomplete spinal cord injury. That is exactly**
9 **correct.**
10 Q Okay. Look down, Doctor, if you will, to the
11 paragraph before last.
12 A **Yep.**
13 Q This is where Dr. Poletti is describing additional
14 impairment due to station and gait disorder.
15 A **Okay.**
16 Q Do you see that?
17 A **I see it.**
18 Q As a practicing neurosurgeon, have you ever issued
19 impairment under Table 15-6 of the AMA Guides
20 relative to station and gait disorder?
21 A **All right. I have to -- I'll have to pull up the**
22 **Guides here to see the reference to the table,**
23 **okay?**
24 Q Do you have that handy?
25 A **I'll go get it. Give me a second.**

1 Q Okay.
2 A **All right. I've gotten the book. Now, I don't**
3 **know which --**
4 Q Are you in the Fifth Edition or the Sixth Edition?
5 A **I brought both just in case.**
6 Q Okay.
7 A **Which one is he in?**
8 Q He's referencing the Fifth.
9 A **He's the Fifth. All right. Okay. I have the page**
10 **open to Table 15-6.**
11 Q And I'm not trying to put pressure on you to come
12 up with a rating right now because I understand
13 that you're going to evaluate Mr. Benjamin in the
14 coming weeks.
15 A **Okay.**
16 Q I just wanted to ask you if you have ever -- if you
17 have personal recall of whether having ever issued
18 medical impairment pursuant to that table section
19 in your practice before?
20 A **Yes. Matter of fact, I remember one in particular**
21 **had a spinal cord injury and I went -- every time I**
22 **do it, I read the whole chapter and go through**
23 **everything in detail it in my report.**
24 Q Okay. And that's all I was looking for was whether
25 you had done it and, in fact, you utilized that

1 section --
2 A Yep.
3 Q -- in your analysis? All right.
4 Mr. Chandler: Okay, sir. Thank you. I
5 don't have any other questions.
6 Mr. Lockhart: Dr. Lozanne, I don't have
7 any further questions. Thank you for your
8 time.
9 (Whereupon the deposition was concluded at
10 6:17 p.m.)
11
12
13
14
15
16
17
18
19
20
21
22
23
24
25

State of South Carolina )
) Certificate
County of Lexington )

Be it known that the foregoing deposition of Karl Lozanne, M.D. was taken before me;

That I was then and there a notary public in and for the State of South Carolina-at-large;

That by virtue thereof I was duly authorized to administer an oath;

That the witness was by me first duly sworn to testify the truth, the whole truth, and nothing but the truth, concerning the matter in controversy aforesaid;

The foregoing transcript of 26 typewritten pages represents a true, accurate and complete transcription of the testimony so given at the time and place aforesaid to the best of my skill and ability;

That I am not related to nor an employee of any of the parties hereto, nor a relative or employee of any attorney or counsel employed by the parties hereto, nor interested in the outcome of this action.

Signed this 26th day of July, 2016.

Cheri B. Williams

Cheri B. Williams, CVR-M

Notary public for South Carolina
My commission expires May 13, 2025.

This transcript may contain quoted material. Such material is reproduced as read or quoted by the speaker.

Florence Neuro' 'rgery & Spine
1204 E. Cheves Street ~ Florence, S.C. 29506
ph: 843 673 0122 ~ fax: 843 673 0227
www.florenceneurosurgery.com

Andrew H. Rhea, M.D. James J. Brennan, M.D. Elizabeth A. Snoderly, D.O.
William B. Naso, M.D. Christopher G. Paramore, M.D.

Patient Name: VICTOR BENJAMIN (45677E)
DOB:
Date of Service: 06/24/2011

## HISTORY

**Chief Complaint:** Headache

**History of Present Illness:** Mr. Benjamin is a 49-year-old black male was involved in an industrial accident in which he sustained a scalp laceration, a left parietal skull fracture, a closed head injury with concussion, and the right forearm tendon injury. We observed in the hospital. He underwent surgery for his tendon injury. He returns in follow-up today. He says he is having significant headaches. He complains of lightheadedness and dizziness. He also complains of some neck discomfort. He has pain in his right scapular region radiating into his right arm. He says he is supposed to start occupational therapy for his hand. He denies seizure activity.

**Past Medical History:** Hypercholesterolemia

**Past Surgical History:** As above

**Social History:** He is married and has two children. He works as a frontend maintainer. He denies tobacco or alcohol use or abuse.

**Review of Systems:** The patient denies chest pain, shortness of breath, or bowel or bladder incontinence. Please see the health history questionnaire for full details of the patient's review of systems, past medical history, and family and social history. The patient is to follow-up with his family physician for any positive review of systems.

## PHYSICAL EXAMINATION

VITAL SIGNS: BP 139/87 HR 66 RR 14 Temp. 97.9 Ht. 6-foot Wt. 190

NEURO/MUSCULOSKELETAL EXAM

Cognitive: The patient is awake alert and conversant, with fluent speech, normal affect, and fully oriented.

Cranial nerves: Pupils are equal and reactive. Extraocular movements are intact. The face is symmetric. The tongue is midline.

Motor exam: Both upper and lower extremities have normal bulk and normal tone with 5/5 strength throughout, including the left grip and both biceps, triceps, deltoids, iliopsoas, quadriceps, hamstrings, gastrocnemius, and anterior tibialis motor groups with good range of motion throughout. His right forearm and hand are in a splint.

Gait: No ataxia.

Florence Neuro[illegible]rgery & Spine
1204 E. Cheves Street ~ Florence, S.C. 29506
ph: 843 673 0122 ~ fax: 843 673 0227
www.florenceneurosurgery.com

Andrew H. Rhea, M.D. James J. Brennan, M.D. Elizabeth A. Snoderly, D.O.
William B. Naso, M.D. Christopher G. Paramore, M.D.

Patient Name: [illegible]ICTOR BENJAMIN (45677E)
DOB: [illegible]
Date of Service: 06/24/2011

## MEDICAL DECISION MAKING

**Assessment/Diagnoses:** 1. Postconcussive syndrome 2. Parietal skull fracture 3. Neck pain with cervical myofasciitis

**Recommendations/Management Options:** We will proceed with cervical spine x-rays with flexion-extension views. Given his head injury and persistent headache and postconcussive symptoms I would recommend an MRI of the brain to make sure there has been no interval development of any extra-axial collections (particularly given his skull fracture) but also to see if there is any evidence for parenchymal injury. I think he would be a good candidate for vestibular rehab. We have also given him a prescription for Skelaxin may help with his myofascial complaints. We removed his scalp staples and left shoulder sutures as well.We will otherwise see him back in the office in 3 to 4 weeks. I discussed at length with the patient's case manager the patient's diagnosis, prognosis, and treatment plan. This was done in the patient's presence.

**Addendum:** AP, lateral, flexion and extension cervical spine x-rays were obtained. There is loss of the normal lordosis. There is degenerative disc disease throughout the cervical spine but no significant C5-6. There is an anterior osteophyte at C3-4. There is maintained in alignment from C1 to C7-T1. There is no gross instability with flexion and extension. I do not see any obvious fractures.

cc:

Electronically Signed by: William B. Naso, M.D. on Friday, June 24, 2011 1:22 pm

GRAND STRAND
SPECIALTY ASSOCIATES
NEUROLOGY

Neurology:
Jeff A. Benjamin, D.O.
Barbara L. Sarb, D.O.
Michael McCaffrey, M.D.

Neurology & Ophthalmology:
George M. Sandoz, M.D.

| | |
|---|---|
| PATIENT: | Victor Benjamin |
| DATE OF BIRTH: | |
| DATE: | 09/16/2011 11:00 AM |
| VISIT TYPE: | Consultation |

**Chief Complaint/Reason for visit:**
This 49 year old male presents with head injury, neck pain and dizziness.

**History of Present Illness**

1. head injury

Onset: sudden. The severity of the symptoms is moderate. The symptoms have not changed. Ventilator support was not used in the hospital. The location of the injury is in the left parietal region. The location of pain is facial, head and neck. The mechanical force causing the injury was coup. Context includes metal guard hit head. The patient does not use alcohol. There are no risk factors. Aggravating factors include exertion, lying down, sound and touch. Denies relieving factors. Associated symptoms include confusion, headache, incoordination, irritability, loss of consciousness, memory difficulty, personality change, restlessness, speech difficulty, stiff neck, unusual behavior, visual disturbance and weakness. Additional information: event on 6-15-11, was control panel, amnestic for event and skull fracture left.

2. neck pain

Onset: sudden. The severity of the problem is moderate. The problem has worsened. The frequency of pain is daily. Location of pain is bilateral posterior neck. There was radiation of pain to the left upper arm, left elbow and left forearm. The patient describes the pain as aching and burning. The event(s) surrounding the occurrence of the symptom include 30 lbs metal guard hit head. Trauma occurred on 06/15/2011. Aggravating factors include climbing stairs, flexion, hyperextension, kneeling, lifting, lying down, walking and working. Denies relieving factors. Associated symptoms include difficulty sleeping, disequilibrium, muscle spasm, numbness, other joint pain, tenderness and tingling. Pertinent negatives include bladder retention.

3. dizziness

Onset was sudden. Severity is moderate. The duration of each episode is Month(s). The problem is unchanged. It occurs persistently. The patient describes it as (an) imbalance and spinning. It occurs while. The patient has sustained a head injury in the past. Symptom is aggravated by rapid rise and turning. Relieving factors include position change. Associated symptoms include hearing loss, loss of consciousness, neck stiffness, paresthesias and tinnitus. Pertinent negatives include diplopia or ear ache.

**Vital Signs**

**Height**

| Time | Ft | In | Cm | Last Measured | Method | % |
|---|---|---|---|---|---|---|
| 12:07 PM | 6.0 | | | | | |

**Weight / BSA / BMI**

| Time | Lb | Oz | Kg | Context | % | BMI | BSA |
|---|---|---|---|---|---|---|---|
| 12:07 PM | 164.00 | | | | | 24.95 | |

**Blood Pressure**

| Time | BP | Position | Side | Site | Method | Cuff Size |
|---|---|---|---|---|---|---|
| 12:07 PM | 140/78 | sitting | | | | |

Benjamin, Victor

**Measured By**
Time
12:07 PM Penny Powers

Physical Exam
**Constitutional:**
Level of distress is moderate distress. Well nourished. Well developed.
**Eyes:**
Right
Fundus is benign.
Left
Fundus is benign.
**Ears:**
Right
Normal tympanic membrane.
Left
Normal tympanic membrane.
**Vascular:**
Bruits
Carotid bruits: absent.
**Musculoskeletal:**
Cervical spine has muscle spasm, moderately reduced ROM
Lumbar spine has muscle spasm
**Neurological:**
Level of Consciousness: Normal.
Orientation: Alert and oriented X 3. Grossly normal intellect. .
Memory: Intact. .
Cranial nerves: II-XII grossly intact. .
Trigeminal:
Motor and Reflexes: normal.
Facial: normal.
Acoustic: Weber test abnormal, lateralizes to the right
Glossopharyngeal: normal.
Vagus: normal.
Spinal Accessory: normal.
Hypoglossal: normal.
Sensory: No sensory loss. .
Motor: No motor weakness. .
Balance & Gait: Balance and gait intact. .
Coordination: Coordination intact. .
Fine Motor: Skills normal. .
Biceps deep tendon reflex is 2+ on the right and 1+ on the left,
Brachioradialis deep tendon reflex is 2+ bilaterally.
Triceps deep tendon reflex is 2+ bilaterally.
Patellar reflex is 2+ bilaterally.
Achilles reflex is 2+ bilaterally.
Brudzinski's sign: Negative.

Clinical Assessment
The patient is a 49-year old male who presents with head injury, neck pain and dizziness. Having some difficulty with ambulation. Needs some assistance with ADLs.

Assessment/ Plan
**Intracranial injury of other and unspecified natur (854.01)**
From traumatic injury will check mri brain perform neuropsych testing and trial with Lamictal for moodstabilazer.
**Memory loss (780.93)**
Due to injury or ptsd, eeg will be perform.
**Dizziness (780.4)**
Due to injury causing damage on innerr ear, will give medizine and exercisses, will check nystagmogram.
**Headache (784.0)**

Benjamin, Victor

Post rauma in nature, trial with Nucynta.
Pain-neck (723.1)
Due to trauma, ncs and mri cervical spine as well for pt, pain control with nucynta.
Pain-limb (729.5)
Due to trauma, consult with orthopedic surgeons.

**Office Services**

| Status | Order | Reason | Interpretation | Value |
|---|---|---|---|---|
| completed | Adequate nutritional intake | | | |
| completed | Patient agrees with treatment plan & instructions | | | |

**Instructions / Education**

| Status | Completed | Order | Reason |
|---|---|---|---|
| completed | 09/21/2011 | Risks/ benefits of treatment plan | |
| completed | 09/21/2011 | Reviewed medications | |
| completed | 09/21/2011 | Activity as tolerated | |
| completed | 09/21/2011 | Take new medication as prescribed | |

**To be scheduled/ordered**

| Status | Order | Reason | Assessment | Timeframe | Appointment | |
|---|---|---|---|---|---|---|
| scheduled | Office visit | Continue current treatment | | 854.01 | -today | 09/21/2011 |
| ordered | MRI C- SPINE W/O DYE | | 854.01 | | 09/21/2011 | |
| ordered | MRI BRAIN W/O & W/DYE | | 854.01 | | 09/21/2011 | |
| ordered | AUDITOR EVOKE POTENT, COMPRE | | | 780.4 | 09/21/2011 | |
| ordered | SPONTANEOUS NYSTAGMUS TEST | | | 780.4 | 09/21/2011 | |
| completed | Follow-up if symptoms persist / worsen | | | 854.01 | 09/21/2011 | |
| completed | Follow-up for increased symptoms | | 854.01 | -today | 09/21/2011 | |
| ordered | EEG MONITORING/COMPUTER 24hr | | | 780.93 | 09/21/2011 | |
| ordered | MUSCLE TEST, ONE LIMB | | 854.01 | | 09/21/2011 | |
| scheduled | Office visit | Discuss test results | | 854.01 | -today | 09/21/2011 |
| scheduled | Office Visit | Follow-up on medication | | 854.01 | -today | 09/21/2011 |
| completed | Follow-up for medication side effect | | 854.01 | -today | 09/21/2011 | |

George M. Sandoz MD

Document generated by: George Sandoz 09/21/2011

Grand Strand Specialty Associates
8170 Rourk Street, Myrtle Beach, SC 29572

Benjamin, Victor

# COLUMBIA NEUROSURGICAL ASSOCIATES, P.A.

www.columbianeurosurgical.com

Spine & Neurological Surgery

Thomas J. Holbrook, Jr., MD
William M. Rambo, Jr., MD
Randall G. Drye, MD
Scott B. Boyd, MD
Brett C. Gunter, MD
Karl A. Lozanne, MD

720 Rabon Road
Columbia, SC 29203
(803) 462-0423 - (F) 462-0432

Pain Medicine
Eva J. Rawl, MD

132 Sunset Court
W. Columbia, SC 29169
(803) 794-3700 - (F) 794-0322


**OFFICE CONSULTATION**

Patient: Victor G. Benjamin
Chart:
DOB:
Date: 1/22/13

CHIEF COMPLAINT: Neck pain, right-sided arm pain, bilateral arm numbness and tingling, imbalance.

HISTORY OF PRESENT ILLNESS: Victor Benjamin is a 50-year-old male who works for Rexam, a can manufacturing company. On 6/15/11, he suffered a work-related injury in which a metal piece from the machine he was working on fell on top of his head and onto his shoulder. Per report, the metal piece weighed over 20 pounds. He lost consciousness and was treated for a laceration to his scalp, his concussion, as well as his shoulder and right arm injury. He underwent right arm tendon repair.

He has continued to struggle with headaches, neck pain, right-sided interscapular and shoulder pain that radiates down into his right arm. He has developed difficulties with his balance and has had numbness and tingling worse on the right than the left. He has developed weakness in the right upper extremity. He denies any urinary or bowel symptoms. He has been managed with oral analgesics, physical therapy and more recently epidural steroid injections. The epidural steroid injections initially were effective at relieving his right-sided arm discomfort but the pain has returned. He underwent an MRI of the cervical spine which revealed significant cervical stenosis with disc/osteophyte complexes as well as what appeared to be spinal cord signal change. He was seen by another surgeon who recommended to undergo a surgical intervention. He presents to me for consultation and further discussion of treatment options.

HISTORIES: Please see patient history form for medications/allergies, past medical history, social history, family history, and review of systems which are well documented in the intake sheet dated 1/21/13 and have been reviewed and signed. The information contained is noncontributory except for that in the HPI. He lists no other past medical history. He had a right arm tendon repair in June 2011 at McLeod Hospital in Florence.

He has been out of work since his work-related injury. He is married with two children. He denies any tobacco use.

PHYSICAL EXAMINATION: Awake, alert, and oriented with normal and appropriate speech. Cranial nerves: VFF on confrontation. EOMI. Facial sensation and movements are symmetric. Hearing is normal. Palate elevates symmetrically and tongue protrudes in the midline. Motor: 4+/5 in the right deltoid, bicep, tricep, hand intrinsics. All other muscle groups are 5.5. Sensory: Decreased to light touch in left-sided C7 and C8 distributions. He is globally hyperreflexive with positive Hoffmann's sign bilaterally and two beats of clonus bilaterally. Reflexes: 4+ at the patellas, 3+ at the Achilles, with 3+ bilateral bicep and tricep reflexes. No Babinski or Hoffmann's sign present. Gait is normal. Finger-to-nose testing is normal.

DIAGNOSTIC STUDIES: EMG/nerve conduction study performed 11/3/11 at that time revealed a moderate degree of carpal tunnel syndrome in the right upper extremity as well as an ulnar neuropathy in the right upper extremity.


RECEIVED

FEB 1 8 2013

Per

IMAGING STUDIES: MRI of the cervical spine performed 11/15/12 is available for my direct review. It comes on CD from Florence MRI and reveals what appears to be a small degree of spinal cord signal change at the C3-4 level. He has a generally narrow canal. At C3-4 I see a mild disc bulge with osteophytes and a mild degree of central canal stenosis. However, at C4-5, C5-6 and C6-7 he has disc/osteophyte complexes with a moderate degree of right-sided lateral recess and foraminal stenosis at 4-5 and 5-6 and a severe amount of lateral recess and foraminal stenosis on the left side at C6-7.

IMPRESSION/PLAN: Mr. Victor Benjamin suffered a work-related injury in June of 2011 and has presented to me with cervical myelopathy as well as signs and symptoms of cervical radiculopathy in both the right and left thumb. Imaging studies reveal multi-level degenerative disease with disc/osteophyte complexes at C4-5, C5-6 and C6-7 consistent with his signs and symptoms.

Considering his condition, I have recommended surgical intervention in the form of an anterior cervical discectomy and plated fusion at C4-5, C5-6 and C6-7. It is my opinion that the C3-4 level does not require any surgical intervention at this time because I am not seeing any significant neural compression despite the fact that it does appear that there is some spinal cord signal change at this level. I suspect that this is from his initial injury and contusion. Nonetheless, he is still manifesting radiculopathy and cervical myelopathy.

The surgical procedure offered was described in detail with the aid of models and diagrams. We discussed the potential benefits, treatment alternatives, and risks which include, but are not limited to: worsening of current status, the possible need for further procedures, the risk of infection, headaches, CSF leak, possible spinal nerve injury resulting in paralysis, infection, neck hematoma, hoarseness of voice, injury to major vessels causing hemorrhage, stroke, loss of language function, coma, and even death. No assurance was given whether symptoms would improve following the procedure. The patient voiced understanding of these risks and decided to proceed with the proposed procedure.

Mr. Benjamin does wish to proceed with surgery. I have discussed this in the company of the case manager, Ms. Rena Spencer. We will schedule this procedure at his convenience. He does understand that the surgical procedure itself is aimed at relieving pressure on the central canal as well as the nerve roots but not one that is going to result in complete recuperation of spinal cord function. There is the possibility he may continue to struggle with discomfort considering his injury. They displayed full understanding of this and wish to proceed. They do understand that he should refrain from any activities with the potential of head and neck injury which could result in worsening spinal cord function. They agree to comply.

Karl Lozanne, MD

Karl A. Lozanne, MD
THIS DOCUMENT HAS BEEN ELECTRONICALLY SIGNED
KAL/MAH CNAWT:

Grand Strand Spine & Neuro Ctr.
8170 Rourke Street
Myrtle Beach, SC 29572
(843) 449-2336

Patient: Benjamin, Victor
Sex: Male
Age: 52
I.D.#:
Ref. M.D.:

Physician: Dr Sandoz
Test Date: 03/26/15

History/Comments:

DOB 04-19-62 Intervetrebral disc disorder with myopathy of cervical region

Motor Nerve Study

| Right Median Nerve<br>Rec Site: APB<br>Stim Site | Lat (ms) | Norm Lat | Amp (mV) | Norm Amp | C.V. (m/s) | Norm C.V. |
|---|---|---|---|---|---|---|
| Wrist | 3.4 | 4.5 | 8.8 | 3 | | 48 |
| Elbow | 8.8 | | 8.6 | | 50.3 | |

| Right Ulnar Nerve<br>Rec Site: ADM<br>Stim Site | Lat (ms) | Norm Lat | Amp (mV) | Norm Amp | C.V. (m/s) | Norm C.V. |
|---|---|---|---|---|---|---|
| Wrist | 3.3 | 3.6 | 12.6 | 5 | | 48 |
| B.Elbow | 6.8 | | 11.3 | | 84.4 | |
| A.Elbow | 8.2 | | 9.0 | | 70.8 | |

Sensory Nerve Study

| Right Median Nerve<br>Rec Site: Wrist<br>Stim Site | Norm Lat | Pk Lat (ms) | Amp (uV) | Norm Amp |
|---|---|---|---|---|
| Thumb | 2.3 | 2.3 | 58.9 | 40 |
| Index | | 2.3 | 48.2 | |

| Right Ulnar Nerve<br>Rec Site: Wrist<br>Stim Site | Norm Lat | Pk Lat (ms) | Amp (uV) | Norm Amp |
|---|---|---|---|---|
| 5th dig | 2.2 | 2.6 | 14.7 | 11 |
| Ring | | 2.3 | 13.0 | |

| Right Radial Nerve<br>Rec Site: Wrist<br>Stim Site | Norm Lat | Pk Lat (ms) | Amp (uV) | Norm Amp |
|---|---|---|---|---|
| Index | 2.7 | 2.1 | 21.7 | 15 |
| | | 2.1 | 26.3 | |

Patient: Benjamin, Victor Test Date: 03/26/15
I.D.#:

**F-Wave Study**

| Right Median Nerve<br>Rec Site: APB<br>Stim Site: Wrist | Latency<br>ms | Normal<br>Latency |
|---|---|---|
| M wave | 3.75 | |
| F wave | 29.92 | 32 |

| Right Ulnar Nerve<br>Rec Site: ADM<br>Stim Site: Wrist | Latency<br>ms | Normal<br>Latency |
|---|---|---|
| M wave | 3.33 | |
| F wave | 31.33 | 32 |

**EMG Study**

| Name | Ins Act | Fibs | PSW | Fascics | Polyph | MU Amp | MU Dur | Config | Pattern | Recruit |
|---|---|---|---|---|---|---|---|---|---|---|
| R. Pronator Ter. | norm | none | none | none | none | norm | norm | norm | norm | norm |
| R. Biceps Brachi. | norm | none | none | none | none | norm | norm | norm | norm | norm |
| R. Triceps | norm | none | none | none | none | norm | norm | norm | norm | norm |
| R. Deltoid | norm | none | none | none | none | norm | norm | norm | norm | norm |
| R. Ext Carp Uln | norm | none | none | none | none | norm | norm | norm | norm | norm |
| R. Flex Dig Prof | norm | none | none | none | none | norm | norm | norm | norm | norm |
| R. ADQ | norm | none | none | none | none | norm | norm | norm | norm | norm |
| R. Dors.Int.1 | norm | none | none | none | none | norm | norm | norm | norm | norm |
| R. Abd.Pol.Br. | norm | none | none | none | none | norm | norm | norm | norm | norm |
| R. Low Cerv Para | inc | 3+ | 3+ | none | none | norm | norm | norm | norm | norm |

**Summary/Interpretation:**
Right median CMAP normal distal latency, amplitude, and conduction velocity. F-waves normal.
Right ulnar CMAP normal distal latency, amplitude, and conduction velocity. F-waves normal.
Right median SNAP borderline distal latency and normal amplitude.
Right ulnar SNAP prolonged distal latency and normal amplitude.
Right radial SNAP normal distal latency and amplitude.

Needle electromyography examination of the right upper extremity and right cervical paraspinal muscles demonstrated: Increased insertional activity and 3+ fibs and PSW at the right low lumbar paraspinal muscles.

Impression: 1. Borderline right sensory CTS.
2. Mild right ulnar sensory neuropathy at the wrist.
3. Right cervical radiculopathy.
4. Clinical correlation is recommended.

George Sandoz, M.D.

Patient: Benjamin, Victor
I.D.#:

Test Date: 03/26/15

R. Median MNC

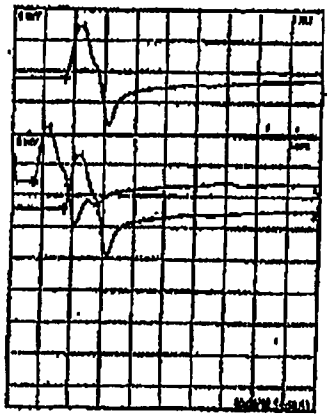

R. Ulnar MNC

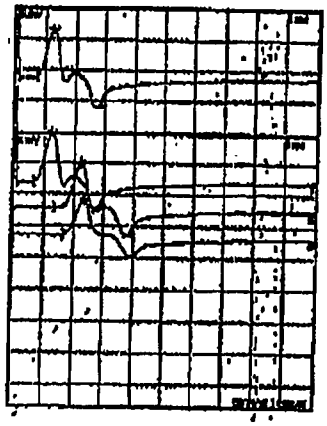

R. Median SNC

R. Ulnar SNC

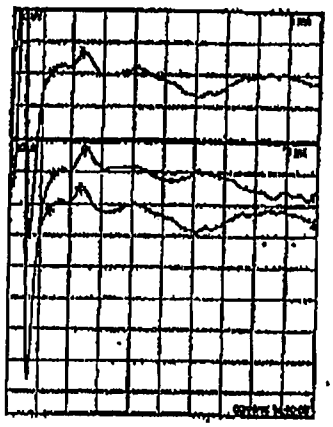

R. Radial SNC

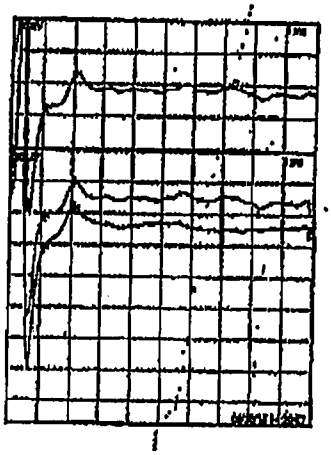

R. Median F-wave

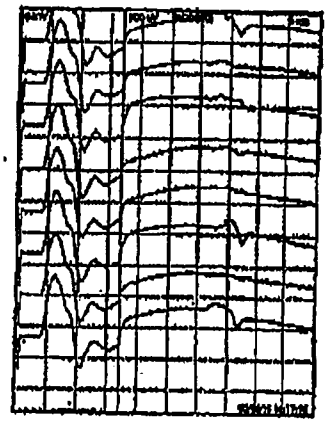

R. Ulnar F-wave

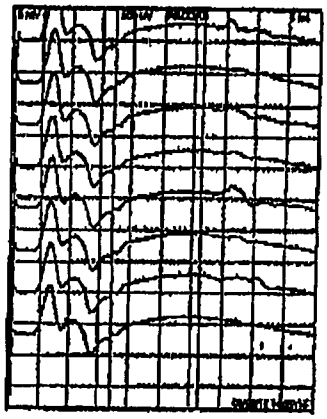

Grand Strand Spine & Neuro Ctr.
8170 Rourke Street
Myrtle Beach, SC 29572
(843) 449-2336

Patient: Benjamin, Victor
Sex: Male
Age: 52
I.D.#:
Ref. M.D.:

Physician: Dr Sandoz
Test Date: 09/26/15

**History/Comments:**

DOB 04-19-62 Intervertebral disc disorder with myopathy

**Evoked Potential Study**
Left Median Nerve

| Set | Sweeps | Lat (ms) N7 | Lat (ms) N13 | Lat (ms) N17 | Lat (ms) N20 |
|---|---|---|---|---|---|
| | 504 | 8.0 | 16.6 | 18.1 | 23.1 |
| | 507 | | | | |

**Evoked Potential Study**
Right Median Nerve

| Set | Sweeps | Lat (ms) N7 | Lat (ms) N13 | Lat (ms) N17 | Lat (ms) N20 |
|---|---|---|---|---|---|
| | 503 | 11.8 | 14.9 | 20.4 | 25.8 |
| | 506 | | | | |

**Evoked Potential Study**
Left Tibial Nerve

| Set | Sweeps | Lat (ms) N7 | Lat (ms) N17 | Lat (ms) N20 | Lat (ms) P42 | Lat (ms) N50 | IPI1 (ms) N7-P42 | Amp1 (uV) P42-N50 | Amp2 (uV) N7-N17 |
|---|---|---|---|---|---|---|---|---|---|
| | 500 | 3.5 | 16.6 | 23.7 | 44.0 | 53.8 | 40.5 | 0.5 | |
| | 500 | | | | | | | | |

Patient: Benjamin, Victor Test Date: 03/26/15
I.D.#:

L. Median HP

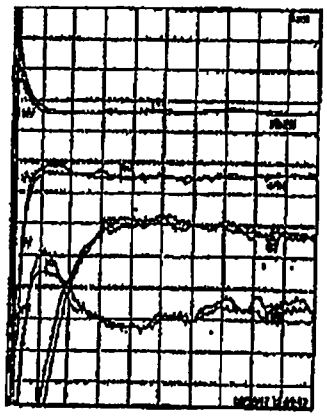

R. Median HP

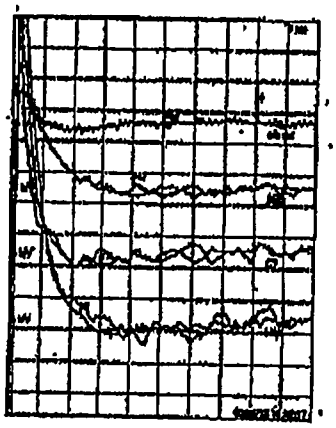

L. Tibial EP

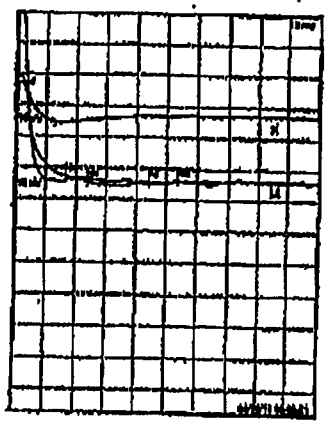

R. Tibial EP

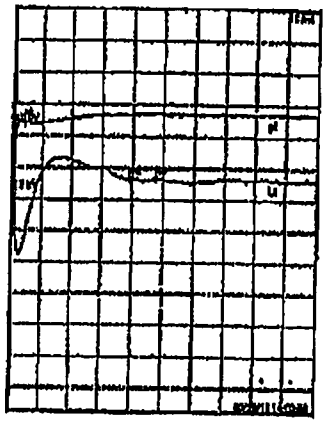

Patient: Benjamin, Victor Test Date: 03/26/15
I.D.#:

Evoked Potential Study
Right Tibial Nerve

| Set | Swaps | Lat (ms) N7 | Lat (ms) N17 | Lat (ms) N20 | Lat (ms) P42 | Lat (ms) N50 | IPI1 (ms) N7-P42 | Amp1 (uV) P42 - N50 | Amp2 (uV) N7-N17 |
|---|---|---|---|---|---|---|---|---|---|
| | 500 | 3.8 | | | 39.2 | 47.5 | 35.3 | 0.3 | |

Summary/Interpretation:
The Upper/Lower Extremity Somatosensory Evoked Response Tests are within normal limits. Clinical correlation is recommended.

George Sandoz, M.D.

Grand Strand
HEALTH SYSTEM
Spine & Neuro Center

Neurology
Jeff Benjamin, DO
Michael McCartney, MD
Barbara Sands, DO
Neurosurgery
Jeremy Cummins, MD
Brian Kelly, PA-C
Kemp Kernan, ANP
Multiology and Orthopedic Oncology
Orthopaedic Surgery/Traumatology
Christopher Plumlee, DO
Kimberly Parker, PA-C

Patient MRN:

Date: 05/15/2015

Category: Dictation

Description: Sarb dictation

Provider ID:C706AC9B-07A5-4436-9BD0-99AC04AF5CE2

Transcription Date: May 15, 2015

Victor Benjamin
DOB:
Chart:
Date: 5/15/2015
Neurology New Patient Evaluation

**HISTORY OF PRESENT ILLNESS:** Mr. Benjamin is seen in evaluation at the request of Dr. Sandoz. He has had epidurals back in November and did really well. He has a back injury related to work injury four years ago. He states a steel guard 35 feet and hit him on his head and he fell backward injuring his back. He fell on to his right side. He has disc L4-L5 with moderate facet disease, disc protrusion with moderate-to-severe recess stenosis. He did really well with his epidural for about three to four months. He has return of low back pain radiating down the right buttock on lateral aspect right to the foot with numbness. He has tried physical therapy in the past with little relief. He is using a cane. Pain is worst on the right. He does not reflex his activities of daily living. He describes it is moderately severe and did waxes and wanes depending on his activity. He still to continue his leakage worse. He would like to proceed with epidural for pain management.

**MEDICATIONS:** He is on citalopram, Vimpat, clonazepam, hydrocodone, Diovan, Norvasc.

**ALLERGIES:** Unchanged DEMEROL.

Victor Benjamin
DOB:
Chart:
Date: 5/15/2015
Page 2

**PHYSICAL EXAM:**
**VITAL SIGNS:** Blood pressure 130/74, pulse 68, temperature 98.3, and weight 167 pounds.
**HEENT:** Patient is normocephalic.
**LUNGS:** Clear.
**HEART:** Regular rate and rhythm. No carotid, orbital or cranial bruits.
**ABDOMEN:** Soft.
**EXTREMITIES:** Without clubbing, cyanosis or edema.

**NEUROLOGICAL EXAMINATION:**
**MENTAL STATUS:** Patient is awake, alert and oriented to person, place, and time. Speech is clear and fluent. Mentation is appropriate for age. Conversation is fluent.
**CN II-XII:** PERRLA. EOMI. Full visual fields with confrontation. Funduscopic exam is normal with no evidence of papilledema or hemorrhage. Spontaneous venous pulsations are seen. Facial sensation is intact to pinprick. Muscle of mastication are strong with symmetrical facial expressions. Hearing is intact to conversation. Soft palate elevated symmetrically with midline protrusion of the tongue. Gag is intact. Sternocleidomastoid and trapezius strength is symmetric.
**MOTOR:** Strength is 5/5 in the upper and lower extremities with normal muscle bulk and tone. There is no evidence of tremor or abnormal involuntary movement.
**SENSORY:** Sensation is intact totemperature, vibration and position sense. There is no truncal sensory level. The patient has decreased sensation pinprick diffusely over right leg. SLR testing mildly positive with complaint of pain in the right leg down the lateral aspect of the leg.
**DTRs:** 2/4 in the upper and lower extremities with downgoing plantar response.
**CEREBELLAR:** There is an intact finger-nose-finger, rapid alternating movements and heel-to-shin testing.
**MECHANICAL SPINE:** Spine is normal, no evidence of curvatures or tenderness to palpation. Negative straight leg, cross straight leg, popliteal compression, and femoral stretch.
**GAIT:** Antalgic.

**MEDICAL DECISION MAKING:** The patient with right L4-L5 radiculopathy. I recommend repeat lumbar epidural injection for pain management. He responded well to it in the past. He is on pain medicines and he has tried physical therapy in the past without relief. Risks and benefits were discussed. The patient will need transportation home and limited activity 48 hours postinjection.

Victor Benjamin
DOB:
Chart: _____
Date: 5/15/2015
Page 3



Barbara L. Sarb, DO

BS/fsh

Electronically Signed on 05/21/2015 10:54 AM

The End.

Barbara Sarb

Main Campus
1106 Chuck Dawley Blvd.
Mt. Pleasant, SC 29464
1112 Chuck Dawley Blvd.
Mt. Pleasant, SC 29464

(843) 849-1551
Fax (843) 884-0619
1-800-432-0274

Spinal Surgery
Donald R. Johnson, II, MD
Steven O. Palmer, MD
R. Blake Daniels, MD
Richard P. Hirsch, MD
Thomas K. Anderson, MD
Daniel R. Butler, PA-C
Justin G. Swain, PA-C
Courtney Z. Beck, PA-C
G. Ryan Apel, PA-C
Liza Tuggle, PA-C
Amanda Hardaway, PA-C

Conservative Spine Care
Leonard E. Forrest, MD
John P. Johnson, MD
G. Robert Richardson III, MD
Kristal W. Loeffler, PA-C
Carolyn Hyre, PA-C
Stephen Fixton, PA-C

Pain Management
Mark D. Nelkenbrecher, MD
W. Ross Richardson, MD
Virginia O. Ekers, PA-C
Kathleen E. Zubowsky, PA-C
Christina Chandler, PA-C

Neuroradiology
Richard C. Holgate, MD

Affiliated Physicians

Neurology-Intracranial Vascular
Neurocomputing
George "Troy" Lee, MD

Vascular Spine
Access Surgery
Thomas C. Appleby, MD

Date: 5/27/2015
Re: Victor Benjamin
DOB:
MRI

Jeffrey C. Chandler, P.C.
Chandler Law Firm
P.O. Drawer 1889
Myrtle Beach, SC 29578-1889

Dear Mr. Chandler:

I first saw Mr. Benjamin at the request of Dr. Sandoz in November of 2012. He had severe spinal stenosis at the C3-4 level after an accident, which rendered him unconscious. He has obvious spinal cord compression and bruising of the spinal cord or myelomalacia. It was recommended that he consider surgical intervention; and he was ultimately sent to Dr. Lozanne where he had surgery at C4-5, C5-6, and C6-7 but did not have surgery at C3-4. He developed progressive spondylosis or disc space collapse at the C3-4 level with worsening of stenosis at the C3-4 level but more importantly continued presence of spinal cord edema or bruising. On his physical examination, he was developing progressive loss of use of his upper extremities with an altered gait and imbalance.

I saw Mr. Benjamin on 1/21/12 with the MRI scan showing the edema within his spinal canal and believed that he should consider surgery, and I felt absolutely that he should not do any type of therapy and that surgery was mandatory. He underwent the operative intervention on what I would describe as an urgent basis in February of 2014 to involve posterior cervical decompression and fusion. Dr. Lozanne saw the patient, and I received records from him noting that he saw myelomalacia or spinal cord edema at the C3-4 level. Dr. Lozanne did state that the spinal cord itself "looked to have been damaged to some degree at the C3-4 level".

I would invite really any neurosurgeon or neuroradiologist to review the MRI scan from January 20, 2014; and I think it would be obvious that there is severe stenosis at the C3-4 level. When comparing the stenosis with spinal cord compression at the C3-4 level on the MRI scan from January 20, 2014 compared to the MRI scan from October 15, 2012, it is clearly worse at the adjacent level after the fusion. I would describe his problem as obviously surgical and obviously

Patient Name: Benjamin, Victor
Account number:
DOB:
Encounter Date: 5/27/2015

urgent. I honestly don't know of anyone who would feel different in terms of worsening cervical stenosis with spinal cord compression and evidence of myelomalacia. Apparently there is some determination by the Workman's Compensation Commission that operative intervention was either not urgent or necessary in 2014. I would respectfully opine that I don't know of a spinal surgeon who would have that opinion.

Suffice it to say this man had a serious or catastrophic neurologic injury. He has signs and symptoms of upper and lower extremity weakness. This type of spinal cord edema or compression is what commonly would be referred to as incomplete quadriparesis or as a form of incomplete quadriplegia. He has a disabling problem that will prevent him from walking normally or using his hands normally for fine motor activities. He is obviously permanently disabled from returning to any type of employment and meets what I would describe as the necessary criteria for pursuing Social Security disability.

With regards to the urgency of the clinical situation for Mr. Benjamin, when you have spinal stenosis of this severity with edema or bruising in the spinal cord, if you don't decompress the stenosis the patient's symptoms will get worse. Again, I would invite this man's imaging studies and clinical records to be reviewed by any other spinal or neurosurgeon; and I'm confident that their opinion would match mine with regards to the urgent nature of the surgery and its absolute necessity.

Specifically with regards to impairment, Mr. Benjamin has undergone a multilevel fusion operation. Specific impairment would be due to alteration of motion-segment integrity requiring fusion. This would be per DRE Cervical Category IV. He would have a 28-percent impairment rating.

With regards to impairment in addition from the spinal cord injury as both I and Dr. Lozanne have described, he has additional impairment not only from the fusion but from the myelomalacia or spinal cord compression. He has station and gait disorders and impairment to both his upper and lower extremity. He is limited to level surfaces of walking and has criteria for impairment due to station and gait disorder, and he does not have digital dexterity in his hands as a consequence of the injury. Impairment with regards to whole-person impairment, which is in addition for criteria of impairment for the upper extremities, is per table 15-6, page 396 of the AMA Guides for Permanent Impairment Fifth Edition. This would be an additional 39-percent whole-person impairment rating and is added to the previous impairment. Therefore, his total numerical impairment is 67 percent to the whole person.

Again, this man has a form of spinal cord injury or incomplete quadriplegia, and this is the rationale behind him having this level of disabling impairment and injury. Again, my opinions are held to a reasonable degree of medical certainty. I would be glad to see him back at any time.

Sincerely,

Steven C Poletti MD

SCP/dmp

Grand Strand
HEALTH SYSTEM
Spine & Neuro Center

Patient MRN:

Date: 06/19/2015

Category: Dictation

Description: Dr. Sandoz dictation

Provider ID:5E9A3D51-EE73-459E-B82D-A3BF8251CF0E

Transcription Date: June 19, 2015

June 19, 2015

Mr. Jeff Chandler
Chandler Law Firm
PO Box 1889
Myrtle Beach, SC 29578-1889

RE: Victor Benjamin
DOB:
Chart:

SSN:

To Whom It May Concern:

Mr. Benjamin is a patient of mine, who I saw for the first time on 09/16/2011 after being involved in a work-related injury on 06/15/2011. As a result of this injury, the patient has suffered cervical disc injury that has left him with myelomalacia and he has been undergoing care by Dr. Poletti. I agree with the impairment rating given from the spinal cord injury and from the spinal cord lesion that he has. From the neurological standpoint, the patient has also been complaining of a headache. This headache, after

8170 ROURK STREET • MYRTLE BEACH, SOUTH CAROLINA 29572
TELEPHONE: 843.449.2336 • FACSIMILE: 843.497.2505
• WWW.GRANDSTRANDSURGICAL.COM

evaluation of the AMA Guidelines Sixth Edition, the patient has 4% impairment of the whole body. The patient has also has suffered a traumatic brain injury with late effect of this injury associated with the headaches, seizure, posttraumatic stress disorder, and lumbar pain. From the injury that the patient has suffered a traumatic brain injury, the patient suffers a 29% impairment of the whole body according to the AMA Guidelines Sixth Edition. From the seizure standpoint, the patient had like 34% impairment of the whole body. Utilizing a combined value chart, this translates to 54% impairment of the whole body. This does not include the injury that he has suffered from the lumbar standpoint secondary to the injury that he has suffered and has not been addressed here as per Workmen's Comp. At this moment, please do not hesitate to call me if you have any other further questions or indications.

Sincerely,



George Sandoz, MD

GS/kis

Electronically Signed on 06/26/2015 8:22 AM

The End.

Dr. George Sandoz



PATIENT: BENJAMIN, VICTOR
DOB:
MRN:
PHONE: 803-428-3352(Home)
PHYSICIAN: MICHAEL MCCAFFREY, MD
EXAM DATE: 04/13/2015

EXAM: MR-Cervical Spine With and Without Contrast

REASON FOR EXAM: intervertebral disc d/o w/ myelopathy

COMPARISON: 10/15/2012.

TECHNIQUE: 1.5T MRI cervical spine utilizing sagittal and axial T1 and T2 sequences. Following uneventful IV contrast administration additional sagittal and axial T1 sequences were obtained.

CONTRAST: 15 mL Magnevist IV.

FINDINGS: No deformity of the cervicomedullary junction. There is again demonstration of extensive mucosal thickening in the paranasal sinuses.

The C2-C3 level is unremarkable.

At C3-C4, progressive degenerative disc disease although there may have been prior discectomy. There is evidence of posterior decompression and posterior fusion with posterior hardware present. The central canal is overall patent with mild stenosis to the left of midline. Mild hypertrophic endplate spur formation greater in paracentral locations. Abnormal increased T2 signal in the cord dorsolateral on the left is again noted, unchanged, and without abnormal contrast enhancement. Moderate left and mild right neural foraminal stenosis.

The patient is status post anterior cervical discectomy and fusion at the C4-C5-C6 levels with anterior hardware present and solid interbody fusion demonstrated. There is also continuation of this fusion to C6-C7 but without confirmation of osseous fusion across the disc space. The central canal is now patent through these levels as are the respective neural foramina other than moderate to severe bony stenosis of the left C7 neural foramen.

At C7-T1, there is a mild disc bulge with minimal central canal stenosis. Mild left and minimal right neural foraminal stenosis.

IMPRESSION:

1. Status post posterior decompression and posterior fusion at C3-C4. Minimal central canal stenosis asymmetric to the left due to hypertrophic spur formation. Persistent abnormal signal with no abnormal enhancement in the spinal cord on the left dorsolaterally suggests probable myelomalacia. Moderate left and mild right neural foraminal stenosis.
2. Status post ACDF at C4-C5-C6-C7. The central canal is patent through these levels. There is solid interbody fusion at C4-C5 and C5-C6 but not

PATIENT: BENJAMIN, VICTOR
DOB:
EXAM: MR-Cervical Spine With and Without Contrast
EXAM DATE: 04/13/2015

confirmed at C6-C7. There is at least moderate and potentially severe bony stenosis of the left C7 neural foramen.
3. Mild left C8 neural foraminal stenosis.
4. No unusual contrast enhancement.

James Thesing, DO

JAT/llh
DD: 04/13/2015 02:22 P
DT: 04/13/2015 05:34 P
Accession#: 08-2050985 VS#: 120319899 CS#: 1342767
cc:

Electronically Signed and Reviewed by James Thesing, DO 04/13/2015 08:59 P

1106 Chuck Dawley Blvd., Suite 200 ■ Mt. Pleasant, SC 29464

Patient Name: Victor Benjamin  Encounter Date: 10/2/2015  Date of Birth:
Account Number

CC: Follow up neck and right upper extremity pain, low back and right lower extremity pain.

HPI: Mr. Benjamin presents today, accompanied by his wife, for follow up evaluation. He is someone we continue to follow for complaints of chronic neck pain with radiation into the right upper extremity, as well as low back pain with radiation into his right hip. He has previous surgical history of C4-7 done at an outside facility with posterior fusion of C3-4 done by Dr. Richard Frisch and Dr. Steven Poletti in February, 2014. His is a difficult situation as he reports chronic radiculopathy of the right upper extremity after undergoing an EMG with his pain management physician Dr. Sandoz. He states he is considering a possible cervical rhizotomy and remains stable with regards to his cervical spine. He also has chronic low back pain with radiation into his right buttock and posterolateral hip. He previously underwent a right L4-5 LESI 7/10/2015 and states this helped his pain. He states that his pain in his lower extremity seems to be worsening and he feels subjective weakness when ascending stairs. He denies any focal muscle deficits, paralysis, or changes in bowel and bladder function.

Imaging: AP and lateral lumbar plane Films were obtained and reviewed with him today. They show evidence of diffuse lumbar spondylosis with degeneration at the L5-S1 level and facet arthropathy. These are compared with his previous images from 5/15/2014 And appear relatively stable. We have also reviewed cervical plain films which the patient brought with him today. They show appropriate positioning of posterior instrumentation at the C3-4 level. His previous fusion site appear stable.

Physical exam: He is well-developed, well-nourished, 53-year-old male who is alert and oriented ×3 and in no acute distress. He is ambulatory with slightly antalgic gait using the assistance of a cane primarily for fall prevention. Strength of the lower extremity is 5/5 with hip flexion, ankle dorsi flexion and 4/5 with knee flexion, knee extension, plantar flexion bilaterally. Positive straight leg raise on the right, negative on the left. Negative Hoffman's sign. Strength of the upper extremity is intact. Restricted, painful, cervical range of motion.

**Diagnosis Codes:**
M54.12 Radiculopathy, cervical region
M47.27 Other spondylosis with radiculopathy, lumbosacral region

**Treatment Plan:** Greater than 15 minutes of face to face time was spent with Mr. Benjamin and his wife discussing his current pain complaints, updated imaging, and plan of care. Recommendation today is for an updated lumbar MRI scan in order to evaluate his neurologic structures given his persistent and increasing pain. We will also place an order for a right L4-5 years thigh as he has historically done well with this and present with similar symptoms. This is to be completed at his convenience. With regards to cervical spine he does remain stable and he is to continue to follow up with Dr. Sandoz for further pain management. He is to return for follow-up evaluation in 3 months time or on completion of his lumbar MRI scan. He is instructed to contact our office if his symptoms progress or worsen in any way.Lumbar epidural steroid injection was ordered. An MRI of the lumbar spine was ordered. The scan will need to include 3-D reformations to evaluate for any potential extraforaminal herniations as well as anticipation of injection

DIGITALLY SIGNED Anne E. Buck, PA-C
10/2/2015

Patient Name: Benjamin, Victor
Account number:
DOB:
Encounter Date: 10/2/2015

therapy or surgical intervention. The patient is instructed to call us if pain persists or get worse. Patient to return in 3 months for follow up. The patient is to return when the result of MRI is available.

Anne E. Buck, PA-C

DIGITALLY SIGNED Anne E. Buck, PA-C
10/2/2015

Richard C. Holgate, M.D.

The Southeastern Spine Institute
1106 Chuck Dawley Blvd.
Mount Pleasant, SC 29464
843-849-1551

# FINAL REPORT

**Patient:** Victor Benjamin
**Exam Date:** 10/19/2015
**Patient Phone:** _
**Exam Name:** Lumbar
**SSN:**
**Modality:** MRI
**Patient #:**
**Referring Doctor:** Poletti, Steven

**Clinical Information:** M/53 WITH LOW BACK AND RIGHT LEG PAIN FOR FOUR YEARS. NO RECENT TRAUMA. HT-6'0" WT-171 LBS.

**TECHNIQUE:** The patient is examined on the High Field GE Horizon LX High Speed MR System . A phased array coil is used to obtain high resolution images of the lumbar spine. **SERIES:** 1) COR, T1, SE, 7 mm; 2) SAG, Proton, FSE, 3 mm; 3) AX, Oblique, Proton, T2, FSE, 3 mm; 4) AX, T1, SE, 5 mm. 5) AX, Proton, FSE, 4 mm.; **ADDITIONAL SEQUENCES:** 1) MR myelotomography. **3D REFORMATIONS:** 1)COR-OBL,T2FSE/FS, 20mm MIPS. 2) SAG-OBL reformations both right and left.

**OVERVIEW:** Overview of the lumbar spine shows normal bony alignment and normal marrow signal apart from Modic changes with no evidence of a congenital anomaly of the spine. Images of the hips, sacroiliac joints, piriformis muscles and proximal sciatic nerves reveal no abnormality.

**THORACIC SPINE:** Views of the distal thoracic spine show a normal spinal cord and conus medullaris, normal vertebrae and mild noncompressive spondylosis.

**INTERVERTEBRAL DISCS:**
**L1-2, L2-3.** Mild noncompressive spondylosis.

**L3-4.** Mild facet arthropathy, signal loss and a minimal bulge but no sign of root compression.

**L4-5.** Moderate facet arthropathy, signal loss and a diffuse shallow protrusion of disc. There is moderate to severe bilateral lateral recess stenosis (see myelogram).

**L5-S1.** Mild noncompressive spondylosis.

**3D REFORMATIONS AND MYELOTOMOGRAPHY:** MR myelotomography is a 3D sequence which displays the distribution of cerebral spinal fluid within the lumbar subarachnoid space and simulates an x-ray myelogram without spinal injection. Multiple oblique projections were performed and confirm the findings above.

**Opinion:** MRI of the lumbar spine including 3D myelotomographic images and multiplanar reformations shows spondylosis with moderate to severe lateral recess stenosis and potential root compression at L4-5.

**Patient:** Victor Benjamin
**Patient #:** 666600

Exam Name: Lumbar

Exam Date: 10/19/2015

Richard C. Holgate, MD
DISC Radiologists
1341C Old Georgetown Road - Mount Pleasant, SC 29464
(843) 884-8095 - (800) 898-1294 - Fax (843) 856-7312

SOUTH CAROLINA WORKERS' COMPENSATION COMMISSION
COLUMBIA, SOUTH CAROLINA
WCC FILE NO. 1106789

**EMPLOYEE/CLAIMANT:** **VICTOR G. BENJAMIN**

**EMPLOYER:** **REXAM, INC.**

**CARRIER:** **HARTFORD INSURANCE COMPANY OF THE MIDWEST**

---

**SOUTH CAROLINA WORKERS' COMPENSATION HEARING**

---

PURSUANT TO NOTICE OF WORKERS' COMPENSATION HEARING, THE WITHIN HEARING WAS TAKEN ON THE 18TH DAY OF AUGUST, 2016, COMMENCING AT THE HOUR OF 12:00 P.M., IN ST. MATTHEWS, SOUTH CAROLINA, BEFORE THE HONORABLE AISHA TAYLOR, ATTENDED BY COUNSEL AS FOLLOWS:

**TIMMI A. PARRISH**
**VERBATIM REPORTER**

# ORIGINAL

---

*TIMMI A. PARRISH*
COURT REPORTING SERVICES
POST OFFICE BOX 551
ROEBUCK, SC 29376
864-921-8743

## APPEARANCES

**JEFF C. CHANDLER,** ESQUIRE, OF THE
CHANDLER LAW FIRM
2501 OAK STREET
MYRTLE BEACH, SOUTH CAROLINA 29578

ATTORNEY FOR THE CLAIMANT,

**JASON W. LOCKHART,** ESQUIRE, OF THE FIRM
McANGUS, GOUDELOCK & COURIE, LLC
POST OFFICE BOX 12519
COLUMBIA, SOUTH CAROLINA 29211

ATTORNEY FOR THE EMPLOYER/CARRIER.

# I N D E X


PAGE

**VICTOR G. BENJAMIN:**

DIRECT EXAMINATION BY MR. CHANDLER..... 12
CROSS EXAMINATION BY MR. LOCKHART..... 51

**LETIA ANDERSON BENJAMIN:**

DIRECT EXAMINATION BY MR. CHANDLER..... 86
CROSS EXAMINATION BY MR. LOCKHART..... 111

CERTIFICATE OF NOTARY PUBLIC..... 131

1 PURSUANT TO NOTICE OF HEARING, THE WITHIN HEARING
2 WAS TAKEN BY THE ABOVE-NAMED COURT REPORTER, A NOTARY
3 PUBLIC FOR THE STATE OF SOUTH CAROLINA, IN ST. MATTHEWS,
4 SOUTH CAROLINA.
5 * * * * * * * * * * * * * * *
6 **BY COMMISSIONER TAYLOR:**
7 TODAY IS THURSDAY, AUGUST 18TH, 2016. WE ARE
8 HERE IN WORKERS' COMP FILE NUMBER 1106789. THIS IS
9 THE CLAIM OF MR. VICTOR BENJAMIN, WHO IS PRESENT
10 HERE TODAY AND REPRESENTED BY MR. JEFF C. CHANDLER.
11 THE EMPLOYER IS REXAM, INCORPORATED, AND THE CARRIER
12 IS HARTFORD CASUALTY INSURANCE COMPANY. BOTH THE
13 EMPLOYER AND CARRIER ARE REPRESENTED TODAY BY MR.
14 JASON LOCKHART. I HAVE AN ORIGINAL DATE OF INJURY
15 OF JUNE 15TH, 2011. THE CLAIMANT HAS AN AVERAGE
16 WEEKLY WAGE OF $1,461.40, WHICH YIELDS A
17 COMPENSATION RATE OF $704.92.
18 WE ARE HERE TODAY ON THE CLAIMANT'S FORM 50,
19 REQUEST FOR HEARING. I WILL ALLOW THE PARTIES TO
20 PUT DETAILED POSITION STATEMENTS ON THE RECORD.
21 HOWEVER, PRIOR TO DOING SO ARE THERE ANY OBJECTIONS
22 TO DOING SO, ARE THERE ANY OBJECTIONS TO APAs,
23 JURISDICTION, VENUE, OR ANY OTHER ITEMS? MR.
24 CHANDLER?
25 **BY MR. CHANDLER:**

1 NO, YOUR HONOR.

2 **BY THE COMMISSIONER:**

3 OKAY. MR. LOCKHART?

4 **BY MR. LOCKHART:**

5 NONE FROM THE DEFENDANTS, YOUR HONOR.

6 **BY THE COMMISSIONER:**

7 THANK YOU. WITHOUT OBJECTION THE COMMISSION
8 FILE BECOMES A PART OF THE RECORD WITH THE EXCEPTION
9 OF SELF-SERVING DECLARATIONS AND UNSTIPULATED
10 MEDICAL REPORTS.
11 MR. CHANDLER, YOUR POSITION STATEMENT, PLEASE,
12 SIR.

13 **BY MR. CHANDLER:**

14 THANK YOU, YOUR HONOR. MAY IT PLEASE THE
15 COMMISSION. THE CLAIMANT CONTENDS THAT HE IS
16 ENTITLED TO LIFETIME MEDICAL AND MONETARY BENEFITS
17 PURSUANT TO 42-9-C (SIC) CONSISTENT WITH THE CASE OF
18 REED-RICHARDS VERSUS CLEMSON UNIVERSITY. THIS IS
19 SUPPORTED, YOUR HONOR, BY THE CONTENTIONS OF --
20 EXCUSE ME, THE MEDICAL OPINIONS OF DR. STEVEN
21 POLETTI, DR. GEORGE SANDOZ, DR. WILLIAM MILLS, AND
22 DR. ROBERT BRABHAM. THERE IS AN ISSUE AS FAR AS
23 COMPENSABILITY OF THE SPINE. WE HAVE BEEN PROVIDED
24 CAUSATION BY THE AUTHORIZED TREATING DOCTOR, DR.
25 GEORGE SANDOZ. PRESENTLY THERE IS AN ISSUE WITH A

1 PRESCRIPTION OR AN ORDER FOR MEDICAL CARE TO INCLUDE
2 A MOBILITY SCOOTER. CAUSATION HAS BEEN PROVIDED BY
3 DR. GEORGE SANDOZ. HE'S INDICATED THAT THE NEED FOR
4 THE MOBILITY SCOOTER IS BECAUSE OF THE CERVICAL CORD
5 INJURY. WE ARE ALSO SEEKING, YOUR HONOR, A
6 DETERMINATION THAT, UNDER 42-9-10(C), MR. BENJAMIN
7 HAS SUFFERED PERMANENT PHYSICAL BRAIN DAMAGE.
8 AGAIN, THIS IS SUPPORTED BY THE OPINION OF DR.
9 GEORGE SANDOZ, DR. BERGMANN, AND DR. DEAL, AS WELL
10 AS DR. ROBERT BRABHAM. IT'S THE POSITION OF THE
11 CLAIMANT THAT HE SHOULD BE ABLE TO GET HIS BENEFIT,
12 IF YOU WILL, YOUR HONOR, IN AT LEAST A PARTIAL LUMP
13 SUM, AND HE IS GOING TO OFFER TESTIMONY ABOUT THE
14 PROBLEMS THAT HE HAS WITH HIS HOUSEHOLD AND WITH HIS
15 OVERALL NEED OF MONEY. MR. BENJAMIN OWNED A
16 BUSINESS APART FROM HIS FULL-TIME EMPLOYMENT WITH
17 REXAM BEVERAGE THAT HE HAS NOT BEEN ABLE TO DO SINCE
18 2011. HE'S LOST GAINFUL EMPLOYMENT AND INCOME IN
19 THAT POSITION. HE TESTIFIED ABOUT THAT SECONDARY
20 SOURCE OF INCOME DURING HIS DEPOSITION, SO IT'S
21 KNOWN TO THE OTHER SIDE -- TO THE OTHER SIDE. WE
22 ASK THAT ANY BENEFIT BE PROVIDED UTICA ALLOCATION
23 LANGUAGE CONSISTENT WITH THOMPSON, SOUTH CAROLINA
24 STEEL ERECTORS, AND UTICA-MOHAWK ALLOCATION --
25 EXCUSE ME, UTICA-MOHAWK CASE. AND I THINK YOUR

1 HONOR HAS MEDICAL IMPAIRMENT RATINGS THAT WE'VE
2 ALREADY SET FORTH AND ARE LISTED ON THE PREHEARING
3 BRIEF AND ITS ATTACHMENT.
4 **BY THE COMMISSIONER:**
5 THANK YOU VERY MUCH. MR. LOCKHART.
6 **BY MR. LOCKHART:**
7 YOUR HONOR, MAY IT PLEASE THE COURT. WE ARE
8 HERE TODAY -- I AM HERE TODAY, RATHER, ON BEHALF OF
9 REXAM AND THEIR WORKERS' COMPENSATION INSURANCE
10 CARRIER. BASED ON A REVIEW OF THE FORM 50 FILED
11 THAT LED TO THE SCHEDULING OF THIS HEARING, IT'S MY
12 UNDERSTANDING THAT THERE ARE A LITANY OF ALLEGED
13 INJURIES THAT HAVE BEEN AT LEAST LAID OUT ON THAT
14 REQUEST FOR HEARING. WE ADMIT THAT MR. BENJAMIN
15 SUFFERED A COMPENSABLE INJURY TO THE NECK, PSYCHE,
16 AND RIGHT UPPER EXTREMITY BUT DENY THAT HE SUSTAINED
17 PHYSICAL BRAIN DAMAGE, INJURIES TO THE LOWER BACK,
18 LEFT SHOULDER, RIGHT SHOULDER, LEFT LOWER EXTREMITY
19 AND/OR RIGHT LOWER EXTREMITY.
20 WITH REGARDS TO THE ISSUE OF THE REQUEST FOR
21 LIFETIME COMPENSATION BASED ON A DIAGNOSIS OF
22 INCOMPLETE EITHER PARAPLEGIA OR QUADRIPLEGIA, WE
23 RELY UPON THE EXPERT OPINION OF DR. CARL LOZANNE AS
24 WELL AS A LITANY OF OTHER MEDICAL RECORDS THAT WE
25 DISCUSSED IN OUR PREHEARING CONFERENCE IN SUPPORT OF

1 OUR CONTENTION THAT MR. BENJAMIN CANNOT SATISFY HIS
2 BURDEN OF PROOF PROVING ENTITLEMENT TO LIFETIME
3 COMPENSATION BASED ON A DIAGNOSIS OF PARAPLEGIA OR
4 QUADRIPLEGIA, AND WE SENT TO YOUR OFFICE EARLIER
5 THIS WEEK A DOCUMENT THAT ESSENTIALLY SUMMARIZES OUR
6 POSITION AND MEDICAL RECORDS THAT SUPPORT IT ON BOTH
7 THAT ISSUE AND THE ISSUE OF HOW WE BELIEVE THAT
8 REED-RICHARDS CASE SUPPORTS OUR CONTENTION THAT HE
9 CANNOT SATISFY HIS BURDEN OF PROOF UNDER SECTION 42-
10 9-10, THE DISTINGUISHABLE DIFFERENCES BETWEEN THOSE
11 TWO CASES. AND ALSO IN THE PREHEARING CONFERENCE WE
12 ALSO DISCUSSED WITH YOU THE RECENT DECISION OF
13 McMAHAN VERSUS THE SOUTH CAROLINA DEPARTMENT OF
14 EDUCATION, WHICH WE ALSO BELIEVE SUPPORTS OUR
15 POSITION ON THE ISSUE OF PARAPLEGIA AND
16 QUADRIPLEGIA.
17 WITH REGARDS TO THE ISSUE OF BRAIN DAMAGE, WE
18 MAINTAIN THAT THE MEDICAL EVIDENCE AS A WHOLE DOES
19 NOT SUPPORT MR. BENJAMIN'S CONTENTION THAT HE HAS
20 SUFFERED BRAIN DAMAGE TO SUCH A DEGREE THAT HE'S
21 ENTITLED TO LIFETIME BENEFITS. WE DISCUSSED DURING
22 OUR PREHEARING CONFERENCE THE SPARKS CASE, WHICH YOU
23 ARE VERY FAMILIAR WITH, IN WHICH THE SUPREME COURT
24 HELD THAT BRAIN -- PHYSICAL BRAIN DAMAGE AS USED IN
25 SECTION 42-9-10 IS PHYSICAL BRAIN DAMAGE THAT IS

1 PERMANENT AND SEVERE. BASED ON A REVIEW OF THE
2 MEDICAL RECORDS, THERE IS NOT ANY PHYSICIAN WHO HAS
3 OPINED THAT MR. BENJAMIN'S BRAIN DAMAGE IS PERMANENT
4 OR SEVERE. I BELIEVE THE CLAIMANT IS RELYING UPON A
5 CORRESPONDENCE FROM DR. SANDOZ TO THE CLAIMANT'S
6 ATTORNEY DATED DECEMBER 14, 2015, IN WHICH DR.
7 SANDOZ OPINES THAT MR. BENJAMIN HAS SUFFERED
8 PHYSICAL BRAIN DAMAGE. WE WOULD DIRECT YOUR HONOR
9 TO DIAGNOSTIC SCANS OF MR. BENJAMIN'S BRAIN AND
10 HEAD, WHICH WE BELIEVE DO NOT SUPPORT SUCH A
11 CONCLUSION, AS WELL AS SOME ADDITIONAL EVIDENCE THAT
12 WE WILL BRING OUT IN THE COURSE OF THE TESTIMONY
13 HERE TODAY.
14 WITH REGARDS TO THE LOWER BACK, THAT HAS BEEN
15 DENIED ON THE BASIS OF THE MEDICAL RECORDS, WHICH WE
16 WILL GET INTO LATER, INCLUDING SOME OF THE EARLY
17 MEDICAL RECORDS IN THIS PARTICULAR CASE. IF YOU
18 WERE TO FIND THAT HE HAS SUSTAINED A COMPENSABLE
19 INJURY TO THE LOWER BACK, WE WOULD ARGUE THAT THE
20 MEDICAL RECORDS SUBMITTED BY THE CLAIMANT, INCLUDING
21 A RECENT DIAGNOSTIC REPORT OF DR. SARB, DATED, I
22 BELIEVE, JUNE 16TH, 2016, INDICATES THAT DR. SARB
23 MOST RECENTLY ADMINISTERED A LUMBAR EPIDURAL STEROID
24 INJECTION TO THE CLAIMANT AND IS RECOMMENDING A
25 RETURN TO HER FOLLOWING THAT INJECTION. THEREFORE,

1 THE MEDICAL EVIDENCE -- THE CONTEMPORANEOUS MEDICAL
2 EVIDENCE SUPPORTS A FINDING THAT HE IS NOT AT
3 MAXIMUM MEDICAL IMPROVEMENT.
4 WITH REGARDS TO THE LUMP SUM PAYMENT, AS I SAID
5 TO YOU IN OUR PREHEARING CONFERENCE, I SEE NO
6 EVIDENCE SUBMITTED WITH THE BRIEF FROM THE CLAIMANT
7 TO SUPPORT A PARTIAL LUMP SUM PAYMENT, AND I RESERVE
8 THE RIGHT TO, OF COURSE, CROSS EXAMINE THE CLAIMANT
9 ON THAT ISSUE. BUT, AGAIN, I THINK I'M A BIT AT A
10 DISADVANTAGE ON THAT IN THAT I DON'T HAVE ANY WAY OF
11 KNOWING EXACTLY WHAT'S BEING REQUESTED ON THAT FROM
12 THAT PERSPECTIVE. THANK YOU, YOUR HONOR.
13 **BY THE COMMISSIONER:**
14 OKAY, THANK YOU. MR. LOCKHART, DID YOU ADDRESS
15 THE SCOOTER? DID YOU ADDRESS THE ISSUE WITH THE
16 SCOOTER?
17 **BY MR. LOCKHART:**
18 WELL, THE ISSUE WITH THE SCOOTER, YOUR HONOR, I
19 THINK WE WOULD ARGUE THAT IF YOU LOOK AT THE MEDICAL
20 EVIDENCE, MUCH OF IT, AFTER THE RECOMMENDATION FROM
21 DR. SANDOZ, INCLUDING DR. LOZANNE'S MOST RECENT
22 DIAGNOSTIC REPORT, THE STRENGTH TEST AND THE
23 PHYSICAL EXAMINATION OF THE LOWER EXTREMITIES
24 WOULDN'T SEEM TO SUPPORT SUCH A MODALITY, AND I
25 DON'T SEE THAT DR. LOZANNE HAS EVER RECOMMENDED IT.

1 AND HE IS ALSO AN AUTHORIZED TREATING PHYSICIAN, THE
2 DOCTOR WHO HAS MOST RECENTLY EXAMINED MR. BENJAMIN.
3 **BY THE COMMISSIONER:**
4 THANK YOU. MADAM COURT REPORTER, WILL YOU
5 PLEASE SWEAR MR. BENJAMIN.
6 **BY THE COURT REPORTER:**
7 SIR, IF YOU WOULD RAISE YOUR RIGHT HAND,
8 PLEASE.
9 * * * * * * * * * * * * * * *
10 THE WITNESS WAS DULY SWORN TO TELL THE TRUTH, THE
11 WHOLE TRUTH, AND NOTHING BUT THE TRUTH CONCERNING THE
12 MATTER HEREIN:
13 **VICTOR G. BENJAMIN,**
14 BEING FIRST DULY SWORN, TESTIFIED ON HIS OATH AS
15 FOLLOWS:
16 **BY THE COMMISSIONER:**
17 MR. CHANDLER.
18 **BY MR. CHANDLER:**
19 THANK YOU, YOUR HONOR. VICTOR, I'M GOING TO --
20 IF YOU DON'T MIND ---
21 **BY THE COMMISSIONER:**
22 NO; SURE.
23 **BY MR. CHANDLER:**
24 HE MAY HAVE A HARD TIME TURNING TOWARDS ME, SO
25 I'M GOING TO ---

1 **BY THE COMMISSIONER:**

2 I UNDERSTAND.

3 **BY MR. CHANDLER:**

4 --- STAND OVER HERE.

5 **BY THE COMMISSIONER:**

6 SURE.

7 **DIRECT EXAMINATION BY MR. CHANDLER:**

8 Q. VICTOR, THIS WILL BE EASIER FOR YOU. TELL THE COURT

9 TODAY, VICTOR, HOW OLD ARE YOU?

10 A. I'M 54 YEARS OLD.

11 Q. ARE YOU MARRIED?

12 A. YES, I AM.

13 Q. AND WHAT IS YOUR WIFE'S NAME?

14 A. LETIA BENJAMIN.

15 Q. AND IF YOU CAN SPEAK UP A LITTLE BIT LOUDER.

16 A. OKAY. LETIA BENJAMIN.

17 Q. OKAY. AND HOW LONG HAVE YOU BEEN MARRIED?

18 A. THREE, FOUR YEARS.

19 Q. DO YOU HAVE CHILDREN?

20 A. YES, I DO.

21 Q. HOW MANY CHILDREN DO YOU HAVE?

22 A. I HAVE TWO KIDS.

23 Q. WHAT AGES ARE THEY?

24 A. ONE IS 24, AND THE OTHER ONE IS 16.

25 Q. DO EITHER OF THOSE CHILDREN LIVE WITH YOU STILL?

1 A. NO.
2 Q. VICTOR, HOW FAR DID YOU GO IN SCHOOL?
3 A. TO 12TH GRADE.
4 Q. DID YOU FINISH THE 12TH GRADE?
5 A. YES, I DID.
6 Q. YOU ARE A GRADUATE?
7 A. YES, I AM.
8 Q. WHAT HIGH SCHOOL?
9 A. BISHOPVILLE HIGH SCHOOL.
10 Q. AND IS THAT WHERE YOU'VE GROWN UP ALL OF YOUR LIFE?
11 A. YES, I HAVE.
12 Q. DID YOU GO ON AND GET ANY ADDITIONAL EDUCATION OR
13 TRAINING AFTER BISHOPVILLE HIGH SCHOOL?
14 A. I WENT TO KERSHAW COUNTY WELDING SCHOOL IN KERSHAW.
15 Q. DID YOU GET A CERTIFICATE?
16 A. YES.
17 Q. WAS THAT IN WELDING?
18 A. YES, IT WAS.
19 Q. TELL THE COURT ABOUT THE TYPES OF WORK YOU'VE DONE
20 THROUGH THE YEARS.
21 A. THE TYPE OF WORKS I'VE DONE THROUGH THE YEARS ARE I
22 WORKED FOR REEVES BROTHERS MANUFACTURING, YARN
23 MANUFACTURING.
24 Q. WHAT WAS THE NATURE OF YOUR JOB AT THAT
25 MANUFACTURING COMPANY? WHAT DID YOU DO FOR THEM?

1 A. I'M TRYING TO THINK. IT WAS SO MANY YEARS AGO.
2 SOMETHING LIKE DYEING CLOTH, DEALING WITH CLOTH AND
3 YARN. THEN I WENT TO WORK FOR BURLINGTON AFTER I
4 HAD GOT LAID OFF FROM REEVES BROTHERS, AND I WORKED
5 FOR THEM FOR A FEW MONTHS. THEN REXAM CALL ME TO
6 WORK.
7 Q. REXAM IS THE COMPANY THAT YOU WORKED WITH WHEN YOU
8 GOT INJURED IN 2011?
9 A. YES, IT IS.
10 Q. DID YOU HOLD DIFFERENT POSITIONS THROUGH THE YEARS
11 WITH REXAM?
12 A. YES, I DID.
13 Q. AND WHAT IS REXAM? WHAT DO YOU UNDERSTAND THAT THE
14 NATURE OF THEIR BUSINESS IS?
15 A. REXAM, THEY MAKE SODA CANS AND BEER CANS.
16 Q. AND HOW MANY YEARS DID YOU WORK WITH REXAM BEFORE
17 YOUR INJURY?
18 A. LIKE 29 YEARS AND -- 29 AND A HALF YEARS OR
19 SOMETHING LIKE THAT.
20 Q. ARE YOU STILL AN EMPLOYEE TO THIS DAY?
21 A. YES, I AM.
22 Q. NEVER FIRED YOU?
23 A. NEVER FIRED ME.
24 Q. VICTOR, I KNOW THAT YOUR TESTIMONY AT YOUR
25 DEPOSITIONS AND MAYBE YOUR PRIOR HEARING IS A LITTLE

1 FUZZY WITH RESPECT TO WHAT HAPPENED TO YOU ON THE
2 DATE OF YOUR INJURY, AND I THINK YOUR RECALL PICKS
3 UP MAYBE IN THE HOSPITAL. BUT WHAT WAS YOUR JOB
4 BACK IN JUNE OF 2011 WHEN YOU GOT HURT?
5 A. I WAS -- I WAS A HEAD OPERATOR OF THE MAKING OF THE
6 CAN, WHAT THEY CALL A CUPPER OPERATOR. I MADE THE
7 FIRST PROCESS OF THAT CAN.
8 Q. VICTOR, COMMISSIONER TAYLOR HAS, I DON'T KNOW,
9 UPWARDS OF A THOUSAND PAGES OR SO OF RECORDS, AND
10 SHE'S GOING TO SPEND A LOT OF TIME GOING THROUGH ALL
11 OF THE DIFFERENT TYPES OF TREATMENT THAT YOU'VE HAD.
12 SO I'M NOT GOING TO HAVE TO WALK YOU THROUGH EVERY
13 OFFICE VISIT THAT YOU HAD WITH THE DIFFERENT
14 DOCTORS. I KNOW YOU'VE SEEN A LOT.
15 A. YES, I HAVE.
16 Q. BUT I DO WANT TO TALK TO YOU ABOUT YOUR INJURIES AS
17 YOU SIT HERE TODAY. OKAY? YOU'RE WEARING A NECK
18 BRACE?
19 A. YES.
20 Q. IS THAT RIGHT?
21 A. YES.
22 Q. AND THE RECORDS REFLECT THAT YOU'VE HAD A COUPLE OF
23 SURGERIES INVOLVING YOUR NECK?
24 A. YES.
25 Q. AND YOU'VE SEEN DR. POLETTI FOR YOUR NECK, IS THAT

1 RIGHT?
2 A. YES, I HAVE.
3 Q. YOU'VE SEEN DR. SANDOZ?
4 A. YES, I HAVE.
5 Q. YOU'VE SEEN DR. LOZANNE?
6 A. YES, I HAVE.
7 Q. YOU'VE SEEN DR. SARB?
8 A. YES, I HAVE.
9 Q. AND YOU ALSO SEE DR. BERGMANN AND FORMERLY SAW DR.
10 DEAL BEFORE HE PASSED AWAY?
11 A. YES, I DID.
12 Q. AND I THINK IN THE DISTANT PAST YOU SAW A LEONARD
13 GOLDSCHMIDT?
14 A. YES, I HAVE.
15 Q. AND WHO IS YOUR TREATING DOCTOR RIGHT NOW? WHO DO
16 YOU SEE MOST FOR YOUR NECK PROBLEM?
17 A. I SEE DR. SANDOZ AND DR. POLETTI.
18 Q. OKAY. AND WITH RESPECT TO DR. SANDOZ, WHAT THINGS
19 DOES HE DO FOR YOU NOW?
20 A. DR. SANDOZ, WHEN I GO TO DR. SANDOZ, HE CHECKS MY
21 NECK, AND I TELL HIM THE THINGS I'M GOING THROUGH
22 WITH MY NECK WITH THE PAINS AND STUFF, AND HE TELLS
23 ME ---
24 **BY MR. LOCKHART:**
25 YOUR HONOR, I'D HAVE TO OBJECT TO ---

1 **DIRECT EXAMINATION RESUMED BY MR. CHANDLER:**
2 Q. YOU CAN'T TELL US WHAT THE DOCTOR SAID TO YOU, JUST
3 WHAT HE DOES FOR YOU.
4 A. OKAY. WHAT HE DOES FOR ME, HE PRESCRIBES
5 MEDICATIONS FOR ME, AND HE CHECKS MY NECK. HE DOES
6 X-RAYS ON MY NECK AND DOES MRIs.
7 Q. VICTOR, I DON'T KNOW IF YOU KNOW THE MEDICINES THAT
8 YOU'RE TAKING. ARE YOU FAMILIAR WITH THE DIFFERENT
9 DRUGS THAT YOU'RE PRESCRIBED AND THAT YOU TAKE?
10 A. YES. I CAN -- I HAVE THEM IN MY WALLET.
11 Q. ARE THEY WRITTEN DOWN ON A PIECE OF PAPER?
12 A. YES, THEY ARE.
13 **BY MR. CHANDLER:**
14 YOUR HONOR, MAY I PUBLISH THOSE?
15 **BY THE COMMISSIONER:**
16 MR. LOCKHART?
17 **BY MR. LOCKHART:**
18 CAN I AT LEAST SEE THEM BEFORE YOU PUBLISH
19 THEM?
20 **BY MR. CHANDLER:**
21 SURE.
22 **BY MR. LOCKHART:**
23 THANK YOU.
24 **DIRECT EXAMINATION RESUMED BY MR. CHANDLER:**
25 Q. AND ARE THESE MEDICINES ALL PRESCRIBED BY DR.

1 SANDOZ, OR IS THERE ANOTHER DOCTOR THAT'S
2 PRESCRIBING SOME OF THESE THAT YOU'RE GOING TO SHOW
3 US?
4 A. DR. SANDOZ PRESCRIBES ALL OF THESE. EVERYTHING
5 THAT'S SCRATCHED OUT IS WHAT I DON'T TAKE. ALSO,
6 THE PRAVASTATIN AND THE -- PRAVASTATIN AND THE -- MY
7 BLOOD PRESSURE MEDICINE, DR. SANDOZ -- I MEAN, THE
8 NORVASC, MY FAMILY DOCTOR PRESCRIBED THAT. I THINK
9 THERE'S MAYBE ONE OR TWO THAT'S NOT ON THERE. I
10 HAVE IT IN MY PHONE, ALL MY MEDICINE I DO TAKE.
11 IT'S UPDATED.
12 Q. IT LOOKS LIKE MAYBE THERE'S A DRUG CALLED VIMPAT. I
13 THINK THAT'S A DRUG, IF I'M NOT MISTAKEN, TO CONTROL
14 YOUR SEIZURES?
15 A. YES, IT IS.
16 **BY MR. LOCKHART:**
17 AND, YOUR HONOR, I'M JUST GOING TO HAVE TO
18 OBJECT TO ANY -- THAT'S NOT LEADING, BUT I THINK THE
19 MEDICAL RECORDS TELL US WHAT THOSE MEDICATIONS ARE
20 FOR.
21 **BY THE COMMISSIONER:**
22 YES. YOU CAN JUST PUBLISH THE LIST.
23 **DIRECT EXAMINATION RESUMED BY MR. CHANDLER:**
24 Q. LOOKS LIKE YOU'VE GOT VIMPAT; YOU'VE GOT A
25 CLONAZEPAM, IT NOTES, AT BEDTIME; YOU'VE GOT

1 DIAZEPAM OR VALIUM; YOU'VE GOT OXYCODONE?
2 A. YES.
3 Q. DO YOU THINK THOSE ARE THE DRUGS THAT ARE PRESCRIBED
4 BY DR. SANDOZ?
5 A. YES, SIR. THERE'S ONE OTHER ONE. HE GAVE ME A RUB
6 THAT HE PRESCRIBED TO ME FOR PAIN. AND I CAN'T
7 REMEMBER WHAT -- IT START WITH A "D," AND I CAN'T
8 PRONOUNCE THE WORD. AND MATTER OF FACT, I HAD TO
9 CALL HIM THIS MORNING TO GET A REFILL ON IT, BECAUSE
10 HE NORMALLY -- WHENEVER HE FILLS MY MEDICINE -- I
11 SEE HIM LIKE EVERY THREE MONTHS -- HE GIVES ME A
12 SCRIPT TO HAVE MY MEDICINE FILLED FOR THE THREE
13 MONTHS UNTIL I GET BACK TO SEE HIM.
14 Q. YOU TAKE THESE DIFFERENT MEDICINES THAT DOCTOR
15 SANDOZ PRESCRIBES YOU. LET'S TALK ABOUT WHY HE
16 PRESCRIBES THESE MEDICINES FOR YOU, OKAY?
17 A. YES.
18 Q. WHAT, IF ANY, SYMPTOMS DO YOU HAVE, VICTOR, WITH
19 RESPECT TO HEAD PAINS OR HEADACHES?
20 A. I HAVE DIZZINESS. I HAVE MIGRAINE HEADACHES. I GET
21 DISORIENTATED SOMETIMES. I HAVE MEMORY -- TRYING TO
22 REMEMBER THINGS SOMETIMES. AND THAT'S PRETTY MUCH
23 ABOUT IT.
24 Q. LET'S TAKE THOSE INDIVIDUALLY. WITH RESPECT TO
25 MIGRAINE HEADACHES, WHAT'S THE FREQUENCY OF THOSE

1 HEADACHES? HOW OFTEN DO THEY OCCUR?
2 A. IT'S KIND OF HARD TO SAY. A FEW TIMES A DAY THAT
3 THEY OCCUR. AND I TAKE THE VALIUM AND THE OXYCODONE
4 FOR THAT AND ALSO THE OXYCODONE FOR MY PAIN THAT I'M
5 HAVING FROM MY NECK AND OTHER PARTS OF MY BODY.
6 Q. VICTOR, THEY OCCUR SEVERAL TIMES A DAY. DOES THAT
7 OCCUR EVERY DAY OF A GIVEN WEEK?
8 A. YES, IT DOES.
9 Q. ARE THERE ANY THINGS BESIDES MEDICINES THAT YOU DO
10 TO TRY TO ELIMINATE THE SYMPTOMS FROM A MIGRAINE
11 HEADACHE?
12 A. YES.
13 Q. WHAT DO YOU TRY TO DO?
14 A. GET INTO BED AND TAKE A NAP SO I CAN JUST SLEEP IT
15 AWAY.
16 Q. HOW MANY HOURS OF A GIVEN DAY ARE YOU IN A BED?
17 A. WELL, AFTER GETTING UP I'M PROBABLY IN THE BED
18 SOMEWHERE CLOSE TO PROBABLY FOUR TO FIVE HOURS A
19 DAY.
20 Q. THAT'S ONCE YOU'VE ALREADY RISEN FOR THE DAY?
21 A. YES.
22 Q. SO YOU GO BACK TO THE BED?
23 A. YES, I DO.
24 Q. YOU TALKED ABOUT DISORIENTATION. DESCRIBE THAT WITH
25 A LITTLE BIT OF DETAIL FOR US. WHAT DO YOU -- WHAT

1 DO YOU FEEL?
2 A. I CAN'T FUNCTION, WHAT'S GOING ON. DISORIENTATION
3 TO ME MEANS I CAN SEE WHAT'S HAPPENING, BUT I CANNOT
4 CONTROL IT. SO WHAT I TRY TO DO IS TRY TO SIT DOWN
5 IN A QUIET PLACE, WHICHEVER PLACE WHEREVER I'M AT IS
6 QUIET, AND JUST TRY TO RELAX. AND I JUST CAN'T
7 FUNCTION WHEN I'M DISORIENTATED.
8 Q. DO YOU FIND THAT THAT TYPE OF SYMPTOM OCCURS
9 FREQUENTLY WITH YOU?
10 A. YES, IT DOES.
11 Q. IS THERE ANYTHING THAT YOU CAN PINPOINT THAT BRINGS
12 THAT ON?
13 A. NO, I CAN'T. I TALKED TO DR. -- A DOCTOR ABOUT IT,
14 DR. SANDOZ. HE SAYS IT COMES FROM THE SPINAL CORD.
15 IT'S NOT ---
16 **BY MR. LOCKHART:**
17 YOUR HONOR, AGAIN, I'D HAVE TO OBJECT TO
18 ANYTHING DR. SANDOZ SAID TO THE CLAIMANT.
19 **BY THE COMMISSIONER:**
20 SUSTAINED.
21 **DIRECT EXAMINATION RESUMED BY MR. CHANDLER:**
22 Q. VICTOR, YOU TALKED ABOUT SOME DIZZINESS?
23 A. YES.
24 Q. HAVE THOSE SYMPTOMS OF DIZZINESS BEEN PRESENT WITH
25 YOU SINCE THE VERY BEGINNING OF YOUR INJURY?

1 A. YES, THEY HAVE.
2 Q. AND IS THAT DIZZINESS SOMETHING THAT HAPPENS TO YOU
3 ALL THE TIME?
4 A. YES.
5 Q. AND HOW DOES THAT AFFECT YOU?
6 A. I'M DIZZY. IF I'M DRIVING I WILL PULL OVER. I
7 DON'T DRIVE LONG DISTANCES. EVEN GOING BACK AND
8 FORTH TO THE DOCTOR TO COLUMBIA I WILL STOP, TAKE A
9 BREAK, LEAVE A LITTLE EARLY, TAKE A BREAK, AND GET
10 BACK UP TO MAKE SURE THAT I'M OKAY. IF I'M OKAY,
11 I'LL TRAVEL ON TO THE DOCTOR.
12 Q. AND THE MEDICAL RECORDS REFER TO -- THAT YOU'VE HAD
13 A SEIZURE IN THE PAST. HAVE YOU HAD A SEIZURE IN
14 THE PAST COUPLE YEARS, THAT YOU'RE AWARE OF?
15 A. I'M NOT AWARE OF IT. BECAUSE OF THE MEDICATION THAT
16 I'M ON I'M NOT AWARE OF IT. I COULD HAVE, BECAUSE
17 SOMETIMES AT NIGHT I'M IN BED WITH MY WIFE, SHE WILL
18 WAKE ME UP, TALKING IN MY SLEEP OR FIGHTING IN MY
19 SLEEP. I'M JUMPING, SHAKING. I DOES THAT A LOT.
20 AND I DON'T KNOW IF I'M HAVING SEIZURES OR NOT. I
21 REALLY DON'T KNOW. EVEN WHEN I STARTED HAVING
22 SEIZURES, I DIDN'T REALIZE I WAS HAVING SEIZURES
23 UNTIL THEY DID A CAT SCAN ON ME, OR WHATEVER THEY
24 DID, PUT THE THING ON MY HEAD. I DIDN'T KNOW I WAS
25 HAVING SEIZURES UNTIL IT WAS BROUGHT TO MY ATTENTION

1 I WAS HAVING SEIZURES.
2 Q. ARE YOU UNDER THE IMPRESSION THAT YOU'RE TAKING
3 MEDICINE TO PREVENT SEIZURES?
4 A. YES, I AM. YES.
5 Q. THESE MEDICINES THAT YOU TAKE, DO YOU TAKE THOSE
6 EVERY DAY AND TAKE THEM AS PRESCRIBED BY THE
7 DOCTORS?
8 A. YES, I DO.
9 Q. HAVE YOU EVER BEEN WITHOUT THE BENEFIT OF THE
10 MEDICINE PERHAPS BECAUSE THE INSURANCE COMPANY
11 DIDN'T AUTHORIZE THEM WHEN YOU TOOK THEM TO THE
12 PHARMACY?
13 A. YES, I HAVE.
14 Q. HAS THAT HAD ANY KIND OF NEGATIVE IMPACT ON YOU WHEN
15 YOU DIDN'T HAVE THE DRUGS?
16 A. I REALLY DON'T KNOW. I FEEL LIKE IT DID BECAUSE IT
17 STRESSES ME OUT, BECAUSE I KNOW THAT I GOT TO HAVE
18 THAT MEDICINE TO PREVENT ME FROM HAVING SEIZURES,
19 AND I GET VERY STRESSFUL ABOUT IT, AND I CONSTANTLY
20 CALL THE DRUGSTORE, AND THEY SAY, "WE'RE WAITING TO
21 HEAR BACK FROM THE CARRIER BEFORE WE CAN GET THE
22 MEDICINE TAKEN CARE OF." AND IT'S THE SAME MEDICINE
23 I TAKE EVERY MONTH, TAKE MONTH IN AND MONTH OUT, AND
24 NOTHING CHANGES WITH THE MEDICINE. THE PROBLEM I
25 HAVE, I GET STRESSED BECAUSE, IN FACT, I'M TAKING

1 THE SAME MEDICINE. THE DOCTOR DOESN'T CHANGE THE
2 MEDICINE, AND I CAN'T UNDERSTAND WHY IT'S NOT
3 APPROVED FOR ME TO TAKE THE SAME MEDICINE EVERY
4 MONTH THAT I'M ALREADY TAKING WHEN THERE'S NOTHING
5 THAT EVER CHANGES.
6 Q. YOU MENTIONED STRESS. YOU SEE SOME DOCTORS IN THE
7 COLUMBIA AREA. YOU DID SEE TWO DOCTORS. ONE WAS
8 DR. DEAL, AND ONE WAS DR. BERGMANN?
9 A. YES.
10 Q. YOU'RE SEEING DR. BERGMANN PRESENTLY?
11 A. YES, I AM.
12 Q. IS THAT RIGHT?
13 A. YES, I AM.
14 Q. OKAY. AND WHAT DOES DR. BERGMANN DO FOR YOU? DOES
15 HE MEET WITH YOU?
16 A. YES, HE DOES. HE MEETS WITH ME. DR. BERGMAN HAS
17 REALLY BEEN HELPFUL TO ME. AND I SPOKE TO DR.
18 BERGMAN, AND ONE OF THE CARRIERS CAME WITH ME ONE
19 DAY AND ASKED DR. BERGMANN HOW MUCH LONGER WOULD I
20 BE ABLE TO SEE HIM, HOW MUCH LONGER DO I NEED TO SEE
21 HIM, AND HE TOLD -- SHE -- HE TOLD HER THAT I WOULD
22 HAVE TO SEE HIM THE REST OF MY LIFE BECAUSE OF THE
23 FACT THE THINGS THAT I'M GOING THROUGH ---
24 **BY MR. LOCKHART:**
25 YOUR HONOR, AGAIN, I'M SORRY.

1 **BY THE COMMISSIONER:**

2 SUSTAINED.

3 **BY MR. LOCKHART:**

4 I'D HAVE TO OBJECT TO ANYTHING DR. BERGMANN

5 SAID TO THE CLAIMANT.

6 **BY THE COMMISSIONER:**

7 SUSTAINED.

8 **DIRECT EXAMINATION RESUMED BY MR. CHANDLER:**

9 Q. THE TREATMENT THAT HE GIVES YOU, THE MEETINGS THAT

10 YOU HAVE WITH DR. BERGMANN, DO YOU EXPLAIN AND

11 DESCRIBE TO HIM ALL THE SITUATIONS AND SYMPTOMS THAT

12 ARE GOING ON IN YOUR LIFE?

13 A. YES, I DO.

14 Q. OKAY. AND SO, FOR THE RECORD TODAY, DO YOU HAVE

15 PROBLEMS -- WHAT, IF ANY, PROBLEMS DO YOU HAVE WITH

16 ANGER?

17 A. I HAVE A LOT OF PROBLEMS WITH ANGER. I TRY -- I TRY

18 TO CONTROL MY ANGER. I TRY NOT TO BE AROUND PEOPLE.

19 I ONLY DEAL WITH PEOPLE THAT I KNOW THAT I GOT TO GO

20 DEAL WITH AND COME BACK, BECAUSE THERE IS SOMETHING

21 INSIDE OF ME, IF SOMEBODY STRIKES ME THE WRONG WAY,

22 IT'S GOING TO COME OUT, AND I WILL GET MYSELF IN

23 TROUBLE. I TRY NOT TO GET MYSELF IN TROUBLE. SO

24 RATHER THAN DOING THAT, I'D RATHER JUST BE AT THE

25 HOUSE, BEING ALONE AND NOT BOTHERING NO ONE OR HAVE

1 TO (UNINTELLIGIBLE WORD) ANYONE ELSE.
2 Q. PRIOR TO JUNE OF 2011 DID YOU HAVE PROBLEMS WITH
3 ANGER OR HOSTILITY?
4 A. NO, I DID NOT.
5 Q. HAS DR. BERGMANN TRIED TO PROVIDE YOU ANY KIND OF
6 COPING MECHANISMS OR ANY KIND OF PLAN THAT YOU COULD
7 UTILIZE WHEN YOU FELT SYMPTOMS COME ABOUT?
8 A. YES, HE HAS.
9 Q. DO YOU TRY TO DO THOSE?
10 A. I TRY TO DO THEM.
11 Q. IN SPITE OF DOING THOSE DO YOU STILL HAVE, I GUESS,
12 BREAKTHROUGH EPISODES OF ANGER?
13 A. I DO HAVE BREAKTHROUGH. I TRY TO -- I TRY TO DO
14 WHAT HE ASK ME TO, BUT I STILL HAVE BREAKTHROUGH. I
15 TRY HARD NOT TO, BUT IT JUST -- WHEN A HEAD INJURY
16 IS THERE, IT JUST -- IT'S DIFFERENT IN MY LIFE. MY
17 LIFE HAS BEEN TOTALLY DIFFERENT WITH THIS HEAD
18 INJURY.
19 Q. WITH RESPECT TO YOUR HEAD INJURY, HOW DO YOU
20 PERCEIVE YOUR LIFE BEING DIFFERENT? HOW DO YOU VIEW
21 YOUR LIFE NOW AS OPPOSED TO HOW IT WAS BEFORE?
22 A. NOW, WHENEVER I SEE SOMETHING, IT'S THE WAY VICTOR
23 SEE IT. IT DOESN'T MATTER WHAT NO ONE ELSE SEES;
24 IT'S HOW VICTOR SEES IT. BEFORE I COULD -- I COULD
25 -- SOMEBODY COULD REASON WITH ME, AND THAT WOULD BE

1 FINE. NOW IT'S VICTOR'S WAY OR NO WAY, BECAUSE
2 THAT'S HOW I SEE IT, AND IT DOESN'T MATTER. I CAN
3 -- I CAN GIVE YOU A PRIME EXAMPLE. YOU COULD BE
4 STANDING OVER THERE AND IF I'M THINKING THAT YOU'RE
5 MY BROTHER AND IT'S MY MIND THAT YOU'RE MY BROTHER,
6 AIN'T NO WAY IN THE WORLD YOU COULD CHANGE MY MIND.
7 YOU MIGHT WOULD HAVE TO CALL THE COPS OR YOU TRY TO
8 TELL ME, "VICTOR, I'M NOT YOUR BROTHER," AND I JUST
9 CANNOT SEE IT, CANNOT SEE IT, BECAUSE IN MY MIND, MY
10 MIND TELLS ME SOMETHING, AND THAT'S WHAT IT IS.
11 THAT'S WHAT IT IS. THERE'S NO CHANGING MY MIND.
12 Q. VICTOR, IN SPITE OF WHAT THE DOCTORS HAVE WRITTEN
13 ABOUT YOUR CONDITION, DO YOU HAVE ANY KIND OF
14 PERSONAL OPINION AS TO WHETHER YOU SUFFER FROM
15 DEPRESSION?
16 A. I DEFINITELY DO.
17 Q. ARE YOU DEPRESSED?
18 A. YES, I AM.
19 Q. HOW HAS THAT AFFECTED YOU? IN WHAT WAY DO YOU FEEL
20 YOUR DEPRESSION? HOW DOES IT FEEL, IF YOU HAD TO
21 DESCRIBE IT?
22 A. I'M DEPRESSED. I CAN LOOK AROUND AT MY HOUSE, SEE
23 THINGS THAT NEED TO BE DONE, THINGS THAT I USED TO
24 COULD DO THAT I CAN'T DO, THINGS THAT I USED TO DO
25 FOR PEOPLE THAT I CANNOT DO ANYMORE, AND THAT REALLY

1 -- IT TEARS ME APART. IT TEARS ME COMPLETELY APART,
2 BECAUSE OF THE FACT KNOWING THE THINGS THAT I USED
3 TO DO I CANNOT DO ANYMORE.
4 Q. I THINK THE RECORDS INDICATE, AND I THINK FROM
5 PERSONAL KNOWLEDGE I REMEMBER, HAVE YOU LOST BOTH OF
6 YOUR PARENTS IN THE LAST COUPLE OF YEARS?
7 A. I LOST MY DAD. I LOST AN AUNT -- I MEAN AN UNCLE,
8 AND THEY WAS LIKE THREE MONTHS APART TO THE DAY, AND
9 THAT WAS A BIG TOLL ON ME. AND DURING THE SAME TIME
10 I LOST DR. DEAL AT THE SAME TIME, AND THAT TOOK A
11 BIG TOLL ON MY LIFE. I MEAN, I WAS SO DEPRESSED.
12 Q. PRIOR TO YOUR WORK INJURY, HAD YOU BEEN RESPONSIBLE
13 FOR CARETAKING FOR YOUR PARENTS IN SOME DEGREE?
14 A. PRIOR TO MY WORK INJURY?
15 Q. YES, SIR.
16 A. WHAT I DOES, I TRY TO HELP MOMMA AS MUCH AS I CAN,
17 BUT I CAN'T DO IT ANYMORE. SHE'S THERE BY HERSELF,
18 AND THAT BOTHERS ME A WHOLE LOT, KNOWING THAT SHE'S
19 THERE BY HERSELF, AND SHE'S AN OLDER LADY. AND WE
20 ALL IN HERE KNOW TODAY, YOU GOT AN OLDER PERSON AT
21 THE HOUSE, SOMEONE CAN COME THROUGH AND OFFER THEM
22 SOMETHING, AND IT MAY SOUND GOOD TO THEM, BUT AT THE
23 SAME TIME I LET HER KNOW, "THAT'S WHAT MY WIFE IS
24 THERE FOR, TO HELP YOU OUT, TO LET YOU KNOW; DON'T
25 FALL FOR ANYTHING THAT SOMEONE IS TRYING TO BRING TO

1 YOU." SOME THINGS I CAN'T THINK STRAIGHT ON. I
2 CANNOT THINK STRAIGHT WHETHER I NEED TO MAKE THE
3 DECISION OR NOT, SO I RELY ON MY WIFE.
4 Q. VICTOR, ARE YOU IN YOUR HOUSE DAILY BY YOURSELF?
5 A. YES, I AM.
6 Q. NO ONE ELSE IS IN THE HOUSEHOLD WITH YOU GENERALLY?
7 A. NO, IT'S NOT.
8 Q. WHO PREPARES YOUR MEALS?
9 A. MY WIFE PREPARES MY MEAL BEFORE SHE GOES TO WORK, OR
10 EITHER THE NIGHT BEFORE, AND SHE HAVE EVERYTHING
11 ALREADY LAID OUT FOR ME TO EAT BEFORE SHE GOES TO
12 WORK. SHE TAKE CARES OF ALL MY FOOD. SHE MAKES
13 SURE THE FOODS IS ALREADY DONE. THE ONLY THING I
14 HAVE TO DO IS TRY TO MAKE IT TO THE MICROWAVE.
15 Q. I WANT TO SHIFT OUR FOCUS A LITTLE BIT AND TALK TO
16 YOU ABOUT SOME OF YOUR SYMPTOMS THAT YOU'VE GOT IN
17 YOUR UPPER EXTREMITIES, OKAY?
18 A. OKAY.
19 Q. WHAT, IF ANY, PROBLEMS DO YOU HAVE WITH YOUR ARMS
20 AND YOUR HANDS?
21 A. I DON'T HAVE THE STRENGTH IN MY HAND THAT I USED TO
22 HAVE. WHEN IT COMES DOWN TO PUTTING MY CLOTHES ON,
23 MY WIFE HAS TO HELP ME PUT MY CLOTHES ON. SHE WILL
24 HAVE TO -- MY FINGERS, THEY DON'T WORK LIKE THEY
25 SHOULD. THEY GET NUMB. THEY'RE NUMB ON THE END.

1 THEY'RE COLD, AND THAT'S WHY I'M HERE CONSTANTLY
2 RUBBING THEM NOW.
3 Q. WHEN YOU SAY YOU'RE RUBBING THEM, ARE YOU REFERRING
4 TO NUMBNESS IN BOTH HANDS?
5 A. NUMBNESS IN BOTH HANDS.
6 Q. IS IT ALL FINGERS?
7 A. YES, IT IS.
8 Q. ON BOTH HANDS?
9 A. YES, IT IS.
10 Q. IS THAT CONSTANT, OR DOES IT COME AND GO?
11 A. NO, IT'S CONSTANT.
12 Q. THE WEAKNESS THAT YOU DESCRIBED, IS THAT WEAKNESS IN
13 BOTH HANDS OR JUST ONE?
14 A. BOTH HANDS.
15 Q. AND HOW DOES THAT WEAKNESS AFFECT YOU? DOES IT
16 AFFECT YOUR ABILITY TO PUSH, PULL, GRASP THINGS?
17 A. WELL, IF MY WIFE AND I ARE SITTING AT THE TABLE, SHE
18 SAYS, "VICTOR, WILL YOU PASS ME THE SALT," I MAY
19 DROP THE SALT OR THE PEPPER ON THE WAY WHILE I'M
20 TRYING TO PASS IT 'CAUSE MY HAND IS SO WEAK.
21 Q. SO SOMETHING AS SMALL AS A LITTLE ---
22 A. SALT SHAKER.
23 Q. --- SALT SHAKER IS DIFFICULT FOR YOU TO HOLD ON TO?
24 A. YES, IT IS.
25 Q. ARE THERE OTHER ITEMS THAT YOU DROP AROUND THE

1 HOUSEHOLD?
2 A. DRINKS. SOMETIMES WHEN I'M EATING, I DROP MY FORK
3 I'M EATING WITH. WHEN IT COMES DOWN TO CUTTING MY
4 MEAT, MY WIFE HAVE TO ALREADY HAVE THAT CUT UP FOR
5 ME FOR SUPPER OR DINNER, WHATEVER I'M EATING, BEFORE
6 SHE -- WHILE SHE'S AT WORK.
7 Q. DO YOU NOT HAVE THE ABILITY TO USE THE UTENSILS
8 YOURSELF?
9 A. NO, I DO NOT, TO A CERTAIN POINT TRYING TO EAT.
10 Q. IS IT -- IS IT SMALL THINGS THAT YOU HAVE TROUBLE
11 WITH AS OPPOSED TO BIG THINGS, OR DO YOU HAVE A
12 PROBLEM EQUALLY WITH BIG THINGS AS WELL?
13 A. WELL, IT COULD BE BOTH.
14 Q. HOW ABOUT THINGS LIKE USING THE STEERING WHEEL WHEN
15 GRABBING THE STEERING WHEEL AND DRIVING FROM
16 BISHOPVILLE TO COLUMBIA TO GO SEE DR. BERGMANN?
17 WHAT, IF ANY, LIMITATIONS DO YOU HAVE WITH DRIVING?
18 A. THE LIMITATION I HAVE WITH DRIVING, I GET TIRED. MY
19 ARMS GET TIRED, SO I WILL PULL OFF AND TAKE A BREAK,
20 TAKE A BREAK FOR A LITTLE WHILE. IF I FEEL LIKE I
21 CAN MAKE IT ON, I GO AHEAD ON. IF I CAN'T, I STOP
22 AND TAKE ANOTHER BREAK.
23 Q. WHAT ABOUT DRIVING IS DIFFICULT FOR YOU; AS FAR AS
24 FOLLOWING THE DIRECTIONS OR DEALING WITH HAVING TO
25 NAVIGATE THROUGH HEAVY TRAFFIC?

1 A. WHAT I DO WITH MY DOCTOR'S APPOINTMENT, I TRY TO
2 MAKE MY APPOINTMENTS WHERE I DON'T HAVE TO DEAL WITH
3 A LOT OF TRAFFIC. SOMETIME I DO, AND SOMETIME --
4 MOST TIME I DON'T. I'D SAY 80 PERCENT OF THE TIME I
5 DON'T HAVE TO DEAL WITH A LOT OF TRAFFIC, BECAUSE
6 DR. BERGMANN HAS WORKED WITH ME TO WHERE I WON'T
7 HAVE TO COME IN EARLY SO I WON'T HAVE TO DEAL WITH
8 THE TRAFFIC.
9 Q. AND HOW OFTEN DO YOU DRIVE YOURSELF TO AN
10 APPOINTMENT VERSUS THE WIFE DRIVING YOU?
11 A. MY WIFE DRIVE ME TO THE APPOINTMENT, I WOULD SAY, 80
12 TO 85 PERCENT OF THE TIME.
13 Q. AND WHY IS THAT?
14 A. BECAUSE SHE TAKES OFF AND SHE KNOW THAT I CANNOT
15 HANDLE THE TRIP BY MYSELF, AND SHE MAKING SURE --
16 WANT TO MAKE SURE I GET THERE SAFE -- SAFELY. AND
17 WHEN I GET THERE, I WILL CALL HER OR EITHER SEND HER
18 A TEXT AND LET HER KNOW THAT I MADE IT SAFELY.
19 Q. NOW, GOING BACK TO DOING SOME OF THOSE ACTIVITIES OF
20 DAILY LIVING, LIKE DRESSING, YOU SAID THE WIFE HELPS
21 YOU DRESS?
22 A. SHE SHOWERS ME AS WELL.
23 Q. WHAT PROBLEMS, IF ANY, DO YOU HAVE WITH DRESSING
24 YOURSELF?
25 A. I CANNOT BUTTON THE SHIRT BY MYSELF.

1 Q. OKAY. YOU'VE GOT A -- I CONSIDER THAT ONE OF THOSE
2 POLO GOLF SHIRT-TYPE SHIRTS ON TODAY?
3 A. YES.
4 Q. AND THEY'RE NOT -- MAYBE THERE'S A BUTTON ON IT. I
5 CAN'T REALLY SEE FROM VERY FAR AWAY, BUT IT LOOKS
6 LIKE THERE'S A ---
7 A. YEAH, THERE'S A BUTTON ON IT.
8 Q. I DON'T SEE THAT YOU'VE GOT ANYTHING BUTTONED ON
9 THERE. SO YOU DIDN'T HAVE TO BUTTON THE SHIRT UP,
10 AND NOBODY BUTTONED YOU UP TODAY, RIGHT?
11 A. RIGHT.
12 Q. DO YOU WEAR A SHIRT LIKE I'VE GOT ON, FOR INSTANCE,
13 JUST ONE OF THESE BUTTON-UP SHIRTS?
14 A. I DON'T. NO, I DON'T.
15 Q. DO YOU EVER GO TO CHURCH ANYMORE?
16 A. YES, I DO.
17 Q. IF YOU GO TO CHURCH, DO YOU HAVE TO WEAR ONE OF
18 THESE BUTTON-UP SHIRTS?
19 A. NO, I DON'T.
20 Q. WHAT DO YOU WEAR?
21 A. I JUST WEAR A CASUAL SHIRT LIKE WHAT I HAVE ON NOW.
22 Q. OKAY. HAVE YOU HAD TO CHANGE THE WAY YOU DRESS OR
23 NOT WEAR CERTAIN THINGS BECAUSE OF ANY DIFFICULTY
24 YOU'RE HAVING DRESSING?
25 A. YES, I HAVE.

1 Q. SO, WHAT ITEMS OF CLOTHING WOULD SHE HELP YOU PUT
2 ON? DOES SHE HELP YOU PUT ON YOUR SHIRT, YOUR
3 PANTS, YOUR SHOES? WHAT DOES SHE DO FOR YOU?
4 A. SHE HELPS ME PUT MY SHIRT, MY PANTS, MY SHOES, MY
5 SOCKS, TIES THEM UP.
6 Q. AND WHAT DIFFICULTY DO YOU HAVE PHYSICALLY THAT
7 PROHIBITS YOU OR CAUSES YOU SUCH DIFFICULTY THAT YOU
8 REALLY DON'T DO THOSE YOURSELF?
9 A. WELL, WHEN I GO DOWN TO TIE MY SHOES UP, MY FINGERS
10 DOESN'T WORK RIGHT FOR ME TO TRY TO TIE THE SHOES
11 UP. SO SHE HELPS ME PUT THE SHOES ON; SHE HELPS ME
12 GET MY SOCKS ON, AS FAR AS PULLING THEM UP ON MY
13 LEG. SHE HELPS ME PUT MY PANTS ON, ESPECIALLY
14 FASTENING THEM.
15 Q. VICTOR, I SEE THAT YOU'VE GOT ONE OF THOSE FOUR-
16 PRONGED CANES IN FRONT OF YOU?
17 A. YES, SIR.
18 Q. WHY ARE YOU USING THE CANE? WHAT PROBLEMS DO YOU
19 HAVE?
20 A. PROBLEMS WITH MY BALANCE AND WALKING.
21 Q. WHAT PROBLEMS DO YOU HAVE WITH WALKING?
22 A. IF I DON'T HAVE SOMETHING TO BRACE ONTO, I WILL
23 BASICALLY FALL.
24 Q. DID YOU REPORT THOSE SYMPTOMS TO DR. SANDOZ?
25 A. YES, I HAVE.

1 Q. AND I UNDERSTAND THAT HE'S WRITTEN YOU A
2 PRESCRIPTION FOR A MOBILITY SCOOTER?
3 A. YES, BECAUSE OF THE REASON, IF MY WIFE AND I GO
4 SOMEPLACE AND WE'RE OUT, THE FIRST THING I'M LOOKING
5 FOR IS SOMEPLACE TO SIT DOWN BECAUSE I'M SHORTNESS
6 OF BREATH BY THE TIME WE GET IN THERE, AND I JUST
7 SIT IN A STORE AND JUST SIT AND SIT, AND MY WIFE,
8 SHE GETS KIND OF AGITATED BECAUSE SHE KNOWS I'M NOT
9 COMFORTABLE. SHE CANNOT SHOP THE WAY THAT SHE WANTS
10 TO SHOP. AND WE DON'T DO THE THINGS THAT WE USED TO
11 DO. NOT THAT WE DO A LOT OF SHOPPING, BUT THE
12 LITTLE BIT THAT WE DO GO OUT, THE FIRST THING I'M
13 DOING IS TRYING TO FIND ME A PLACE TO SIT BECAUSE I
14 KNOW I CAN'T STAND BUT SO LONG.
15 Q. WHAT, IF ANY, WEAKNESS DO YOU HAVE IN YOUR LEGS?
16 A. THEY ARE VERY WEAK. AS YOU NOTICED A WHILE AGO WHEN
17 I GET UP TO GET MY WATER, I LIKED TO FALL. MY LEGS
18 ARE VERY WEAK.
19 Q. DO YOU HAVE AN OPINION ON WHETHER YOU HAVE THE SAME
20 MUSCLE MASS THAT YOU'VE HAD IN YOUR QUADRICEPS, YOUR
21 HAMSTRINGS, AND YOUR CALF MUSCLES THAT YOU DID BACK
22 IN 2011 WHEN YOU GOT HURT, OR HAVE THEY GOTTEN
23 SMALLER?
24 A. THEY'VE GOTTEN WORSER.
25 Q. WHEN YOU SAY WORSE, DOES THAT MEAN MORE SYMPTOMS OR

1 HAVE ---
2 A. MORE SYMPTOMS. THEY GOT WEAK ---
3 Q. --- THEY GOTTEN PHYSICALLY SMALLER?
4 A. WELL, SMALLER, WEAKNESS. I DON'T KNOW WHAT YOU CALL
5 -- WHAT YOU MEAN BY SMALLER NOW? THEY'VE GOTTEN
6 WEAKER?
7 Q. WELL, HAS YOUR MUSCLE IN YOUR -- WITH YOUR --
8 LOOKING AT YOUR EYES -- WITH YOUR EYES LOOKING AT
9 THE MUSCLE TONE THAT YOU USED TO HAVE, ---
10 A. OKAY.
11 Q. --- HAS IT REMAINED THE SAME OR HAS IT GOTTEN
12 SMALLER?
13 A. GOTTEN SMALLER.
14 Q. AND DO YOU EVER -- I THINK YOU TESTIFIED ABOUT THIS.
15 SOMETIMES YOU FALL IF YOU'RE NOT USING THE CANE?
16 A. YES, I DO.
17 Q. DO YOU REPORT THOSE SYMPTOMS TO THE DOCTORS AND
18 THOSE FALLS TO THE DOCTORS?
19 A. YES.
20 Q. VICTOR, THE RECORDS FROM DR. SANDOZ FROM FEBRUARY OF
21 2016 AND APRIL OF 2016 REFERENCE THAT YOU COMPLAINED
22 OF BLADDER PROBLEMS?
23 A. YES.
24 Q. WHAT DID YOU TELL DR. SANDOZ ABOUT ANY BLADDER
25 PROBLEMS YOU WERE HAVING?

1 A. IF I'M SITTING AND RELAXING, JUST RELAXING, I NOTICE
2 I HAVE A LITTLE LEAKAGE FROM MY BLADDER, AND DR.
3 SANDOZ ---
4 Q. AND YOU CAN'T TELL US WHAT HE SAID.
5 A. OKAY.
6 Q. I'LL JUST CAUTION YOU. BUT I JUST WANT TO KNOW WHAT
7 YOU REPORTED TO HIM. WHAT SYMPTOMS DID YOU HAVE
8 THAT MADE THEIR WAY INTO HIS CHART NOTES?
9 A. WHAT I REPORTED TO HIM WAS THAT I HAVE LEAKAGE WHEN
10 I'M RELAXING. WHEN I'M SITTING UP IN THE CHAIR,
11 TAKING A NAP, JUST RELAXING, I -- I NOTICE BEFORE I
12 GO TO THE BATHROOM I WOULD HAVE A LEAKAGE.
13 Q. AND YOU VISIBLY WET YOUR PANTS?
14 A. YES, I DO.
15 Q. HOW OFTEN DOES THAT OCCUR?
16 A. I HAVEN'T BEEN KEEPING COUNT OF IT, BUT IT OCCURS
17 PRETTY OFTEN.
18 Q. MORE THAN ONE TIME A DAY?
19 A. YES, IT DOES. I DON'T KNOW EXACTLY HOW MANY TIMES A
20 DAY, BUT IT DOES OCCUR QUITE A FEW TIMES A DAY.
21 Q. DOES IT HAPPEN EXCLUSIVELY IN THE DAYTIME, OR DOES
22 IT HAPPEN EXCLUSIVELY AT NIGHTTIME?
23 A. DAY AND NIGHT.
24 Q. VICTOR, WHAT, IF ANY, PROBLEMS DO YOU HAVE WITH
25 ERECTILE DYSFUNCTION SINCE THIS ACCIDENT? AND I

1 KNOW THIS IS A SENSITIVE THING TO SAY IN FRONT OF
2 THE COURT AND IN FRONT OF LADIES.
3 A. WELL, THE QUESTION YOU ASKED, I'M GOING TO BE HONEST
4 WITH YOU. BEFORE I HAD MY ACCIDENT, I'VE HAD -- MY
5 WIFE AND I HAVE INTERCOURSE ANYWHERE FROM THREE TO
6 FOUR TIMES A WEEK. AFTER THE ACCIDENT, IT'S MAYBE
7 ONCE OR TWICE A MONTH.
8 Q. IS THAT WITH OR WITHOUT THE USE OF A MEDICATION TO
9 HELP YOU ACHIEVE AN ERECTION?
10 A. WITH THE MEDICATION.
11 Q. SO, TAKE US THROUGH KIND OF A DAY IN THE LIFE, IF
12 YOU WILL, VICTOR, OF HOW YOU SPEND YOUR WAKING HOURS
13 AND THEN HOW YOU FINALLY DECIDE TO RETIRE FOR THE
14 EVENING. WHAT DO YOU DO EVERY DAY?
15 A. IT'S A -- I -- WHEN I WAKES UP MY WIFE COMES AROUND
16 AND MAKES SURE I'M OKAY. THAT'S THE FIRST THING SHE
17 DOES, "VICTOR, ARE YOU OKAY?"
18 Q. ARE YOU PRESENTLY SLEEPING IN THE SAME BEDROOM, IN
19 THE SAME BED TOGETHER EVERY NIGHT?
20 A. DEFINITELY, BECAUSE OF THE FACT MY WIFE DON'T WANT
21 TO MAKE SURE THAT I GET SICK DURING THE NIGHT OR
22 FALL OUT THE BED, WHATEVER, BECAUSE WITH MY SHAKING
23 THAT I HAVE AT NIGHT, MY BODY SHAKES SO. SO SHE
24 WANT TO MAKE SURE THAT SHE'S THERE WITH ME TO MAKE
25 SURE I DON'T FALL OR HURT MYSELF, BECAUSE THERE'S

1 BEEN TIMES I WOULD ACTUALLY FIGHT IN MY SLEEP AND
2 REALLY HIT HER IN THE SIDE AND NOT EVEN KNOW IT. I
3 HAVE BAD NIGHTMARES AND FIGHT MYSELF IN MY SLEEP AT
4 NIGHT.
5 Q. DO YOU REMEMBER NIGHTMARES WHEN YOU GET UP THE NEXT
6 MORNING? DO YOU REMEMBER THAT YOU'VE HAD
7 NIGHTMARES?
8 A. SOMETIME I DO, AND SOMETIME I DON'T, AND I ASK HER
9 WHAT'S GOING ON WITH HER, AND SHE SAID, "YOU HAD A
10 BAD NIGHTMARE." SHE TELLS ME SEVERAL TIMES THAT SHE
11 HAVE WAKEN ME UP, AND I DON'T EVEN KNOW NOTHING
12 ABOUT IT.
13 Q. SO SHE GETS UP, CHECKS ON YOU IN THE MORNING, AND
14 THEN WHAT HAPPENS?
15 A. SHE GETS ME UP, GET ME TO THE BATHROOM, GET A
16 SHOWER, HELP ME WITH A SHOWER.
17 Q. DOES SHE HELP BATHE YOU EVERY MORNING?
18 A. YES, SHE DOES.
19 Q. DO YOU DO MOST OF YOUR BATHING AND PERSONAL HYGIENE
20 THINGS IN THE MORNING?
21 A. IN THE MORNING. SHE BATHES ME AGAIN WHEN I GO TO
22 SLEEP AT -- BEFORE WE GO TO BED AT NIGHT.
23 Q. DO YOU BATHE DOWN IN A TUB, OR ARE YOU STANDING IN A
24 STANDUP SHOWER?
25 A. WE GET IN A STANDUP SHOWER.

1 Q. OKAY. AND WHAT KIND OF THINGS DOES SHE DO FOR YOU
2 IN THE SHOWER?
3 A. EVERYTHING THAT GOT TO BE DONE.
4 Q. I MEAN, DOES SHE HAVE TO WASH YOU HAIR?
5 A. MY HAIR, MY ARMS, MY LEGS, MY WHOLE BODY.
6 Q. OKAY. SO SHE USES A BAR OF SOAP OR ONE OF THOSE
7 PUMP THINGS OF SOAP AND ---
8 A. A BAR OF SOAP.
9 Q. --- WASHES YOU DOWN?
10 A. YES.
11 Q. RINSES YOU OFF?
12 A. YES, SIR.
13 Q. DOES SHE HELP TOWEL-DRY YOU?
14 A. YES, SHE DOES. DEFINITELY GOT TO DO THAT.
15 Q. WHAT DOES SHE DO AFTER -- OR WHAT DO YOU DO AFTER
16 SHE'S GOT YOU BATHED?
17 A. WELL, SHE HELP ME BACK TO THE BEDROOM, AND I -- SHE
18 HELP ME GET DRESSED, AND I JUST SIT BACK AND RELAX
19 ON THE COUCH.
20 Q. IS SHE PRESENTLY WORKING AT HER JOB?
21 A. SHE'S PRESENTLY WORKING, BUT SHE'S NOT WORKING FULL
22 TIME.
23 Q. AND WHO DOES SHE WORK FOR PRESENTLY?
24 A. SHE WORKS FOR WELLS FARGO.
25 Q. WHAT DOES SHE DO FOR WELLS FARGO?

1 A. SHE'S A BANKER.
2 Q. YOU SAY A BANKER?
3 A. YES, SHE'S A BANKER.
4 Q. OKAY. SO, WHEN YOU SAY SHE DOESN'T WORK FULL TIME,
5 HOW MANY DAYS OUT OF A GIVEN WEEK DOES SHE GO TO THE
6 OFFICE?
7 A. PROBABLY TWO TO THREE DAYS A WEEK, I'M GUESSING,
8 SOMEWHERE ALONG IN THERE.
9 Q. AND THE OTHER DAYS SHE DOES WHAT; SHE STAYS AT HOME?
10 A. YES. SHE TAKES ME TO MY DOCTORS' APPOINTMENTS. SHE
11 BASICALLY TAKES ME TO MY DOCTORS' APPOINTMENTS.
12 Q. HAS SHE HAD TO REQUEST, IF YOU KNOW, ANY KIND OF
13 SPECIAL LEAVE OF ABSENCE OR ANY KIND OF SPECIAL
14 ALLOWANCE TO ALLOW HER TO NOT WORK ON A FULL-TIME
15 BASIS?
16 A. YES, SHE HAS.
17 Q. HAVE THEY GRANTED HER THAT, TO YOUR KNOWLEDGE?
18 A. YES, THEY GRANTED HER THAT, TO MY KNOWLEDGE, BECAUSE
19 THEY KNOW WHAT I'M GOING THROUGH ON THE JOB.
20 **BY MR. LOCKHART:**
21 YOUR HONOR, I'D HAVE TO OBJECT TO ANYTHING ---
22 **BY THE COMMISSIONER:**
23 SUSTAINED.
24 **BY MR. LOCKHART:**
25 --- THE CLAIMANT'S WIFE'S EMPLOYER KNOWS ABOUT

1 THIS CASE.

2 **BY THE COMMISSIONER:**

3 SUSTAINED.

4 **DIRECT EXAMINATION RESUMED BY MR. CHANDLER:**

5 Q. SO, VICTOR, WHEN YOU GET TO YOUR COUCH AND THEN YOU
6 RELAX, HOW DO YOU SPEND THE REST OF YOUR MORNING OR
7 AFTERNOON?

8 A. THAT'S IT. I'M STANDING THERE -- I'M SITTING THERE
9 RELAXING. I MAY LOOK AT T.V. THEN THE T.V. START
10 LOOKING AT ME.

11 Q. DO YOU TAKE A NAP?

12 A. YES, I DO. THAT'S WHAT I MEANT BY THE T.V. START
13 LOOKING AT ME. I'M TAKING A NAP.

14 Q. VICTOR, YOU LIVE OUT ON SOME PROPERTY IN THE, I
15 GUESS, THE BISHOPVILLE COMMUNITY?

16 A. YES.

17 Q. DO YOU HAVE A YARD?

18 A. YES, I DO.

19 Q. HOW MUCH LAND DO YOU HAVE OUT THERE?

20 A. I HAVE FIVE ACRES OUT THERE.

21 Q. HOW LONG HAVE YOU HAD THAT PROPERTY?

22 A. I'M NOT GOOD AT DATES. SOMEWHERE BETWEEN 20, 25
23 YEARS.

24 Q. DO YOU STILL HAVE A MORTGAGE ON YOUR HOME AND LAND?

25 A. YES, I DO.

1 Q. AND HOW MUCH IS IT?
2 A. HOW MUCH IS THE MORTGAGE?
3 Q. THE MONTHLY PAYMENT.
4 A. THE MONTHLY PAYMENT IS AROUND $1,400 A MONTH.
5 Q. AND, VICTOR, WHAT OTHER EXPENSES DO YOU HAVE IN
6 ADDITION TO YOUR MORTGAGE? DO YOU HAVE ANY LOANS
7 FOR AUTOMOBILES?
8 A. I HAVE LOANS FOR AUTOMOBILES. I HAVE INSURANCE. I
9 HAVE TAXES ON AUTOMOBILES AS WELL.
10 Q. AND AT THE TIME OF THIS INJURY IN JUNE OF 2011, YOU
11 ACTUALLY HAD ANOTHER BUSINESS? YOU HAD SELF-
12 EMPLOYMENT AS WELL, IS THAT RIGHT?
13 A. YES, I HAVE.
14 Q. I THINK YOUR BUSINESS WAS CALLED BENJAMIN AND SON
15 ---
16 A. BENJAMIN AND SON TOWING.
17 Q. --- TOWING?
18 A. YES, IT IS.
19 Q. OKAY. WHAT WAS THE NATURE OF THAT BUSINESS? WHAT
20 DID YOU DO?
21 A. I'D GO OUT AND TOW PEOPLE CARS THAT NEED TO BE
22 TOWED. IT WAS SOMETHING THAT I DID EVEN WHEN I WAS
23 WORKING, EVEN AFTER THE HOURS I WORKED. IF SOMEONE
24 WAS TO CALL ME FOR A TOW TO HELP SOMEONE OUT, I
25 WOULD GO OUT AND DO THAT BECAUSE THAT WAS MY

1 PASSION, AND THAT'S WHAT I WANTED TO DO WHEN I
2 RETIRED. SO I BOUGHT ME A TRUCK, AND I WAS ABLE TO
3 BUY THAT TRUCK BECAUSE OF MY JOB. I WAS MAKING "X"
4 AMOUNT OF DOLLARS AND MAKING GOOD MONEY.
5 Q. DID YOU PAY FOR THAT TRUCK OUTRIGHT, OR DO YOU STILL
6 HAVE A LOAN ON IT?
7 A. NO, I PAID FOR IT OUTRIGHT.
8 Q. AND, VICTOR, HOW MUCH INCOME WOULD YOU SAY THAT
9 BENJAMIN AND SON TOWING WAS EARNING ON AN ANNUAL
10 BASIS BACK WHEN YOU GOT HURT?
11 A. SOMEWHERE AROUND LIKE 10,000, $15,000 A YEAR
12 ROUGHLY.
13 Q. AND WOULD YOU CLAIM THAT ON YOUR TAXES ANNUALLY?
14 A. YES, I DID.
15 Q. DID YOU HAVE A TAX PREPARER OR CPA THAT WOULD ASSIST
16 YOU WITH THOSE ---
17 A. YES, SIR.
18 Q. --- MATTERS?
19 A. YES, SIR.
20 Q. HAVE YOU BEEN ABLE TO EARN ANY OF THAT INCOME SINCE
21 JUNE OF 2011 WITH RESPECT TO THE TOWING BUSINESS?
22 A. NO, I HAVEN'T.
23 Q. DID YOU LOSE ALL OF YOUR ACCOUNTS, IF YOU WILL?
24 A. YES, I HAVE.
25 Q. DO YOU STILL OWN THE TRUCK?

1 A. YES, I DO.
2 Q. WHERE DOES IT SIT?
3 A. IT SITS AT MY HOUSE.
4 Q. AND, VICTOR, AT THE TIME OF YOUR WORK INJURY IN JUNE
5 OF 2011, HAD YOU STARTED ANY KIND OF BIG,
6 SUBSTANTIAL HOME IMPROVEMENTS ON THE HOME OR THE
7 PROPERTY, SUCH AS WERE YOU BUILDING A GARAGE, WERE
8 YOU BUILDING A SHED, OR WERE YOU DOING ANYTHING OF
9 THAT SORT?
10 A. WELL, BEFORE THIS HAPPENED I HAD A CEMENT PAD OUT
11 THERE THAT I PLANNED TO BUILD A STORAGE BUILDING FOR
12 MY VEHICLE, AND THE PAD IS JUST STILL SITTING THERE
13 BECAUSE I WAS NOT ABLE TO AFFORD TO DO ANYTHING WITH
14 IT.
15 Q. SO YOU HAD STARTED THE CONSTRUCTION PROCESS, GOTTEN
16 THE PAD POURED, AND THEN IT SAT?
17 A. IT'S SITTING RIGHT NOW, YEAH.
18 Q. AND WHO DOES ANY OF YOUR, I GUESS, OUTSIDE
19 RESPONSIBILITIES, SUCH AS LAWN CARE, ANY KIND OF
20 MAINTENANCE ON THE EXTERIOR OF THE HOUSE?
21 A. WELL, I GOT -- AS FAR AS LAWN CARE, MY WIFE, SHE WAS
22 DOING SOME OF THAT, AS MUCH OF THAT AS SHE CAN. IT
23 DON'T LOOK NOTHING LIKE IT WAS BEFORE. I'M NOT
24 TRYING TO PUT LADIES DOWN, AND I KNOW Y'ALL DO A
25 GOOD JOB ON LAWN CARE AS WELL, 'CAUSE YOU GOT A LOT

1 OF LADIES DOES A REAL GOOD JOB. BUT IT'S NOTHING
2 LIKE THE WAY IT USED TO BE, AND EVERY DAY WHEN I
3 LOOK OUT THERE IT HURTS SO BAD THE WAY MY YARD USED
4 TO LOOK AND THE WAY IT LOOKS NOW. AND AS FAR AS
5 MAINTENANCE, MY FATHER-IN-LAW USED TO DO SOME OF IT,
6 BUT NOW I CAN'T AFFORD TO HAVE ANY OF IT DONE.
7 Q. SO THAT EXTRA INCOME THAT YOU HAD FROM THE TOWING
8 BUSINESS, DID YOU USE SOME OF THAT INCOME TO FUND
9 HOUSEHOLD RESPONSIBILITIES, CONSTRUCTION PROJECTS
10 AROUND THE HOUSEHOLD, THINGS OF THAT SORT?
11 A. YES, SIR. IT WAS A BIG, BIG HELP.
12 Q. AND, IN FACT, I THINK IN 2011 YOU WERE CONSIDERED AT
13 OUR STATE MAXIMUM COMPENSATION RATE, AND YOU WERE
14 CAPPED ---
15 A. YES.
16 Q. --- AT WHAT EARNINGS YOU COULD GET THROUGH WORKERS'
17 COMPENSATION, IS THAT RIGHT?
18 A. THAT'S RIGHT.
19 Q. BUT, IN FACT, YOU ACTUALLY MADE WELL ABOVE $700 WHEN
20 YOU WORKED WITH REXAM, IS THAT RIGHT?
21 A. A WHOLE LOT MORE.
22 Q. AND YOU HAVEN'T BEEN ABLE TO REPLACE THAT INCOME?
23 A. NO, I HAVE NOT.
24 Q. VICTOR, DO YOU HAVE HOUSEHOLD NEEDS NOW, SUCH AS
25 REPAIR OF A ROOF, REPLACEMENT OF ---