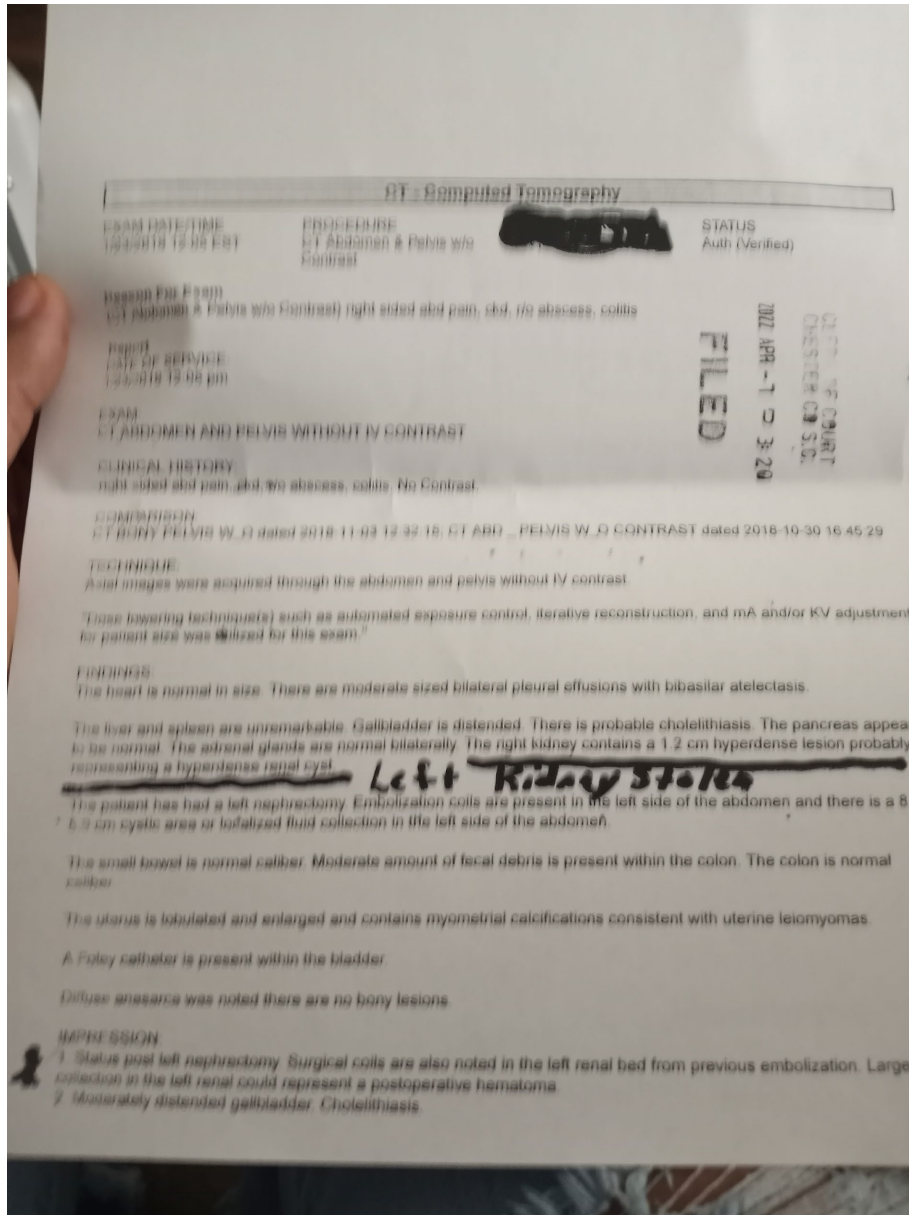


Apr 07 2022

SC Court of Appeals

From: Tanya Murphy
To: Court Of Appeals Filings
Subject: Make Me Stop Exposing CORRUPTION!!!
Date: Thursday, April 7, 2022 3:50:03 PM

*** EXTERNAL EMAIL: This email originated from outside the organization. Please exercise caution before clicking any links or opening attachments. ***



CT Abdomen & Pelvis w/o Contrast
* Final Report *

COLEMAN [REDACTED]

Result Type: CT Abdomen & Pelvis w/o Contrast
Result Date: October 30, 2018 16:54 EDT
Result Status: Auth (Verified)
Result Title: CT Abdomen and Pelvis w/o Contrast
Performed By: [REDACTED] October 30, 2018 17:02 EDT
Verified By: [REDACTED] October 30, 2018 17:02 EDT
Encounter info: [REDACTED] 10/30/2018 -

* Final Report *

FILED
2017 APR - 1 3:20
CLERK OF COURT
CHESTER CO PA

Reason For Exam
Abd pain, unspecified

CT Abdomen and Pelvis w/o Contrast
DATE OF SERVICE:
10/30/2018 4:54 pm

EXAM:
CT ABDOMEN AND PELVIS WITHOUT IV CONTRAST

CLINICAL HISTORY:
Abd pain, unspecified, No IV, No PO Contrast.

TECHNIQUE:
As of images were acquired through the abdomen and pelvis without IV contrast.

Dose lowering technique(s) such as automated exposure control, iterative reconstruction, and mA and/or KV adjustment for patient size was utilized for this exam.

FINDINGS:
A tiny left pleural effusion is seen. Minimal subsegmental atelectatic changes are noted within the left lower lobe.

There is third spacing of fluids within the subcutaneous tissues, consistent with anasarca.

Presumed embolization coils are seen causing a large amount of spray artifact within the left upper quadrant. The stomach, small bowel, and colon show no evidence of ileus or obstruction. A large amount of fecal material is seen throughout the colon, especially within the rectal vault, consistent with significant constipation.

There is a large fluid density collection within the left upper quadrant, presumably representing an infarcted spleen. This measures 9.0 x 9.6 x 13.3 cm in size. The

* Patient appears to be status post left nephrectomy.

There is no evidence of free intraperitoneal fluid or air.

Calcified and noncalcified uterine fibroids are seen.

stolen
Kidney

Hayes and Hayes L.L.C.

ATTORNEYS AT LAW

200 OAKLAND AVENUE, SUITE B
ROCK HILL, SOUTH CAROLINA 29730
www.weshayeslaw.com

Robert W. Hayes, Jr.
rwhayes@weshayeslaw.com

J. Creighton Hayes
creighton.hayes@weshayeslaw.com

DISBURSEMENT SHEET
RICE

Date of Accident: April 11, 2106

FILED
APR 11 2017
RICE
3 20
MISTAKE
Mailing Address:
P.O. Box 904
Rock Hill, SC 29731-6904
Telephone: (803) 324-2800
Fax: (803) 324-5030

CASE SETTLED FOR \$ [REDACTED]

LESS

Attorney's fees (reduced from 1/3 to 1/4).....	\$ 16,250.00	← Mistake
Costs advanced for copies, fax, and long distance calls.....	36.36	what did you do besides cause future damages!!!
Costs advanced -OrthoCarolina (medical bill).....	10.00	
Midlands Ortho.....	-0-	
Chester Regional Medical Center.....	-0-	
Carolinas Healthcare.....	-0-	
C/MC Behavioral Health.....	229.90	
Stepping Stones.....	-0-	
OrthoCarolina.....	-0-	
Carolina Ortho. & Neurosurgical.....	-0-	
Medicaid.....	4,138.87	← Mistake
Attorney's lien (Andrew Kunz).....	7,487.62	← Mistake
Tange Murphy responsible for this Not Victim		
TOTAL FEES AND COSTS.....	\$ 28,152.75	

TOTAL NET PROCEEDS \$ [REDACTED]

APPROVED:

[REDACTED SIGNATURE]

Victim is at risk!!!

*IT IS MY UNDERSTANDING THAT SHOULD ANY OTHER MEDICAL PROVIDERS, INSURANCE COMPANIES, MEDICARE AND/OR MEDICAID, REQUEST TO BE REIMBURSED REGARDING OUR ACCIDENT ON 4/11/16, IT IS MY RESPONSIBILITY AND NOT THE RESPONSIBILITY OF HAYES AND HAYES, L.L.C.

Patient Needs Additional Therapy....

CT Abdomen & Pelvis w/o Contrast
* Final Report *

COLEMAN, [REDACTED]

FILED
APR 10 3 20
RADIOLOGY DEPARTMENT
ST. LOUIS, MO

A high density right renal cyst is seen, unchanged from a prior study from 10/29/2017.

IMPRESSION:

1. Significant constipation, with a large volume of fecal material within the rectosigmoid vault.
2. There is a large left upper quadrant fluid collection. Given the embolization coils, this likely represents the infarcted spleen. If the patient is status post splenectomy, this likely represents a large seroma. No air bubbles are seen within this collection.

Removed
Left Kidney

[REDACTED]

D: 10/30/2018 5:02 PM

[REDACTED]

Signature Line

**** Final ****

Verified: 10/30/2018 5:02 pm [REDACTED]

Signed (Electronic Signature): 10/30/2018 5:02 pm

Transcribed by [REDACTED]

CT Abdomen and Pelvis w/o Contrast
This document has an image

ALL DOCTORS ARE
NOT ON BOARD WITH
CORRUPTION

Printed by: [REDACTED]

③

Gods wrath will continue until
justice is prepaired!!! In the Name of Jesus

Let Study to show thyself approved
unto God, a workman that needeth not
to be ashamed, rightly dividing the word of truth.

You may want to study Ezekiel 7:1

The Lord Has Come...

Also Ezekiel 11:16-20 promised Return to Jerusalem

"Better to be an Open Sinner than a Hypocrite
Sinner"

(We accept Bites in the Lord has no limits)

The Appeals Court settlement is also a Wager
to the Victory Belongs to Jesus case!!! 😊

This is a case that is refusing to be sent to a
higher court WHY!!! George Murphy

(2)

There is no reason a 65,000 case has
this much to lose unless my allegations are
correct. The last motion I already named
these parties, so this motion is to address
the Court of Appeals for allowing Claire Allen
to further cause Mental Anguish in the
amount of Unlimited awards for this action.
The reason Mr. Rice the victim asked to
not attend the hearing is still unknown to
all parties but will be revealed in due time!!!
This award damages has merit because the
Clerk used The Court of Appeals letter head &
in envelope from the Court of appeals.
Since this case was remitted back to this jurisdiction
victim has been stopped by the police which
caused an overwhelming setback, and triggers!

[Sent from Yahoo Mail on Android](#)

①

2017-CP-12-00079

April 7, 2022

To whom it may concern, My name is Lanya Murphy. Ms. Murphy contacted the Court of Appeals showing additional proof of the made up case 2021-000751 as the appellant case number should be reheard because the attorney had a clause in the paperwork that prohibits the victim from seeking treatment for his ongoing disabilities. Mrs. V Claire allen, Defendants, Assquins Hayes and the Judges attached to this case allegedly invented some sort of conspiracy that prevents them from rehearing this case. Ms. Murphy is alleging something like a Bitcoin investment, (Stolen Organs) back Market Operation, Paying Civilians to destroy those who are willing to expose them WHO KNOWS!!!